

Journal Pre-proof

Breast reconstruction using the Profunda Artery Perforator (PAP) flap: technical refinements and evolution, outcomes and patient satisfaction based on 116 consecutive flaps

Matteo Atzeni MD , Rosa Salzillo MD ,
Richard M Haywood MBBS FRCS (Plast) ,
Paolo Persichetti MD PhD FEBOPRAS ,
Andrea Figus MD PhD FEBOPRAS

PII: S1748-6815(21)00635-5
DOI: <https://doi.org/10.1016/j.bjps.2021.11.085>
Reference: PRAS 7509



To appear in: *Journal of Plastic, Reconstructive & Aesthetic Surgery*

Received date: 24 March 2021
Accepted date: 14 November 2021

Please cite this article as: Matteo Atzeni MD , Rosa Salzillo MD , Richard M Haywood MBBS FRCS (Plast) , Paolo Persichetti MD PhD FEBOPRAS , Andrea Figus MD PhD FEBOPRAS , Breast reconstruction using the Profunda Artery Perforator (PAP) flap: technical refinements and evolution, outcomes and patient satisfaction based on 116 consecutive flaps, *Journal of Plastic, Reconstructive & Aesthetic Surgery* (2021), doi: <https://doi.org/10.1016/j.bjps.2021.11.085>

This is a PDF file of an article that has undergone enhancements after acceptance, such as the addition of a cover page and metadata, and formatting for readability, but it is not yet the definitive version of record. This version will undergo additional copyediting, typesetting and review before it is published in its final form, but we are providing this version to give early visibility of the article. Please note that, during the production process, errors may be discovered which could affect the content, and all legal disclaimers that apply to the journal pertain.

© 2021 Published by Elsevier Ltd on behalf of British Association of Plastic, Reconstructive and Aesthetic Surgeons.

**Breast reconstruction using the Profunda Artery Perforator (PAP) flap:
technical refinements and evolution, outcomes and patient satisfaction based on
116 consecutive flaps**

Matteo Atzeni¹, MD, Rosa Salzillo², MD, Richard M Haywood³, MBBS FRCS
(Plast), Paolo Persichetti², MD PhD FEBOPRAS, Andrea
Figus^{1,*}, andreafigus@hotmail.com, MD PhD FEBOPRAS

¹University of Cagliari, Faculty of Medicine and Surgery, Department of Surgical Sciences, Plastic Surgery and Microsurgery Unit, University Hospital Duilio Casula, Cagliari. Italy

²Campus Bio-Medico University of Rome, Department of Plastic, Reconstructive and Aesthetic Surgery, University Hospital Campus, Bio-Medico, Rome, Italy

³Norfolk and Norwich University Hospital NHS Foundation Trust, Department of Plastic and Reconstructive Surgery, Norwich, United Kingdom. University of East Anglia, Norwich Medical School

***Corresponding author:** Prof. Andrea Figus, MD, PhD, FEBOPRAS, Professor of Plastic Surgery, Faculty of Medicine and Surgery, University of Cagliari, Department of Surgical Sciences, Director of Plastic Surgery and Microsurgery Unit, University Hospital Duilio Casula, SS554, Monserrato, 09100, Cagliari, Sardinia, Italy

Abstract

Introduction: When a Deep Inferior Epigastric Artery flap is not suitable, the Profunda Artery Perforator (PAP) flap can be a good alternative for autologous breast reconstruction. Popularity of the PAP flap is expanding, but it is still only slowly being adopted worldwide. We report our experience with 116 consecutive PAP flaps showing refinements and evolution of the technique towards improvement in outcomes and patients' satisfaction.

Methods: We prospectively collected data from consecutive PAP flap breast reconstructions performed from 2016 to 2019. Patients' demographics, pre-, intra-, postoperative data and revision procedures were analyzed. The BREAST-Q and a specific questionnaire investigating outcomes at the donor site were completed preoperatively and 12 months postoperatively.

Results: One-hundred and sixteen PAP flaps were performed in 86 patients, 64 unilateral and 22 bilateral breast reconstructions. Mean body mass index was 24.72 kg/m² (range 18.9-29.2) and

mean flap weight was 251.30g (range 152g – 455g). Complications included donor site hematoma (1.7%), seroma (2.6%), fat necrosis (1.7%) and wound dehiscence (2.6%). No arterial/venous thrombosis nor flap losses were recorded. Patients reported high satisfaction in all BREAST-Q domains, with mean postoperative scores being higher than preoperative ones, suggesting a positive effect in quality of life and satisfaction. Scores were significant in the satisfaction with breast domain ($p= 0.0016$).

Conclusions: Breast reconstruction with PAP flap yields a high success, low complications and excellent cosmetic outcomes in the breast and donor sites. It improves patients' satisfaction and quality of life; hence it can be considered an excellent option for autologous breast reconstruction.

Introduction

The Deep Inferior Epigastric Artery Perforator (DIEP) flap is accepted worldwide as the first choice in autologous breast reconstruction due to its advantages in creating a natural breast mound with long-lasting aesthetic results, low complications and acceptable donor site morbidity. However, the abdomen is not always a suitable donor site due to previous abdominal surgeries, insufficient available tissue or patients' reluctance to have an abdominal scar. The wide range of patients' physical features and preferences, encouraged breast reconstructive surgeons to seek alternative flaps from different donor sites. Amongst these, the Profunda Artery Perforator (PAP) flap is considered a good choice for autologous breast reconstruction. It provides a relatively large amount of tissue that can be easily shaped to mimic a natural breast mound. It demonstrated a constant vascular anatomy with a long pedicle and adequate vessel diameter for comfortable micro-anastomoses associated with a low donor site morbidity and good cosmetic results¹. Since its description in 2012 for breast reconstruction by Allen et al.², the PAP flap is gaining popularity and its role in breast reconstruction is expanding but it is still only slowly being adopted worldwide. In order to define an effective role of the PAP flap within autologous breast reconstruction, we report

the evolution of our surgical technique over the years and analyze outcomes and patients' satisfaction with this autologous breast reconstructive procedure.

Patients and Methods

In order to assess the outcomes and patients' satisfaction with PAP flap breast reconstruction, we carried out a prospective service evaluation of all patients who underwent breast reconstruction with PAP flap between 1st January 2016 and 31th December 2019 in adherence to the STROBE guidelines. Demographic data and previous breast cancer treatments were recorded for each patient. This data set included age, body mass index (BMI), history of chemotherapy and/or radiation therapy. Reconstructive timing, type of mastectomy prior to reconstruction and operative variables such as average flap weight, operative time and days of hospitalization were also noted. Early and late complications relative to both donor and recipient sites were listed together with the number of revision procedures performed. All data were prospectively recorded within a PAP flap data sheet updated constantly by the authors. The BREAST-Q Reconstruction Module was completed by patients preoperatively and 12 months postoperatively. Patients' satisfaction and physical well-being of the thighs was investigated through a specific questionnaire³ administered preoperatively and 12 months postoperatively. The aforementioned questionnaire, unlike the BREAST-Q, is non-validated and has limitations^{4,5}. To date, there are no specific tools to evaluate the PAP flap donor site and a specific tailored questionnaire would give more accurate data compared to other validated but non-specific questionnaires investigating only functional impairment of the lower extremity⁶. In this series, none of the patients presented comorbidities of the lower limbs such as hip replacement, knee surgery or arthrosis, that could have interfered with the scoring.

Descriptive statistics was performed using Microsoft Excel (Microsoft Corp., Redmond, Wash.). A t-test was also performed with the same software in order to compare pre- and postoperative

BREAST-Q scores. The values were two-tailed and a p value < 0.05 was considered statistically significant.

Operative technique

All patients underwent preoperative computed tomographic angiography to evaluate the presence, location, calibre and route of the PAP flap perforators. Using the trochanter, the midline of the posterior thigh and the inferior gluteal crease as reference points, the largest, better placed perforators can be identified. Ideally, we choose the medial perforator closest to the inferior gluteal crease. Preoperative markings are made first with the patient standing and then lying supine in the frog leg position. The dimensions of the skin flap depend on the amount of skin needed in the reconstructed breast. As a general rule, less skin is required in immediate reconstructions (following nipple or skin sparing mastectomies) compared to delayed reconstructions where, at times, it can be difficult obtaining adequate skin coverage with a single PAP flap. The patients have been marked taking in account our experience with TUG flap⁷ breast reconstruction. As our technique and experience evolved, we started to raise the flap with a narrower skin island not including the chosen perforator and measuring up to 6 cm of width, due to the increased request of immediate breast reconstructions at our Institution. We placed the superior border of the skin flap 1 cm above or at the level of the inferior gluteal crease to reduce the risk for lower migration of the donor site scar. We realized the anterior skin was not useful due to unreliable perfusion and did not add significant bulk to the flap. Therefore, we moved the anterior apex of the skin flap medially to the level of the anterior labial commissure, avoiding a visible scar anteriorly (Figure 1). In the operative theatre, we moved from the frog leg position to the lithotomy position, which allows more comfortable dissection and less surgeon fatigue during the procedure as described by Hunter et al⁸. Following incision of the skin paddle, dissection of the flap was changed following a superomedial to inferolateral direction, allowing gravity to retract the flap out of the operative field leading to greater exposure of the perforator and pedicle dissection and a more comfortable view and access to

the operative field. Dissection is carried out undermining the thigh skin from the flap's adipose tissue and dissecting it above the gracilis muscle fascia⁷. Reassured by a constant and reliable flap perforator anatomy, we now discard the gracilis muscle perforators at the beginning of the dissection. Deep fascia is included in the flap to offer a more robust perfusion to the adipose tissue. Hence, the dominant perforator is safely not included within the territory of the skin paddle but it is included within the adipose tissue (Video). Following incision of the adductor magnus muscle fascia below the inferior border of the gracilis muscle, the sub-fascial dissection is carried out until identification of the dominant perforator; a second additional perforator may be selected. The dominant perforator is usually found exiting the adductor magnus muscle belly approximately within 3 cm posterior to the posterior border of the gracilis muscle and within 5 to 14 cm from the inferior gluteal fold. The perforator dissection is continued along its intra-muscular course. Pedicle dissection is continued until the vessels are of an adequate diameter to match the internal mammary vessels which are the authors preferred recipient vessels and have been used in all the cases in this series. The donor site is closed in layers over a drain, ensuring a robust suture of the superficial fascia, restoring its continuity. Key points of the evolution of our harvesting technique are summarized in Table 1.

Postoperative management

All patients were encouraged to mobilize from the first postoperative day, but were asked to avoid strenuous physical activity for at least four weeks. Patients could start a regular diet since the first postoperative day. After two days, the Foley catheter and intravenous fluids were discontinued. Postoperative pain was generally well controlled using intravenous paracetamol and avoiding opiates⁹. Clinical monitoring of the flap vitality was continued for 2 days postoperatively and drains were removed when < 50 cc in 24h. Compressive garments, i.e. cyclist pants, were encouraged to be dressed for 2 weeks. Patients were informed about the possibility of experiencing subtle

temporary distortion of the vaginal introitus or direction of the urinary stream for 4 to 8 weeks after surgery.

Results

Our prospective case series included a total of 116 PAP flaps performed in 86 consecutive patients for a total of 108 reconstructed breasts. Unilateral reconstruction was performed in 64 patients, of which 56 unilateral to one side and 8 bilateral to one side (stacked) flaps. Twenty-two patients received a bilateral reconstruction.

Mean patients' age was 47.56 ± 9.48 years and average BMI was 24.72 ± 2.20 kg/m². Twenty-one patients received chemotherapy and 19 patients received radiotherapy before surgery, whereas 23 patients received post-mastectomy radiotherapy (PMRT) following reconstruction. Nineteen patients received immediate axillary lymphadenectomy. Mean follow-up time was 27.12 ± 13.16 months (Table 2).

Eighty-three breasts were reconstructed simultaneously to the mastectomy: amongst these, 71 therapeutic and 12 prophylactic mastectomies were performed. The remaining 25 breasts were reconstructed in a secondary fashion i.e. implant-based reconstruction complicated by capsular contracture or dehiscence/infections with implant failure. Details about reconstructive timing and type of mastectomy performed are shown in Table 3.

Average operative time was 343.79 ± 101.89 minutes including mastectomy. Unilateral breast reconstructions mean operative time was 288.8 ± 42.05 minutes, while 483.72 ± 69.77 minutes were needed on average for bilateral reconstructions. Average flap weight was 251.30 ± 89.22 g (range 152g – 455g). Patients' mean hospitalization was 6.96 ± 2.41 days.

Return to theatre was required in two cases (1.7%) of donor site hematoma and three cases (2.6%) of donor site wound dehiscence. Furthermore, three patients (2.6%) developed a seroma at the donor site that was managed in the outpatient clinic with puncture aspiration. Fat necrosis was diagnosed in two cases. Postoperative course was otherwise uneventful with no arterial or venous

thrombosis nor flap losses recorded (Table 4). Two patients with bilateral reconstruction reported a slight change in the direction of the urine stream which resolved within 6 weeks.

Thirty-one patients (36%) underwent simultaneous contralateral symmetrization by means of breast reduction or mastopexy. One patient underwent a second stage contralateral symmetrization. Four patients (4.7%) required fat grafting to the flap to improve breast contour and volume, two of which (2.3%) underwent PMRT following immediate reconstruction. No patients suffered from lymphedema.

Pre- and postoperative BREAST-Q scores were high in every domain. Details regarding patients' satisfaction and quality of life are shown in Table 5. Mean postoperative scores were higher than preoperative ones as shown in Figure 2.

The t-test showed a significant difference ($p=0.0016$) between pre- and postoperative BREAST-Q scores for satisfaction with breast domain, whereas it was not significant for psychosocial well-being ($p=0.1203$), physical well-being ($p=0.8610$) and sexual well-being ($p=0.0535$) domains.

Regarding patients' satisfaction with donor site, the mean preoperative score was 3.6 ± 0.5 (90%) with a maximum possible score of 4, whereas the mean postoperative score was 10.9 ± 1.3 (91%) with a maximum possible score of 12 (Table 5). Concerning thighs' physical well-being, the mean pre- and postoperative scores were 74.0 ± 14.7 and 75.2 ± 15.8 respectively ($p=0.6148$), (Table 5). Mean difference between pre- and postoperative BREAST-Q scores (delta) was calculated for patients undergoing immediate and secondary reconstruction in order to investigate how patients' satisfaction varied pre- and postoperatively in the two groups (Table 5). Both groups showed an increased satisfaction and quality of life after PAP flap breast reconstruction. However, differences between the two groups were not statistically significant in any domain (Table 5).

Discussion

The PAP flap allows to harvest a relatively large amount of tissues that can be easily shaped conferring natural and long-lasting outcomes to a reconstructed breast of small to moderate size¹⁰.

This flap has a constant vascular anatomy¹¹ and good donor site cosmesis (Figure 3). Some studies¹²⁻¹⁴ have investigated safety and reliability of the PAP flap, showing numbers comparable to the DIEP flap, which can be considered the gold standard for autologous breast reconstruction. Therefore, PAP flap is a good alternative to DIEP flap in women with insufficient abdominal tissue, previous abdominal surgery, a failed TRAM/DIEP/SIEA flap, pear shaped body habitus or patients who simply prefer a non-abdominal donor site. Our approach has followed these indications for a long time, but in the last four years, moving our practice from the United Kingdom to Sardinia (Italy), it has started to change since we faced an increasing number of patients requesting PAP flap breast reconstruction. This may be due to local body habitus and country habits as having favourable weather conditions throughout the whole year, people are more prone to beach life, where they wear a bikini for many hours a day and pay more attention to body exposure. In fact, many of our patients asked for a PAP flap breast reconstruction mainly because the scar can be easily hidden in the gluteal fold being hardly noticeable even when they are entirely naked in front of a mirror. Although in clinical practice the PAP flap volume is adequate for small to moderate sized breasts, recently Haddock and Teotia¹⁵ reported a consistent cluster of PAP flap breast reconstructions with a wide flap weight range (from 190 to 800 g), showing low donor site complications and high patients' satisfaction after high volume reconstructions.

To our knowledge, Haddock and Teotia¹⁵ published the first study investigating patients' satisfaction after breast reconstruction with PAP flap. We reported similar results in the postoperative BREAST-Q evaluation, with higher scores in the sexual well-being (71.7 vs 64) and physical well-being domains (90.3 vs 84), comparable scores in the satisfaction with breast domain (77.8 vs 78) and lower scores in the psychosocial well-being domain (76.7 vs 83). However, they did not investigate patients' satisfaction and quality of life preoperatively. This is an important factor to evaluate the impact of the PAP flap breast reconstruction on patients' satisfaction¹⁶. Comparing pre- and postoperative BREAST-Q scores, we noticed a particular increase in the satisfaction with breast domain, where we recorded a mean score of 70.4 ± 20.8 preoperatively that

raised to 77.8 ± 17.7 postoperatively. Considering that 76.9% of our patients underwent an immediate reconstruction, these scores may suggest that, compared to the preoperative condition, following breast cancer diagnosis, the PAP flap breast reconstruction had a positive impact on patients' satisfaction and quality of life. Similar findings related to DIEP flap breast reconstruction were reported in the MROC study.¹⁷⁻¹⁹

Moreover, this increase in patients' satisfaction with breasts might be also supported by the fact that contralateral symmetrization was always performed simultaneously to the mastectomy when needed, therefore, patients may have experienced satisfied postoperative breast symmetry. Nonetheless, it is useful to contextualize our findings comparing them with breast cancer and reconstruction normative data published by Mundy et al.²⁰: our series showed higher results in every BREAST-Q domain except for physical well-being of the chest that reported slightly lower scores. Patients' satisfaction with the thigh and buttocks donor site was also very high, with mean scores very close to the maximum scores possible (Table 5). These data strongly support PAP flap in breast reconstruction.

Satisfaction and quality of life after breast reconstruction using PAP flap increases postoperatively in both immediate and secondary reconstructions (Table 5). Differences between the two groups, however, are not statistically significant in any domain and more studies are needed to better assess this finding.

Comparing complications with other series¹⁵, we reported similar incidence of thigh hematoma but less dehiscence and seromas. This may be in part explained by the reduction of the skin paddle size and the fact that the distal portion of the PAP flap is harvested as an adipose flap whose dimensions depend on the amount of tissue needed to restore the breast mound. This results in a tension-free suture with a subsequent potential reduction of dehiscence and seromas. Furthermore, we did not experience any flap losses or venous congestions compared to other series¹⁵. This can be related to a relatively limited series.

Allen et al.¹⁰ published their experience with 164 PAP flap breast reconstructions showing similar numbers of hematoma and wound dehiscence compared to our series, while reporting higher rates of seroma and fat necrosis. The authors stated that the vast majority of their patients underwent revision procedures, mainly consisting in fat grafting to improve the donor and recipient sites contour. Tielemans et al.²¹ recently reported their experience with the extended PAP flap for breast reconstruction, whose design is very similar to the already described trilobed PAP flap²². They state it allows to recruit more skin and subcutaneous tissues on a dominant distal perforator. This design implies an additional vertical scar difficult to hide. According to our experience, it is possible to harvest an extended PAP flap based on a distal perforator without the need of a vertical skin paddle. This perforator does not need to be included within the skin paddle, but can be safely embedded within the adipose tissue harvested undermining the medial thigh skin. Doing so, the width of the skin paddle is reduced allowing a tension-free suture without the need of a more visible vertical scar. In unilateral cases, this technique allowed us to avoid any surgery in the contralateral thigh. In fact, avoiding the vertical scar, we do not perform reduction in the circumference of the thigh and, until now, the perception of asymmetry between the thighs has never prompted the patients to request a contralateral surgery.

Further studies are needed to confirm patients' satisfaction and quality of life on a larger scale and to investigate the correlation between patient BMI, flap weight and complications in order to define the ideal patient selection.

Conclusions

The present series of PAP flap breast reconstructions demonstrated a low number of complications and revision surgeries with high satisfaction with breast and donor sites. To our knowledge, this is the first study comparing pre- and postoperative patients' satisfaction and quality of life after breast reconstruction with PAP flap. Our findings demonstrated that breast reconstruction with PAP flap

has positive impact on patients' satisfaction and quality of life. More studies are needed to further evaluate the role of PAP flap in autologous breast reconstruction.

Financial disclosure statement

the authors have no financial interest to declare in relation to the content of this article.

Funding

none.

Ethical Approval

N/A

Declaration of competing interest

none declared.

References

1. Haddock N, Nagarkar P, Teotia SS. Versatility of the Profunda Artery Perforator Flap: Creative Uses in Breast Reconstruction. *Plast Reconstr Surg.* 2017 Mar;139(3):606e-612e.
2. Allen RJ, Haddock NT, Ahn CY et al. Breast reconstruction with the profunda artery perforator flap. *Plast Reconstr Surg.* 2012 Jan;129(1):16e-23e.
3. Stocco C, Figus A, Razzano S. Upgrading the BREAST-Q questionnaire with donor site evaluation after PAP flap breast reconstruction. *J Plast Reconstr Aesthet Surg.* 2018 Jun;71(6):928-929.
4. Klassen AF, Kaur MN, Pusic AL. Adding scales to BREAST-Q must follow the same rigor as original scales. *J Plast Reconstr Aesthet Surg.* 2018 Aug;71(8):1216-1230.
5. Stocco C, Figus A, Razzano S. Response to letter commenting on upgrading the BREAST-Q questionnaire. *J Plast Reconstr Aesthet Surg.* 2018 Aug;71(8):1216-1230.

6. Binkley JM, Stratford PW, Lott SA, Riddle DL. The Lower Extremity Functional Scale (LEFS): scale development, measurement properties, and clinical application. North American Orthopaedic Rehabilitation Research Network. *Phys Ther.* 1999 Apr;79(4):371-83.
7. Fattah A, Figus A, Mathur B et al. The transverse myocutaneous gracilis flap: technical refinements. *J Plast Reconstr Aesthet Surg.* 2010 Feb;63(2):305-13.
8. Hunter JE, Lardi AM, Dower DR et al. Evolution from the TUG to PAP flap for breast reconstruction: Comparison and refinements of technique. *J Plast Reconstr Aesthet Surg.* 2015 Jul;68(7):960-5.
9. Bonde CT, Khorasani H, Elberg J et al. Perioperative Optimization of Autologous Breast Reconstruction. *Plast Reconstr Surg.* 2016 Feb;137(2):411-414.
10. Allen RJ Jr, Lee ZH, Mayo JL et al. The Profunda Artery Perforator Flap Experience for Breast Reconstruction. *Plast Reconstr Surg.* 2016 Nov;138(5):968-975.
11. Largo RD, Chu CK, Chang EI et al. Perforator Mapping of the Profunda Artery Perforator Flap: Anatomy and Clinical Experience. *Plast Reconstr Surg.* 2020 Nov;146(5):1135-1145.
12. Qian B, Xiong L, Li J et al. A Systematic Review and Meta-Analysis on Microsurgical Safety and Efficacy of Profunda Artery Perforator Flap in Breast Reconstruction. *J Oncol.* 2019 Jul 29;2019:9506720.

13. Gill PS, Hunt JP, Guerra AB et al. A 10-year retrospective review of 758 DIEP flaps for breast reconstruction. *Plast Reconstr Surg.* 2004 Apr 1;113(4):1153-60. doi: 10.1097/01.prs.0000110328.47206.50. PMID: 15083015.
14. Knox AD, Ho AL, Leung L et al. Comparison of Outcomes following Autologous Breast Reconstruction Using the DIEP and Pedicled TRAM Flaps: A 12-Year Clinical Retrospective Study and Literature Review. *Plast Reconstr Surg.* 2016 Jul;138(1):16-28.
15. Haddock NT, Teotia SS. Consecutive 265 Profunda Artery Perforator Flaps: Refinements, Satisfaction, and Functional Outcomes. *Plast Reconstr Surg Glob Open.* 2020 Apr 7;8(4):e2682.
16. Builes Ramírez S, Acea Nebril B, García Novoa A et al. Evaluation of the preoperative perception of quality of life and satisfaction of women with breast cancer using the BREAST-Q™ questionnaire. *Cir Esp.* 2020 Apr;98(4):212-218.
17. Weichman KE, Hamill JB, Kim HM et al. Understanding the recovery phase of breast reconstructions: Patient-reported outcomes correlated to the type and timing of reconstruction. *J Plast Reconstr Aesthet Surg.* 2015 Oct;68(10):1370-8.
18. Wilkins EG, Hamill JB, Kim HM et al. Complications in Postmastectomy Breast Reconstruction: One-year Outcomes of the Mastectomy Reconstruction Outcomes Consortium (MROC) Study. *Ann Surg.* 2018 Jan;267(1):164-170.
19. Cooke AL, Diaz-Abele J, Hayakawa T et al. Radiation Therapy Versus No Radiation Therapy to the Neo-breast Following Skin-Sparing Mastectomy and Immediate Autologous

Free Flap Reconstruction for Breast Cancer: Patient-Reported and Surgical Outcomes at 1 Year-A Mastectomy Reconstruction Outcomes Consortium (MROC) Substudy. *Int J Radiat Oncol Biol Phys.* 2017 Sep 1;99(1):165-172.

20. Mundy LR, Homa K, Klassen AF et al. Breast Cancer and Reconstruction: Normative Data for Interpreting the BREAST-Q. *Plast Reconstr Surg.* 2017 May;139(5):1046e-1055e.

21. Tielemans HJP, van Kuppenveld PIP, Winters H et al. Breast reconstruction with the extended profunda artery perforator flap. *J Plast Reconstr Aesthet Surg.* 2020 Sep 20:S1748-6815(20)30459-9.

22. Mohan AT, Zhu L, Sur YJ et al. Application of Posterior Thigh Three-Dimensional Profunda Artery Perforator Perforasomes in Refining Next-Generation Flap Designs: Transverse, Vertical, and S-Shaped Profunda Artery Perforator Flaps. *Plast Reconstr Surg.* 2017 Apr;139(4):834e-845e.

Figure and table legends

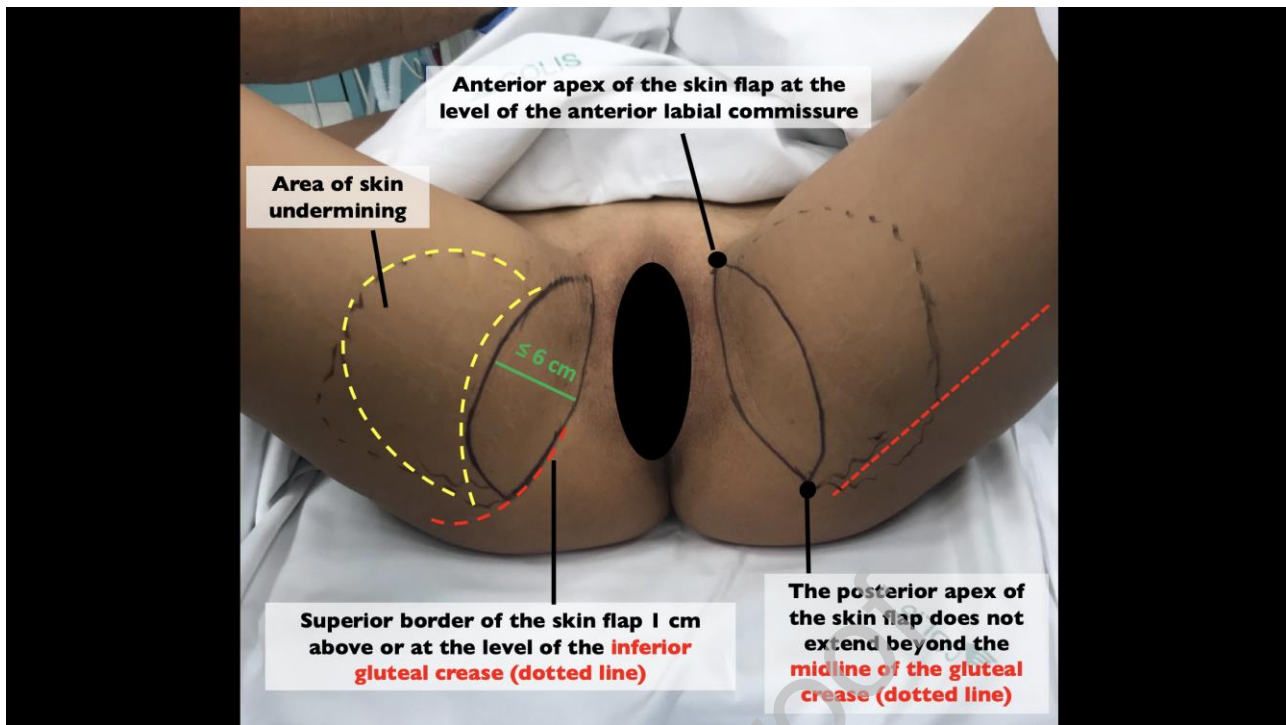


Figure 1 Preoperative marking of the PAP flap.

Comparison between pre- and postoperative BREAST-Q scores

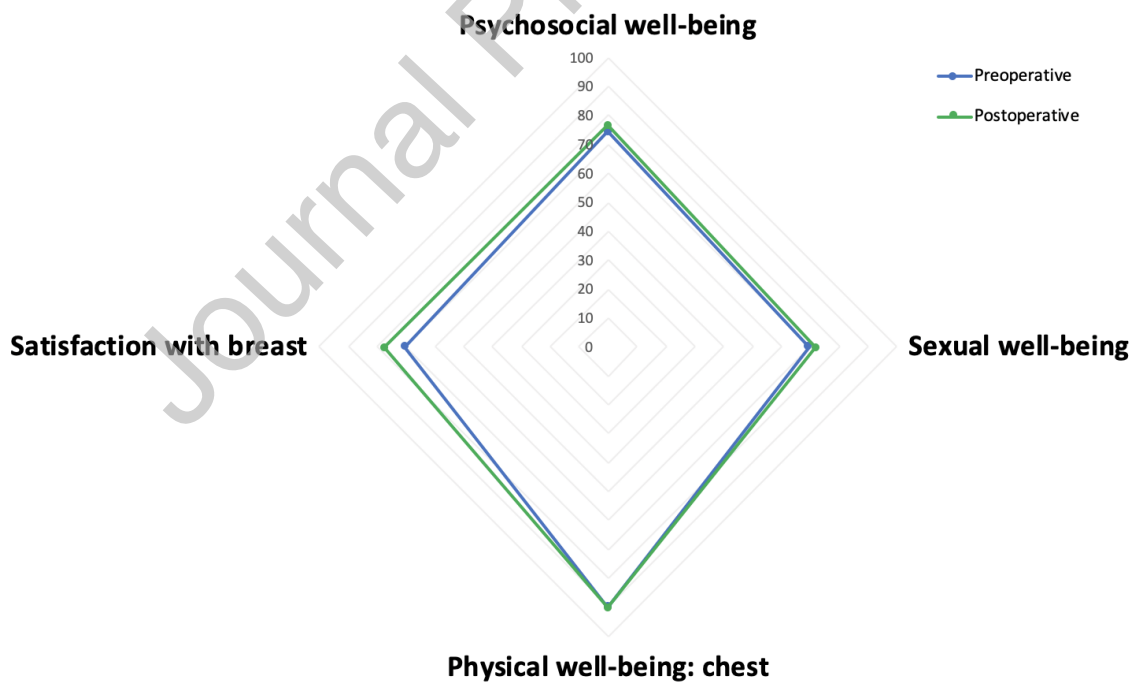


Figure 2 Radar chart showing mean pre- and postoperative BREAST-Q scores for the satisfaction with breast, physical well-being, psychosocial well-being and sexual well-being domains. Mean

postoperative scores are higher than the preoperative ones in every domain with a statistically significant difference in the satisfaction with breast domain ($p= 0.0016$).

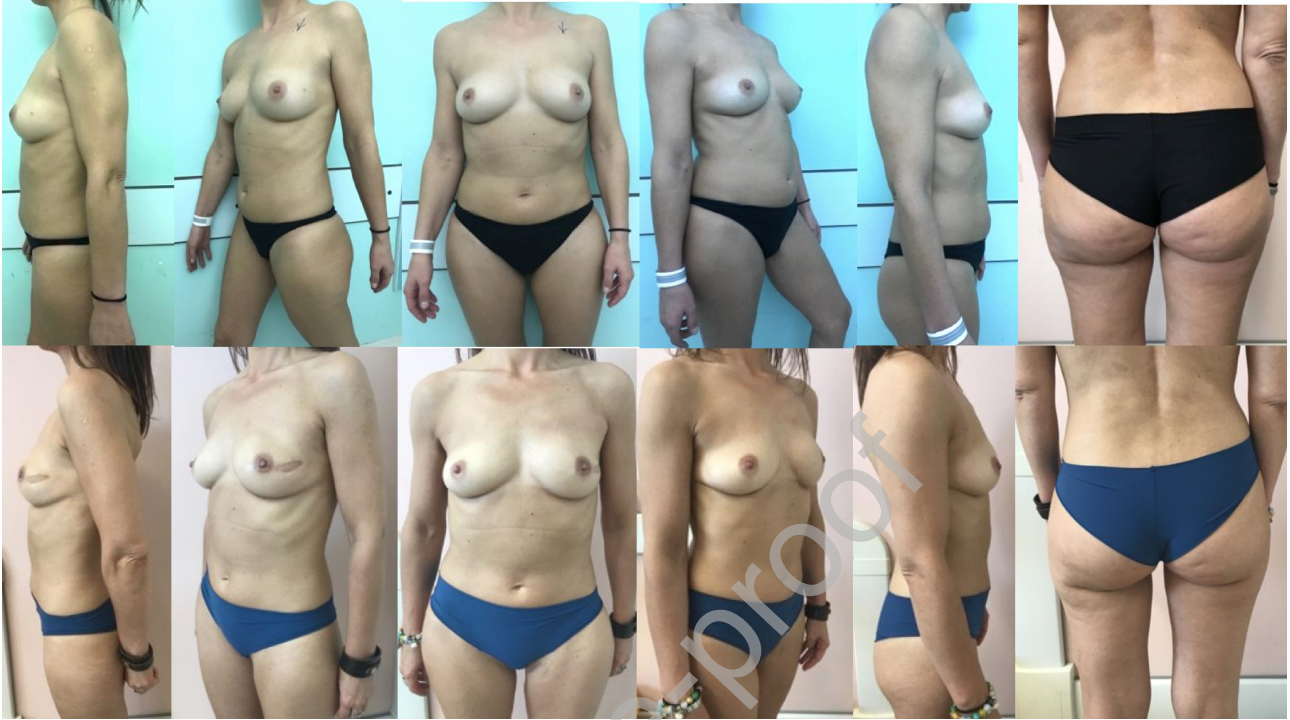

Figure 3 A 52 years old woman underwent left nipple sparing mastectomy followed by immediate breast reconstruction with a right PAP flap. Upper row: preoperative view. Lower row: 14 months postoperative view.

Table 1 Technical refinements and evolution: key points

Key points	Advantages
<ul style="list-style-type: none"> Lithotomy position 	<ul style="list-style-type: none"> More comfortable position, less surgeon's fatigue
<ul style="list-style-type: none"> Superomedial towards inferolateral dissection Skin island width ≤ 6 cm 	<ul style="list-style-type: none"> Quicker and comfortable identification and dissection of flap perforators Less tension at donor site closure
<ul style="list-style-type: none"> Superior margin of the skin paddle 1 cm above or at the level of the inferior gluteal crease 	<ul style="list-style-type: none"> Scar hidden in the gluteal crease, reduced lower migration of the scar

<ul style="list-style-type: none"> • Anterior apex of the skin paddle at the level of the anterior labial commissure 	<ul style="list-style-type: none"> • No visible scar anteriorly
<ul style="list-style-type: none"> • Posterior apex of the skin paddle not beyond the midline of the gluteal crease 	<ul style="list-style-type: none"> • Less visible scar posteriorly, Sparing of posterior cutaneous femoral nerve
<ul style="list-style-type: none"> • Perforator not included in the skin paddle 	<ul style="list-style-type: none"> • No need for extended flap vertical scar

Table 2 Patients' demographic data.

	Value (%)
N. patients	86
Total n. flaps	116
Mean age, y \pm SD (range)	47.56 \pm 9.48 (26-68)
BMI, kg/m ² \pm SD (range)	24.72 \pm 2.20 (18.9-29.2)
Neoadjuvant chemotherapy	21/86 (24.4%)
Neoadjuvant radiotherapy	19/86 (22.1%)
Adjuvant radiotherapy	23/86 (26.7%)
Axillary lymphadenectomy	19/86 (22.1%)
Follow-up, months \pm SD (range)	27.2 \pm 13.16 (15-45)

Table 3 Reconstructive timing.

		Reconstructed breasts (%) n=108
Immediate reconstruction		83 (76.9%)
Nipple Sparing Mastectomy (NSM)		69 (83.1%)
Skin Sparing Mastectomy (SSM)		11 (13.3%)
Modified Radical Mastectomy (MRM)		3 (3.6%)
Delayed reconstruction		0%

Secondary reconstruction	25 (23.1%)
Modified Radical Mastectomy (MRM)	19 (76%)
Nipple Sparing Mastectomy (NSM)	4 (16%)
Skin Sparing Mastectomy (SSM)	2 (8%)

Table 4 Operative variables and complications.

	Value (%) n= 116
Average operative time (min \pm standard deviation)	343.79 \pm 101.89
Unilateral reconstructions (min \pm standard deviation)	288.8 \pm 42.05
Bilateral reconstructions (min \pm standard deviation)	483.72 \pm 69.77
Average flap weight (g \pm standard deviation)	251.30 \pm 89.22
Average hospitalization (days \pm standard deviation)	6.96 \pm 2.41
Complications needing reintervention	5 (4.3%)
Thigh hematoma	2 (1.7%)
Thigh wound dehiscence	3 (2.6%)
Arterial/venous thrombosis	0 (0%)
Flap loss	0 (0%)
Fat necrosis	2 (1.7%)
Seroma (managed in outpatient clinic)	3 (2.6%)

Table 5 Pre- and postoperative BREAST-Q scores and satisfaction with donor site scores.

	Preoperative (mean \pm standard deviation)	Postoperative (mean \pm standard deviation)	t-test
N. of patients	78	78	
Psychosocial well-being	74.5 \pm 15.9	76.7 \pm 15.7	p=0.1203
Sexual well-being	69.4 \pm 18.5	71.7 \pm 19.2	p=0.0535
Physical well-being: chest	89.8 \pm 27.1	90.3 \pm 13.5	p=0.8610

Satisfaction with breast	70.4 ± 20.8	77.8 ± 17.7	p=0.0016
Satisfaction with information	N/A	91.3 ± 14.0	
Satisfaction with surgeon	N/A	90.3 ± 13.3	
Satisfaction with medical team	N/A	94.1 ± 10.8	
Satisfaction with office staff	N/A	93.8 ± 10.5	
Satisfaction with donor site	3.6/4 ± 0.5 (90%)	10.9/12 ± 1.3 (91%)	
Physical well-being: thighs	74.0 ± 14.7	75.2 ± 15.8	p=0.6148
	Immediate reconstructions' BREAST-Q score delta (mean ± SD)	Secondary reconstructions' BREAST-Q score delta (mean ± SD)	t-test with Welch's correction
Psychosocial well-being	1.4 ± 12.3	5.7 ± 7.2	0.0631
Sexual well-being	1.3 ± 8.7	1.9 ± 8.2	0.7927
Physical well-being: chest	1.3 ± 28.2	0.4 ± 10.1	0.8271
Satisfaction with breast	8 ± 19.9	5.6 ± 18.4	0.6266