

Forno Gonzalo (Orcid ID: 0000-0003-2739-6028)

Going round in circles – the Papez Circuit in Alzheimer’s Disease.

The Papez Circuit in Alzheimer’s Disease

Gonzalo Forno^{1,2,3}, Albert Lladó^{1,4} and Michael Hornberger⁵

¹ Alzheimer’s Disease and Other Cognitive Disorders Unit, Neurology Service, Hospital Clínic of Barcelona, Institut d’Investigacions Biomèdiques August Pi i Sunyer (IDIBAPS), Universitat de Barcelona, Barcelona, Spain.

² School of Psychology, Universidad de los Andes, Santiago, Chile.

³ Neuropsychology and Clinical Neuroscience Laboratory (LANNEC), Physiopathology Department, ICBM, Neurosciences Department, Faculty of Medicine, University of Chile, Santiago, Chile.

⁴ Centro de Investigación Biomédica en Red de Enfermedades Neurodegenerativas. CIBERNED, Spain.

⁵ Norwich Medical School, University of East Anglia, Norwich, UK.

Corresponding author:

Prof. Michael Hornberger, Norwich Medical School, University of East Anglia, Norwich, United Kingdom, m.hornberger@uea.ac.uk.

Norwich Medical School, Bob Champion Research and Education Building, University of East Anglia, James Watson Road, Norwich, NR4 7TJ, UK

Tel: +441603597139, Fax: +441603593752

Keywords:

hippocampus, anterior thalamic nucleus, posterior cingulate cortex, episodic memory, spatial navigation

This article has been accepted for publication and undergone full peer review but has not been through the copyediting, typesetting, pagination and proofreading process which may lead to differences between this version and the Version of Record. Please cite this article as doi: 10.1002/ejn.15494

Abbreviations:

AD, Alzheimer's disease; *APOE4*: apolipoprotein E4; *APOE*, apolipoprotein; MCI, mild cognitive impairment; aMCI, amnesic mild cognitive impairment; ADAD, autosomal dominant Alzheimer's disease; *PSEN1*, presenilin 1; *PSEN2*, presenilin 2; APP, amyloid precursor protein; MB, mammillary bodies; MTT, mammillothalamic tract; ATN, anterior thalamic nuclei; ACC, anterior cingulate cortex; PCC, posterior cingulate cortex; RSC, retrosplenial cortex; PHC, parahippocampal cortex; aPHC, anterior parahippocampal cortex; PMC, presymptomatic mutation carriers; SMC, symptomatic mutation carriers; EC, entorhinal cortex; DG, dentate gyrus; lvPPA, logopenic variant primary progressive aphasia; PCA, posterior cortical atrophy; CBS-AD, corticobasal syndrome; DTI, diffusion tensor imaging; DMN, default mode network; fMRI, functional magnetic resonance imaging.

Acknowledgement:

Dr. Albert Lladó received funding from Departament de Salut de la Generalitat de Catalunya (PERIS 2016-2020 SLT008/18/00061).

On behalf of all authors, the corresponding author state that there is no conflict of interest.

Abstract.

The hippocampus is regarded as the pivotal structure for episodic memory symptoms associated with Alzheimer's disease (AD) pathophysiology. However, what is often overlooked is that the hippocampus is 'only' one part of a network of memory critical regions, the Papez circuit. Other Papez circuit regions are often regarded as less relevant for AD as they are thought to sit 'downstream' of the hippocampus. However, this notion is oversimplistic and increasing evidence suggest that other Papez regions might be affected before or concurrently with the hippocampus. In addition, AD research has mostly focused on episodic memory deficits, whereas spatial navigation processes are also subserved by the Papez circuit with increasing evidence supporting its valuable potential as a diagnostic measure of incipient AD pathophysiology.

In the current review we take a step forward analysing recent evidence on the structural and functional integrity of the Papez circuit across AD disease stages. Specifically, we will review the integrity of specific Papez regions from at-genetic-risk (*APOE4 carriers*), to mild cognitive impairment (MCI), to dementia stage of sporadic AD, as well as autosomal dominant AD (ADAD). We related those changes to episodic memory and spatial navigation/orientation deficits in AD. Finally, we provide an overview of how the Papez circuit is affected in AD diseases and their specific symptomology contributions. This overview strengthened the need for moving away from a hippocampal-centric view to a network approach on how the whole Papez circuit is affected in AD and contributes to its symptomology, informing future research and clinical approaches.

Introduction

Alzheimer's disease (AD) is the most prevalent form of dementia contributing to 60-70% of all cases (WHO, 2017). It is a slowly progressive disease with insidious onset and, most commonly, impaired episodic memory (Schroeter *et al.*, 2009). Its most common presentation consists on sporadic AD, whereas a minority of AD cases are inheritance with an autosomal dominant pattern (ADAD) caused by mutation in different causal genes (*presenilin 1*, *presenilin 2* or *amyloid precursor protein*), with nearly 100% penetrance at 65 years old (Fortea *et al.*, 2010). AD has also known genetic risk factors, with *APOE4* being the major susceptibility gene (Li *et al.*, 2014), with three to four times more likely to develop AD in carriers with at least one copy (Brown *et al.*, 2011).

For decades, the hippocampus has been the centre of memory research as it is so strongly associated with Alzheimer's neuropathology. Notwithstanding, increasing evidence have shown that episodic memory does not rely solely in the hippocampus as several cortico-subcortical structures plays a critical role in mnemonic function (Moscovitch *et al.*, 2006; Hornberger *et al.*, 2012; Jankowski *et al.*, 2013; Acosta-Cabronero & Nestor, 2014; Aggleton, 2014; Aggleton *et al.*, 2016). In particular the larger Papez circuit, which involve the hippocampus, fornix, mammillary bodies (MB), mammillothalamic tract (MTT), anterior thalamic nuclei (ATN), cingulate cortex and the parahippocampal cortex (PHC) (Figure 1), contributes to the episodic memory and spatial navigation symptomology in AD. Furthermore, AD view as a hippocampal-amnesic disorder, could be misleading as memory impairment is not always sensitive enough for differentiating AD from other dementias (Hornberger *et al.*, 2012) and different presentations of AD reflects pathologies that extend beyond the hippocampus (Aggleton *et al.*, 2016; Falgas *et al.*, 2019).

Previous evidence (Aggleton *et al.*, 2016) has shown that structures of the Papez circuit, specifically the limbic thalamus and their reciprocal connections with the retrosplenial cortex, are vulnerable to AD pathology and might contribute to early symptomatology in AD and its prodromal phases. Further, spatial navigation and orientation have been described as a novel feature of cognitive evaluation for incipient AD offering a sensitive and specific marker of the disease (Coughlan *et al.*, 2018). Despite these important advances, no previous work has analysed the Papez circuit structure by structure and how its structural/functional disposition may be affected across different stages of sporadic AD and ADAD. Moreover, few works have related the specifics Papez circuit structures with the main symptomatology of AD.

Based on this, the current literature review takes a step back to examine the evidence of how Papez circuit regions are affected in genetically at-risk subjects due to *APOE4*, mild cognitive impairment (MCI), sporadic AD and genetic ADAD (presymptomatic mutation carriers -PMC- and symptomatic mutation carriers -SMC). We will review each region of the circuit and how it is structurally and functionally affected throughout the different stages of the disease. We will further analyse how these changes are associated with impaired episodic memory and spatial navigation deficits.

Anatomical and Functional Findings

Hippocampus

Located adjacent the PHC (Small *et al.*, 2011), the hippocampus ranges 4 to 4.5 cm along the medial temporal pole (Thomas *et al.*, 2008). Along its longitudinal axis, the hippocampus cellular cytoarchitecture can be subdivided into CA1 — 4 subfields, the dentate gyrus (DG), the presubiculum, parasubiculum and subiculum (Thomas *et al.*, 2008; Small *et al.*, 2011; Zeidman & Maguire, 2016; Lindberg *et al.*, 2017). From a functional point of view, the hippocampus trails the following pathway: the entorhinal cortex (EC) projects, through the perforant pathway, to the dentate gyrus (DG) which connects CA3 to CA1 subfield and the subiculum (Small *et al.*, 2011; Zeidman & Maguire, 2016). Finally, the subiculum and CA1 projects back to the EC (Zeidman & Maguire, 2016).

More recent evidence has shown that the hippocampus might not be a uniform structure. Emerging findings show that there is an anatomical differentiation along the longitudinal hippocampal axis, implying a functional differentiation along its anterior and posterior axis and associated cortical projection areas (Dalton *et al.*, 2019). Not only does this functional specialisation impact on the theoretical aspects but also as to whether it can explain the vulnerability of the hippocampus across proteinopathies, such as AD (Llado *et al.*, 2018).

The hippocampus is a well-known key structure affected by AD, by being one of the earliest regions to be affected by the pathophysiology (Braak & Braak, 1991), and causing the typical episodic memory deficits (McKhann *et al.*, 2011). Nowadays, hippocampal amnesic syndrome has been characterized as the most common syndromic presentation of AD (McKhann *et al.*, 2011) and essential for typical AD diagnosis (Sarazin *et al.*, 2007; Aggleton *et al.*, 2016). Neuropathological studies have described neurofibrillary tangles at first, in the transentorhinal cortex and then progress, across the limbic system, throughout the entire cortex in the end-stages of AD (Braak & Braak, 1991). Accompanied by significant microstructural

degeneration, changes on the hippocampal body white matter are also early noted (Cherubini *et al.*, 2010; Hong *et al.*, 2013), resulting in increasing cognitive impairment in severer stages of the disease (Desgranges *et al.*, 2002; den Heijer *et al.*, 2012). Amyloid accumulation, on the other hand, shows more variability, especially in the early stages of the disease (Braak & Braak, 1991). β -amyloidosis is a successive process beginning with neocortical A β -deposition expanding step by step into further regions of the brain (Thal *et al.*, 2002). Braak and Braak A-B-C scheme described few A β deposits located in the subiculum and CA1 in Stage B (Braak & Braak, 1991). While Thal scheme of 5 progressive phases of cerebral amyloidosis, described A β deposits in the entorhinal region, CA1 and the insular cortex since phase 2 (Thal *et al.*, 2002).

In the early stages, typical AD is associated with atrophy of CA1 and subiculum (Carlesimo *et al.*, 2015), whereas atypical presentations of AD, such as logopenic variant primary progressive aphasia (lvPPA), posterior cortical atrophy (PCA), corticobasal syndrome (CBS-AD) and behavioural/dysexecutive AD often show highly variable hippocampal atrophy (Whitwell *et al.*, 2010; Ossenkoppele *et al.*, 2015a; Ossenkoppele *et al.*, 2015b; Phillips *et al.*, 2018).

For ADAD, hippocampal atrophy, white matter pathology, abnormal functional connectivity and cortical thickness have been widely reported in SMC and PMC close to the age of symptom onset (Ridha *et al.*, 2006; Quiroz *et al.*, 2010; Apostolova *et al.*, 2011; Bateman *et al.*, 2012; Ryan *et al.*, 2013; Sala-Llonch *et al.*, 2015; Thordardottir *et al.*, 2015; Zheng *et al.*, 2018), resembling the so-called “AD signature” described in sporadic AD (Dickerson *et al.*, 2009). However, hippocampal changes in PMC might not follow a linear trajectory as more often a rapid, nonlinear change in hippocampal volume is only noted shortly before symptom onset (Fortea *et al.*, 2010; Apostolova *et al.*, 2011; Ryan *et al.*, 2013; Sala-Llonch *et al.*, 2015).

In healthy *APOE4* carriers evidence showing structural hippocampal changes are not consistent. While some studies reported decreased hippocampal volume in young and old cognitively intact carriers (Wishart *et al.*, 2006; Crivello *et al.*, 2010; O'Dwyer *et al.*, 2012), other studies show no hippocampal volume decrease (Honea *et al.*, 2009; Haller *et al.*, 2017). It has been even suggested that hippocampal structural changes may not be a good imaging marker to understand the effect of *APOE4* on the risk of dementia (Crivello *et al.*, 2010). Functional changes, on the other hand, seem to be more robust. Studies have consistently

reported hippocampal altered functional connectivity in healthy young and older *APOE4* carriers (Lind *et al.*, 2006; Filippini *et al.*, 2009; Dennis *et al.*, 2010; Patel *et al.*, 2013).

On a cognitive level, episodic memory impairment remains as the most common clinical feature in AD, associated with hippocampal changes. Vulnerability within a posterior network including the posterior cingulate, precuneus and hippocampus (La Joie *et al.*, 2014), supports the hypothesis that AD-related episodic memory impairments rely on a network including but going beyond the hippocampus, rather than focal hippocampal changes solely (Nestor *et al.*, 2006; La Joie *et al.*, 2014). More recently, differentiation along the hippocampal anterior-posterior longitudinal axis has shown more pronounced posterior hippocampal atrophy associated with visual memory decline in AD (Llado *et al.*, 2018).

Interestingly, while episodic memory impairment is also the most common clinical presentation on ADAD (Ridha *et al.*, 2006), the relationship of *APOE4* and episodic memory remains somewhat controversial in healthy carriers. Alterations in functional connectivity in episodic memory-related regions and impaired memory associated with *APOE4* in AD has been consistently described (El Haj *et al.*, 2016; Rajah *et al.*, 2017; Rabipour *et al.*, 2020). However, there is also evidence that shows similar performance on clinical memory tests between *APOE4* and non-carriers healthy elderly controls (Haller *et al.*, 2017). When cognitively healthy, *APOE4* is not always associated with an increased risk of cognitive deterioration, suggesting that *APOE4* effects on terms of structural and/or clinical progression becomes evident only in MCI and AD (Haller *et al.*, 2017).

Despite the clinical focus on episodic memory, animal models have shown that the hippocampus is critical for another cognitive function - spatial navigation. The discovery of place cells in CA1 and grid cells in the EC, presubiculum and parasubiculum (O'Keefe, 1976; Hafting *et al.*, 2005; O'Mara *et al.*, 2009; Zeidman & Maguire, 2016) has helped us understand how location of the animal in space (O'Keefe & Dostrovsky, 1971; Suthana *et al.*, 2009) and spatial representation are modulated in the brain (Hafting *et al.*, 2005; Zeidman & Maguire, 2016). For instance, CA1 and CA3 regions are involved in allocentric navigation strategies. This is, navigation using world-centred strategies forming a cognitive map of the environment (Coughlan *et al.*, 2018).

However, spatial navigation and orientation are only recently emerging as potential cognitive marker in AD (Ritchie *et al.*, 2018) and as a sensitive measure to differentiate between AD and other dementias (Tu *et al.*, 2015). Contrary to episodic memory, spatial

navigation is an uncommon complaint in healthy older adults and non-AD dementia (Cerman *et al.*, 2018; Coughlan *et al.*, 2018). Probably because the EC integrity is critical for successful navigation and at the same time is the cortical origin of AD pathophysiology (McNaughton *et al.*, 2006; Coughlan *et al.*, 2018). Not surprisingly, an increasing amount of studies show spatial navigation/orientation deficits in AD, due to hippocampal changes with some studies indicating that these changes are even present in MCI patients and cognitively healthy *APOE4* carriers (Coughlan *et al.*, 2018; Coughlan *et al.*, 2020). Indeed, allocentric spatial processing deficit has been proposed as a better predictor of risk to future dementia than episodic memory impairment in a middle-age *APOE4* cohort (Ritchie *et al.*, 2018). It remains therefore to be explored whether spatial navigation might be a more sensitive and specific cognitive marker for hippocampal pathophysiology in AD (Tu *et al.*, 2015; Tu *et al.*, 2017).

Fornix

Acting as the major output fibre of the hippocampus, the fornix plays an important role connecting the medial temporal lobe to associated regions. Located on the medial aspects of the cerebral hemisphere beneath the corpus callosum and above the thalamus, fornix projections end in the MB and the ATN (Copenhaver *et al.*, 2006; Aggleton *et al.*, 2010; Thomas *et al.*, 2011; Bubb *et al.*, 2017). Fornix fibres passing rostral to the anterior commissure also end in the septal area, basal forebrain (Thomas *et al.*, 2011) and prefrontal cortex (Copenhaver *et al.*, 2006). On a functional level, the fornix plays an important role in the Papez circuit which is critical for memory consolidation and learning new episodic information (Aggleton *et al.*, 2010; Thomas *et al.*, 2011; Bubb *et al.*, 2017). It is therefore not surprising that AD studies in particular have investigated this region, due to pervasive episodic memory changes in AD.

On a structural level, neuropathological evidence has shown widespread atrophy in limbic structures, including the fornix in AD (Callen *et al.*, 2001). The neuropathological findings have been extended to MCI by diffusion tensor imaging (DTI), a sensitive white matter technique. DTI results have consistently shown fractional anisotropy fornix changes in MCI (Mielke *et al.*, 2009; Kantarci, 2014; Wang *et al.*, 2020). Studies have even suggested that decreased fractional anisotropy in the fornix could be an early diagnostic and prognostic biomarker in sporadic AD (Ringman *et al.*, 2007; Mielke *et al.*, 2009; Mielke *et al.*, 2012). Furthermore, damage in white matter integrity, including the fornix, has been proposed as

partially responsible for reduced resting-state functional connectivity in MCI and AD (Wang *et al.*, 2020).

Altered white matter integrity in the fornix has also been found on ADAD (Ringman *et al.*, 2007; Cash *et al.*, 2013; Kantarci, 2014; Sanchez-Valle *et al.*, 2016). Decreased fractional anisotropy (Ringman *et al.*, 2007; Kantarci, 2014), and increased radial diffusivity (Ryan *et al.*, 2013) in the fornix can be already seen in PMC (*PSEN1*), although more significant reduction have been reported in SMC (Cash *et al.*, 2013). Similarly, *APOE4* carriers have shown widespread disruption of white matter tracts, including the fornix, even when no cognitive impairment is reported (Zhang *et al.*, 2015).

There is a clear consensus in the role the fornix plays in memory and learning new information (Rudebeck *et al.*, 2009; Aggleton *et al.*, 2010; Metzler-Baddeley *et al.*, 2011; Kantarci, 2014), as reflected by their connections with other key limbic structures (Copenhaver *et al.*, 2006). Furthermore, fornix structural and functional changes consistently correlate with cognitive impairment across different studies (Wang *et al.*, 2020), with fornix white matter integrity significantly associated with memory performance in MCI and AD.

In healthy adults, recent evidence has also demonstrated the functional relevance of the fornix in human spatial navigation using virtual reality (Dahmani *et al.*, 2019; Hodgetts *et al.*, 2020). Crucially, this supports the idea that spatial navigation does not solely depends on individual regions but also the white matter linking these brain areas (Hodgetts *et al.*, 2020). Although this evidence is of increasing interest, to date we are not aware of any study analysing how spatial navigation is affected by fornix vulnerability to AD pathology.

Mammillary Bodies

Situated ventral to the hypothalamus, the MB comprise two main nucleus: the lateral and medial with the lateral portion only accounting for 6% of the entire structure (Vann, 2010). Animal models have shown that MB are connected mainly by fibres originated in the subiculum, which join the fornix to end in the medial mammillary nucleus (Bubb *et al.*, 2017). Other inputs ending in the medial mammillary nucleus emerge from the medial EC, while the lateral mammillary nucleus receive parallel projections from the presubiculum, parasubiculum and postsubiculum (Vann & Aggleton, 2004). Also, MB receive inputs from the tegmental nuclei of Gudden, via the mammillary peduncle. While projections from the hippocampus are solely efferents (Bubb *et al.*, 2017), both medial and lateral mammillary nucleus have

reciprocal connections with the ventral tegmental nucleus of Gudden (Vann, 2010). MB also connect the ATN via the MTT (Aggleton & Sahgal, 1993).

While lesion studies have consistently shown amnesic symptoms after mammillary damage (Dusoir *et al.*, 1990; Tanaka *et al.*, 1997; Hildebrandt *et al.*, 2001), evidence showing mammillary volume reduction in AD is somehow inconsistent (Callen *et al.*, 2001; Copenhaver *et al.*, 2006; Hornberger *et al.*, 2012). For instance, MB volumetric loss in mild to moderate AD, have been described when compared with healthy controls (Callen *et al.*, 2001), MCI and older people with a subjective cognitive decline (Copenhaver *et al.*, 2006). Increased iron level in the right mammillary body with no apparent volumetric differences has been reported when comparing MCI and healthy controls (Jin *et al.*, 2020). Substantial decrease in neuronal population and abbreviation in dendritic arbores have also been reported in early cases of AD using electron microscopy and silver impregnation techniques (Baloyannis *et al.*, 2016). Furthermore, comparison of metabolic activity between MCI and AD, revealed hypometabolic activity in a limbic network including the MB (Nestor *et al.*, 2003). However, other study did not found significant differences in MB between AD and healthy controls using *in vivo* and post-mortem volumetric methods (Hornberger *et al.*, 2012). The conflicting results might be explained due to a variable loss of hippocampal afferents for MB, which might affect its own AD neuronal loss (Hornberger *et al.*, 2012). However, the sparsity of the data suggests that this requires more extensive, future investigation.

On a cognitive and functional level, MB has been commonly seen as hippocampal-dependent, and their role interpreted as a hippocampal relay, sending the information to the ATN and thus, heavily associated with hippocampal integrity. Nonetheless, recent findings suggest that MB have a role in memory independent to the hippocampus. It seems that the ventral tegmental nucleus of Gudden could provide critical input needed to support mnemonic processes (Vann, 2010; Vann & Nelson, 2015). Animal and human models have shown that MB are involved in, at least, two related system (Vann & Aggleton, 2004; Vann, 2010). The first one, implicated in episodic memory associated with medial mammillary nucleus, and the second one, as a critical structure for normal spatial navigation due to 'head direction' neurons located in the lateral mammillary nucleus. Both systems are tightly related and damage to either one of them, produce similar consequences (Vann & Aggleton, 2004; Vann, 2010; Jankowski *et al.*, 2013).

Evidence in animal models of AD consistently show that MB volume reduction is associated with episodic and spatial memory deficit (Grossi *et al.*, 1989; Baloyannis *et al.*, 2016). Dysfunction in an integrated network, including the MB, could be partially responsible for episodic memory deficits in AD (Nestor *et al.*, 2006). Overall, memory performance and MB shrinkage are consistently found across studies, strengthening the role that MB play in episodic and spatial memory (Grossi *et al.*, 1989; Hornberger *et al.*, 2012; Tan *et al.*, 2014; Bueno *et al.*, 2020), at least in animals, whereas the human evidence is still largely missing.

Mammillothalamic Tract

The MTT have been characterized as the only white matter tract that exclusively connects two Papez circuit regions (Bubb *et al.*, 2017) – the MB and the thalamus. Within the tract the medial mammillary nucleus projects ipsilaterally to the anterior medial and anterior ventral thalamic nucleus, while the lateral mammillary nucleus has a bilateral projection to the anterior dorsal thalamic nucleus (Aggleton & Sahgal, 1993). As stated before, MB are the only structure that contributes to the MTT allowing a direct understanding of their contribution to cognition and normal functioning. Nonetheless, evidence targeting the MTT integrity in AD are non-existent, to our knowledge.

On the contrary, studies using lesions and animal models in MTT and cognition are more common (Van der Werf *et al.*, 2000; Yoneoka *et al.*, 2004; Vann *et al.*, 2011; Jankowski *et al.*, 2013; Danet *et al.*, 2015; Vann & Nelson, 2015). Lesions studies has mainly focussed on thalamic infarct, where lesions in the MTT produce severe cases of amnesia (Carlesimo *et al.*, 2011). Even more severely affected than damage to the mediodorsal thalamic nucleus only (Van der Werf *et al.*, 2000; Danet *et al.*, 2015). Moreover, memory impairment by structural damage due to bilateral MTT infarction can be so severe, that it could mirror Korsakoff syndrome (Yoneoka *et al.*, 2004).

On the other hand, animal models have consistently shown the role that MTT play in spatial navigation (Vann *et al.*, 2011; Jankowski *et al.*, 2013; Vann & Nelson, 2015). Using rat models in the T-maze, radial-arm maze and water maze, difficulties on learning new spatial information (allocentric) were impaired after MTT lesions (Vann & Aggleton, 2003). Overall, animal and lesion model has consistently show that MTT inputs to the ATN are crucial for normal episodic and spatial memory. But there is, to our knowledge, no evidence how damage to this structure might impact on the symptomology in AD.

Anterior Thalamic Nucleus

Within the thalamic nuclei, the ATN is a highly interconnected region connecting key limbic areas. It can be subdivided into an anterior medial, anterior ventral and anterior dorsal nucleus (Aggleton & Sahgal, 1993), which receives densely projections from regions like the MB, hippocampus, retrosplenial cortex (RSC) and anterior cingulate cortex (ACC). While indirect hippocampal information reaches the ATN through the MTT, fibres passing exclusively through the fornix connects the ATN directly with the hippocampus (Thomas *et al.*, 2011). Arising from the presubiculum and parasubiculum, hippocampal projections connects the anterior ventral nucleus, while the anterior medial nucleus is predominantly innervated by the subiculum (Aggleton & Sahgal, 1993). Unlike the mammillothalamic pathway, the direct ATN and hippocampal connections are reciprocal, with projections arising from the ATN reaching the subiculum, presubiculum and parasubiculum (Aggleton & Sahgal, 1993; Aggleton *et al.*, 2010). Finally, among the cingulate cortex, the ATN possesses densely reciprocal connections with medial posterior brain regions, especially the RSC (Aggleton & Sahgal, 1993; Bubb *et al.*, 2017).

The ATN has received increasing interest, due to its i) dense reciprocal connections with the hippocampus and the RSC (Aggleton, 2012; Jankowski *et al.*, 2013; Aggleton *et al.*, 2016; Bubb *et al.*, 2017), ii) its role in cognition (Aggleton, 2012; Hornberger *et al.*, 2012; Jankowski *et al.*, 2013; Aggleton *et al.*, 2016) and iii) its vulnerability to neurodegenerative diseases (Nestor *et al.*, 2003; Schroeter *et al.*, 2009; Hornberger *et al.*, 2012; Ryan *et al.*, 2013; Aggleton *et al.*, 2016; Tentolouris-Piperas *et al.*, 2017). Beyond the medial temporal lobe, marked neurofibrillary changes have been found in the anterodorsal thalamus at the same time as the hippocampus in AD (Braak & Braak, 1991; Aggleton *et al.*, 2016). Also, substantial atrophy (Callen *et al.*, 2001; de Jong *et al.*, 2008; Zarei *et al.*, 2010), decreased blood perfusion (Kobayashi *et al.*, 2008), hypometabolism (Nestor *et al.*, 2003; Villain *et al.*, 2008), and altered connectivity (Zarei *et al.*, 2010; Wang *et al.*, 2020) of the ATN have been described in AD. The focus now is to understand if thalamic abnormalities in AD are secondary process due to medial temporal lobe dysfunction or occur at early stages of the disease.

According to the first point of view, thalamic and extra-hippocampal dysfunction would be a response of a 'disconnection process', akin to Wallerian degeneration, resulting due to hippocampal atrophy followed by white matter changes, with the cingulum bundle and the fornix playing a critical role (Villain *et al.*, 2008; Wang *et al.*, 2020). For example, a meta-

analysis concluded that the hippocampal formation is the first affected region in amnesic MCI, followed by later changes in the limbic thalamus in AD (Schroeter *et al.*, 2009). By contrast, other findings suggest that thalamic abnormalities occur in the earliest stages of AD (Aggleton *et al.*, 2016). For instance, hypometabolism and significant volume reduction in the anterior thalamus has been associated with very earlier stages of AD, and even MCI (Nestor *et al.*, 2003; de Jong *et al.*, 2008). Also, altered connectivity patterns in the thalamus have been described in MCI and AD (Rose *et al.*, 2006; Zhou *et al.*, 2013).

A substantial amount of evidence has also shown thalamic changes in AD. For instance, reduced thalamic volumes, increased fractional anisotropy and increased mean diffusivity have been described in PMC and SMC *PSEN1* carriers (Ryan *et al.*, 2013; Sala-Lluch *et al.*, 2015; Pardiella-Delgado *et al.*, 2021). Changes that have been described, even 15 years prior to symptom onset (Lee *et al.*, 2013). Furthermore, the thalamus has been described as one of the earliest sites of amyloid deposition (Knight *et al.*, 2011b). Similar findings are reported in relation to *APOE4*, as decreased thalamic volume and altered functional connectivity have been described in cognitively healthy and MCI *APOE4* carriers (Patel *et al.*, 2013; Li *et al.*, 2014; Novellino *et al.*, 2019).

The ATN, as well as the hippocampus, plays a critical role in episodic memory and spatial navigation. Specifically, the ATN has been described as critical for recollective memory rather than familiarity-based recognition (Aggleton *et al.*, 2010; Aggleton *et al.*, 2011; de Bourbon-Teles *et al.*, 2014). In very early symptomatic AD when memory impairment is an isolated feature, hypometabolism in a “limbic-diencephalic” network, where the thalamus plays a critical role, has been identified (Acosta-Cabronero & Nestor, 2014) with metabolic function been crucial for episodic memory performance in AD (Desgranges *et al.*, 2002; Salmon *et al.*, 2009). Moreover, altered thalamic functional connectivity has been related with difficulties in memory task in amnesic MCI (aMCI) *APOE* non carriers (Cai *et al.*, 2015), and MCI *APOE4* carriers (Li *et al.*, 2014; Novellino *et al.*, 2019).

Regarding navigation, head directions cells, interaction between the allocentric—egocentric navigation system, and navigation capacity are all mediated by the ATN accompanied by frontal, temporal and parietal regions (Coughlan *et al.*, 2018). However, to our knowledge, there are no studies having investigated spatial navigation impairment in relation to thalamic changes in AD.

Cingulum Bundle

The cingulum bundle is one of the most prominent white matter tracts that connects frontal, parietal and temporal cortices, as well as subcortical structures. It almost forms a ring from the orbital prefrontal cortex going through the dorsal surface of the corpus callosum up to the temporal pole through the PHC. There is no clear consensus on how to subdivide the cingulum bundle due to its complexity and length (Bubb *et al.*, 2018), but most literature analysing white matter changes on neurodegenerative diseases has focussed on the rostral/anterior and caudal/posterior cingulum (e.g., (Fouquet *et al.*, 2009; Acosta-Cabronero *et al.*, 2010; Villain *et al.*, 2010; Agosta *et al.*, 2012)). While others have also considered the parahippocampal/temporal cingulum bundle (e.g., (Metzler-Baddeley *et al.*, 2011; Daianu *et al.*, 2016)).

Increased absolute (axial, radial, and mean) diffusivity in AD has been described in critical white matter tracts connecting Papez circuit, like the parahippocampal gyrus, posterior cingulum, splenium and fornix (Acosta-Cabronero *et al.*, 2010). Specifically in the cingulum, significantly lower fractional anisotropy values in AD compared with healthy older adults has been reported (Stricker *et al.*, 2009). As well as cingulum fibre loss associated with decreased metabolism in the posterior cingulate and the orbitofrontal cortices in early AD (Villain *et al.*, 2010).

Interestingly, disruptions of the cingulum bundle have already been described in MCI. It seems that the cingulum plays a critical role in connecting areas of the Default Mode Network (DMN), as synchronic hypoactivation of the hippocampus and posterior cingulate cortex (PCC) measured with fMRI may reflect cingulum bundle disruption (Choo *et al.*, 2010; Villain *et al.*, 2010; Papma *et al.*, 2017). Increasing evidence points to an important role in this white matter tract as volume loss and decreased fractional anisotropy in the cingulum bundle have been reported as early as in aMCI (Kiuchi *et al.*, 2009; Wang *et al.*, 2009; Villain *et al.*, 2010). Fractional anisotropy decreased of the cingulum fibres has even been suggested as an early marker of AD (Zhang *et al.*, 2007). Although, both MCI and AD present with cingulum disruption, it appears that patterns of diminished fractional anisotropy distinctly affect MCI and AD. While no apparent differences in mild cingulum fractional anisotropy would be found in both groups, AD present decreased fractional anisotropy in the parahippocampal and posterior cingulum bundle, whereas MCI would only show significant fractional anisotropy decreased in the parahippocampal cingulum (Choo *et al.*, 2010).

When analysing white matter integrity of the cingulum bundle in ADAD, decreased fractional anisotropy and extensive white matter loss have been described in SMC and PMC (Ryan *et al.*, 2013; Araque Caballero *et al.*, 2018). Altered mean diffusivity in the cingulum bundle have also been reported in older *APOE4* carriers (Bendlin *et al.*, 2010; Adluru *et al.*, 2014). However, at this stage it is not yet clear how the cingulum structural changes (e.g., fractional anisotropy) impact on the well-known reduced network efficiency along the DMN (Hodgetts *et al.*, 2019), as DMN regions are partly connected via cingulum tracts (Cavedo *et al.*, 2017).

Consequently, cingulum white matter abnormalities have been related with cognitive impairment in AD. For instance, changes in the anisotropy of the cingulum bundle in MCI and AD has been associated with episodic memory deficit (Choo *et al.*, 2010; Sexton *et al.*, 2010). Evidence that is consistent with several studies showing hippocampal volume reduction and PCC hypometabolism mediated by the cingulate bundle disruption and its impact in episodic memory (Choo *et al.*, 2010; Villain *et al.*, 2010; Papma *et al.*, 2017). The cingulum contribution to spatial navigation remains less clear at this stage.

Posterior Cingulate cortex

Due to its cytoarchitectonic differentiation, regional circuitry and specificity in cognitive, motor and emotional processes, the cingulate cortex cannot be considered as one structure as Papez originally described (Papez, 1937; Vogt, 2009). Instead, we will be focusing on the posterior region of the cingulate cortex, referred to as PCC. The nomenclature of the posterior cingulate remains challenging with many people still referring to it as RSC, which is only a very small proportion of the PCC. Here we consider the PCC to comprise Brodmann areas 23, 29, 30, 31, which includes also the precuneus and the RSC (Vogt, 2009; Shah *et al.*, 2012; Rolls, 2019). Anatomically situated anteriorly to the parieto-occipital sulcus, posteriorly to the ventral anterior cingulate and located between the marginal ramus of the cingulate sulcus and the corpus callosum, the PCC is heavily interconnected with other limbic, paralimbic and cortical areas (Beckmann *et al.*, 2009; Leech & Sharp, 2014). Along its critical connections, white matter tracts emerge from the retrosplenial and ventral posterior cingulate cortex to connect the medial temporal lobes while dorsal posterior cingulate cortex connects the ventromedial prefrontal cortex along the cingulum bundle (Greicius *et al.*, 2009; Leech & Sharp, 2014).

The PCC is a core structure of the DMN (Buckner *et al.*, 2008), and it has been heavily associated with AD pathology (Callen *et al.*, 2001; Nestor *et al.*, 2003; Choo *et al.*, 2010). Conjointly evidence have consistently shown decreased PCC volume (Callen *et al.*, 2001; Choo *et al.*, 2010; Mutlu *et al.*, 2016), increased cortical thinning (Im *et al.*, 2008; Dickerson *et al.*, 2009), disrupted functional connectivity (Zhou *et al.*, 2008; Buckner *et al.*, 2009; Mutlu *et al.*, 2016), hypometabolism (Minoshima *et al.*, 1997; Nestor *et al.*, 2003; Salmon *et al.*, 2009; Villain *et al.*, 2010), and diffusion abnormalities (Rose *et al.*, 2008; Nakata *et al.*, 2009; Nir *et al.*, 2013) in AD. All these evidences have supported the notion that PCC abnormalities, form part of an AD “cortical signature” (Dickerson *et al.*, 2009).

Grey matter loss in the PCC (Choo *et al.*, 2010) and hypometabolism (Villain *et al.*, 2010) has also been reported in MCI. Notably, significant grey matter volume loss in the PCC has been associated with rapid converters in MCI towards probable AD (Chetelat *et al.*, 2005). Also, reduced connectivity and decreased fibres bundle from the PCC to the whole brain, have been described in MCI (Zhou *et al.*, 2008). More specifically, evidence has shown disrupted functional connectivity in a ventral PCC network (including the hippocampus, posterior occipitotemporal and temporoparietal regions) in aMCI (Mutlu *et al.*, 2016).

Evidence is also consistent when analysing ADAD reports. Even in PMC, volume loss (Fox *et al.*, 2001), hypometabolism (Mosconi *et al.*, 2006), and impaired functional connectivity (Chhatwal *et al.*, 2013) in the PCC have been reported. As a core structure of the DMN, functional disruption of the PCC is evident in presymptomatic ADAD and continue worsening in more advanced stages of the disease (Chhatwal *et al.*, 2013). Notably, impaired DMN functional connectivity before clinical symptomatology onset trace a similar pattern in ADAD and sporadic AD. However, this is not always the case for all biomarkers as PiB retention in PMC *PSEN1* is less intense than in sporadic AD (Klunk *et al.*, 2007) and no PCC white matter loss has been reported in PMC (Quan *et al.*, 2020).

Similarly, cognitively healthy *APOE4* carriers also shows PCC hypometabolism (Reiman *et al.*, 1996; Small *et al.*, 2000; Reiman *et al.*, 2004; Drzezga *et al.*, 2005), increased cortical thickness associated with age (Brown *et al.*, 2011), and altered functional connectivity (Filippini *et al.*, 2009; Dennis *et al.*, 2010; Sheline *et al.*, 2010; Westlye *et al.*, 2011). Likewise, sporadic AD and ADAD, *APOE4* carriers shows impaired functional connectivity on posterior regions of the DMN, including the PCC (Sheline *et al.*, 2010; Westlye *et al.*, 2011). Evidence has shown a more abruptly functional decline in *APOE4* carriers across age span which may

contribute with cognitive abilities rapidly decline (Brown *et al.*, 2011). Strikingly, *APOE4* carriers only present PCC grey matter loss when cognitive impairment is evident (Haller *et al.*, 2017).

The PCC, particularly the RSC, has also been characterized as a critical node in a hippocampal memory network (Tan *et al.*, 2014). Evidence in AD have consistently shown that PCC impairment is associated with episodic memory impairment (Choo *et al.*, 2010; Irish *et al.*, 2014; Leech & Sharp, 2014). It seems that hypometabolism and PCC functional impairment are, at least, partially responsible for aMCI and AD episodic memory decline (La Joie *et al.*, 2014; Mutlu *et al.*, 2016). Interestingly, in *APOE4* carriers reduced PCC glucose metabolic rates have been associated with greater memory impairment (Small *et al.*, 2000).

The PCC has also been heavily associated with spatial navigation and orientation (Leech & Sharp, 2014; Coughlan *et al.*, 2018; Coughlan *et al.*, 2020) characterized as critical for normal integration of egocentric and allocentric spatial information (Coughlan *et al.*, 2018), a function that has been associated with cognitive deficits in early AD (Tu *et al.*, 2015; Coughlan *et al.*, 2018). Difficulties that have been also reported in homozygous healthy *APOE4* carriers (Laczo *et al.*, 2014) and aMCI (Hort *et al.*, 2007) with the latest presenting more difficulties on allocentric orientation. Even though studies have shown that *PSEN1* and *APP* carriers show changes to PCC thickness 8 years prior clinical symptom onset (Weston *et al.*, 2016), to our knowledge no studies have been conducted in these population when assessing spatial navigation abilities.

Anterior Parahippocampal Cortex

The PHC encompass a large part of the temporal lobe, located between the hippocampus and the fusiform gyrus. Caudally including the entorhinal and perirhinal cortex and posteriorly ending with the occipital cortex (Aminoff *et al.*, 2013), the PHC is classically divided into an anterior and posterior region (Powell *et al.*, 2004). The anterior PHC (aPHC) is a significant part of the Papez circuit as it is strongly connected with areas of the DMN (Baldassano *et al.*, 2013), the RSC (Aminoff *et al.*, 2013), and it has strong reciprocal connections with the hippocampus (Powell *et al.*, 2004) playing an important role in episodic memory and spatial navigation (Baldassano *et al.*, 2013). For instance, animal models have shown that EC projections, through perirhinal and postrhinal connections to the hippocampus, forms the main extrahippocampal network within medial temporal lobe structures (Burwell & Amaral, 1998; van Strien *et al.*, 2009). Perirhinal—lateral EC pathway has even been

described as critical for object—space association, having a direct impact in spatial memory and spatial information processing (Connor & Knierim, 2017). For the review we only focus, therefore, on the aPHC as it has more relevance for AD pathophysiology.

Evidence has shown that there is a specific aPHC vulnerability to pathological changes in AD, with its entorhinal and perirhinal subdivisions most significantly affected (Van Hoesen *et al.*, 2000; Desgranges *et al.*, 2002; Im *et al.*, 2008). Specifically, structural changes have been detected in anterior regions of the transentorhinal and entorhinal cortex 9—14 and 8—11 years respectively, prior to a diagnosis of MCI (Kulason *et al.*, 2020). Compared to healthy controls, AD patients show aPHC volume decreases (Frisoni *et al.*, 1999; Callen *et al.*, 2001; Carter *et al.*, 2014; Mutlu *et al.*, 2016), hypometabolism (Salmon *et al.*, 2009), white matter abnormalities (Zhang *et al.*, 2007; Rose *et al.*, 2008; Choo *et al.*, 2010), loss of cortical thickness (Im *et al.*, 2008) and functional connectivity disruption (Mutlu *et al.*, 2016). Furthermore, studies in MCI have also found lower fractional anisotropy values (Zhang *et al.*, 2007; Mutlu *et al.*, 2016), altered functional connectivity (Mutlu *et al.*, 2016; Wang *et al.*, 2020) and loss of cortical thickness (Wang *et al.*, 2009).

Contrary to sporadic AD, reports on aPHC abnormalities in ADAD are somehow inconsistent. Some studies investigating atrophy, cortical thinning and white matter pathology cross-sectionally and longitudinally (Knight *et al.*, 2011a; Cash *et al.*, 2013) have reported no significant results in the aPHC. By contrast, other studies have shown increased tau accumulation (Quiroz *et al.*, 2018) and decreased metabolism in the PHC, when compared with sporadic AD (Mosconi *et al.*, 2003).

APOE4 carriers, on the other hand, have consistently shown to have aPHC changes, even when cognitively healthy. A couple of studies have described lower fractional anisotropy in parahippocampal white matter tracts in healthy *APOE4* carriers compared with non-carriers (Nierenberg *et al.*, 2005; Honea *et al.*, 2009). Disrupted functional connectivity in the aPHC, have also been reported in active (Dennis *et al.*, 2010) and resting state fMRI in *APEO4* carriers (Sheline *et al.*, 2010; Machulda *et al.*, 2011; Westlye *et al.*, 2011).

On a cognitive level, the aPHC has been consistently associated with episodic memory (Desgranges *et al.*, 2002; Nestor *et al.*, 2006; Lin *et al.*, 2014), spatial navigation (Moscovitch *et al.*, 2006; Suthana *et al.*, 2009; Coughlan *et al.*, 2018) and is also considered to be a crucial node for the DMN (Buckner *et al.*, 2008). Interestingly, episodic memory deficits and aPHC

changes have been described in early stages of the disease with no significant association in the more severe stages of AD (Desgranges *et al.*, 2002).

Discussion

The present review highlights the structural and functional integrity of Papez circuit in *APOE4* carriers (at genetic-risk AD), mild cognitive impairment (MCI), sporadic AD and ADAD (including PMC and SMC). We further analysed how different Papez circuit subregions are involved in the main cognitive symptomology of AD.

Contrary to Papez' original conception of a serial circuit (Papez, 1937), a better understanding regarding this network is of parallel and reciprocal connections between critical limbic structures with the hippocampus, the ATN and the PCC, as key hubs. With the exception of the MTT, evidence showing structural and functional impairment along Papez circuit in AD is abundant (Table 1). At clinical presentation, both sporadic AD and ADAD present similar grey and white matter pathology for the hippocampus, PCC, ATN and fornix. Still despite similar cognitive impairment in ADAD and sporadic AD there are differences in aPHC vulnerability, as no significant changes have been reported in ADAD (Cash *et al.*, 2013) but altered functional connectivity and loss of cortical thickness have been reported in sporadic AD (Wang *et al.*, 2009; Mutlu *et al.*, 2016).

Interestingly, while sporadic AD has been typically associated with atrophy of primarily the hippocampus, ADAD might not follow the same path. Evidence in PMC (*PSEN1*) shows more of a nonlinear hippocampal atrophic trajectory. Specifically, it appears that changes in the PCC (Fortea *et al.*, 2010; Apostolova *et al.*, 2011; Sala-Llonch *et al.*, 2015) and thalamus are evident years before expected symptom onset (Ryan *et al.*, 2013), whereas hippocampal changes occur only shortly before symptom onset (Lee *et al.*, 2013). This would suggest that structural and functional changes in ADAD can be first observed in the PCC before progressing to the temporal cortex (Benzinger *et al.*, 2013). This notion is further confirmed as no macroscopic changes in the lateral temporal cortex have been reported in PMC (Knight *et al.*, 2011a), with changes only emerging in mildly symptomatic ADAD (Cash *et al.*, 2013).

Furthermore, evidence of thalamic involvement along different stages of AD has been consistently described. Progressive cognitive impairment in MCI towards AD have been associated with increasing thalamic volume reduction (Bernstein *et al.*, 2021) along with changes to thalamic functional connectivity (Aggleton *et al.*, 2016). There have been also suggestions that thalamic changes might have prognostic value to determine the conversion

from aMCI to AD (de Oliveira *et al.*, 2011), which clearly needs to be investigated further. Thalamic changes are also common in ADAD, but have so far not been associated with cognitive worsening, despite reduced thalamic integrity reported up to 15 years before symptom onset (Lee *et al.*, 2013). Notably, PMC white matter changes along the cingulum bundle has been limited to the anterior thalamic tracts projecting to the cingulate cortex and the hippocampus (Ryan *et al.*, 2013), while hippocampal cingulum bundle alterations appear only in SMC (Araque Caballero *et al.*, 2018). It is still debated as to whether ADAD is similar in its disease trajectory to sporadic AD, however, considering these findings, it might be more the PCC and the ATN than the hippocampus which should be the focus in PMC, with the hippocampus only giving an indication of when patients convert to clinical symptoms. One intriguing question is, as to whether current clinical symptomology is too 'crude' to detect extra-hippocampal changes in the Papez circuit network?

Another intriguing finding is that *APOE4* carriers show a similar relationship between decreased PCC grey matter and cognitive impairment onset (Haller *et al.*, 2017). Even more striking is the fact that *APOE4* carriers can present hippocampal volume reduction (Honea *et al.*, 2009; O'Dwyer *et al.*, 2012), altered hippocampal functional connectivity (Li *et al.*, 2014), fornix white matter disruption (Zhang *et al.*, 2015), thalamic functional abnormalities (Patel *et al.*, 2013; Li *et al.*, 2014), and parahippocampal white matter pathology (Nierenberg *et al.*, 2005) with no apparent cognitive impairment on clinical tests. At this stage it is not clear in how far cognitive reserve processes might contribute to the lack of clinical cognitive symptoms in this group, despite them having clear changes in several Papez circuit regions. Again, the PCC emerges as a critical region to explore further to determine how it might contribute to the disease and cognitive impairment developing in *APOE*.

Overall, AD associated structural and functional changes can be noted along several Papez circuit regions even when no clinical symptomatology is evident. Although hippocampal changes have been commonly associated with early AD neuropathology, emerging evidence has consistently show that other Papez circuit regions are also vulnerable in the earliest stage of AD. Even in PMC and healthy *APOE4* carriers, various Papez circuit region, along with the hippocampus, show already neuroimaging changes. In particular, our review highlights that subcortical structures and posterior parietal regions are highly susceptible to AD pathophysiology in ADAD and healthy *APOE4* carriers.

Far from being exclusively implicated in episodic memory, there is increasing evidence showing that Papez circuit plays a role in both, episodic memory and spatial navigation/orientation. It becomes increasingly clear that the core network for navigation is highly vulnerable to AD pathophysiology, even in prodromal stages of the disease (Coughlan *et al.*, 2018). Together, the EC and the PCC are consistently described as crucial for spatial navigation, as they are critical for path integration and normal egocentric and allocentric spatial information integration (Howett *et al.*, 2019; Coughlan *et al.*, 2020). Even in at-genetic risk subjects, path integration deficits related to EC grey matter volume and changes in grid cell functioning are detected before potential disease onset (Bierbrauer *et al.*, 2020). Egocentric—allocentric deficits have been associated with an extensive cerebral spatial network covering the hippocampus, retrosplenial and parietal dysfunction in positive amyloid aMCI (Schoberl *et al.*, 2020). Deficits restricted to allocentric strategies in negative amyloid aMCI, suggesting preserved extrahippocampal egocentric strategies in this group (Schoberl *et al.*, 2020).

Less known is how spatial navigation and orientation are affected due to changes among other Papez circuit regions, as few, studies have investigated how spatial navigation is impaired in relation with ATN, and no study have analysed how fornix and MB changes affects spatial navigation in AD. A recent review already analysed the critical role of the limbic thalamus on spatial orientation and its impact in clinical symptomatology in prodromal AD, remarking the need for the development of specific cognitive measures that tap ATN dysfunction (Aggleton *et al.*, 2016).

Therefore, the need for future research to investigate how these subcortical and white matter structures vulnerability to AD pathology affects cognition and clinical symptomatology along different stages of the disease are still strongly needed. Finally, the PCC is a critical region to integrate allocentric and egocentric spatial navigation processes, due to its early involvement in sporadic AD and ADAD (PMC), the development of PCC specific spatial tests might shift the diagnostic goal post to identify ‘pre-symptomatic’ clinical symptoms.

Different approaches have been made recently to assess whether spatial navigation is sensitive to detect preclinical AD stage (Levine *et al.*, 2020; Bayat *et al.*, 2021) and at-genetic-risk (*APOE4*) (Coughlan *et al.*, 2020). Real world paradigms (Bayat *et al.*, 2021) and virtual navigation task studies (Howett *et al.*, 2019; Coughlan *et al.*, 2020; Levine *et al.*, 2020) have proved effective in identifying preclinical AD among older adults (Howett *et al.*, 2019; Coughlan *et al.*, 2020; Levine *et al.*, 2020; Bayat *et al.*, 2021). Spatial navigation and

orientation processes emerge, therefore, as potential more sensitive cognitive marker of AD pathophysiology than solely relying on episodic memory measures.

In summary, there is a clear need for future investigations to consider the Papez circuit as a network and explore how critical regions of this network are involved in AD pathophysiology progression. As emerging evidence is suggesting, regions such as the thalamus, fornix and the MB are closely related with AD neuropathology and progression (Ringman *et al.*, 2007). Despite their relevance, thalamus, fornix and MB changes and their impact in clinical symptomatology has not been studied thoroughly as other Papez circuit regions, especially the hippocampus. This might be in particular due to clinical scans often not capturing these subcortical regions, making it more difficult to take their integrity into account. However, on a research level there is clear indication to take the subcortical Papez circuit regions into account when investigating AD disease progression. Finally, the PCC emerges as a key region in the development of the disease in particular in *APOE4* carriers however the PCC is often overlooked in clinical investigation in comparison to hippocampal integrity and there are no validated cognitive measures to tap into its functionality. This clearly needs to be addressed in future investigations, along with longitudinal studies investigating Papez circuit integrity in AD progression.

Despite these intriguing findings, there are some important limitations to consider for the review. For example, many of the cited studies did not have biomarker confirmation for their participants. This means that most of the sporadic AD literature reviewed remains without pathophysiological of AD in those. Clearly this is more of an issue with MCI and not clinical AD but future investigations for the Papez circuit are needed which have biomarker-confirmed sporadic MCI and AD cases. Further, most of the studies reviewed were of a cross-sectional nature, except for most ADAD findings. It remains, therefore, to be explored in how far longitudinal changes in the Papez circuit network contributes to the disease progression and symptomatology in sporadic AD. Finally, as with any narrative review, a number of factors may differ between studies including age, educational level, neuropsychological protocols, sample size, or imaging acquisition parameters, to name a few. Once more systematic data is available for most Papez circuit structures, it would be therefore important to conduct systematic review or meta-analyses on the circuit for AD population. Regardless, we believe that the review provides a stepping stone towards a re-evaluation of the whole Papez circuit network in AD, moving away from a hippocampal-centric view.

Accepted Article

Taken together, the review highlights the importance of an extended network in the pathophysiology and clinical symptomatology of AD, the Papez circuit. There is substantive and consistent evidence that multiple Papez regions are affected by AD pathophysiology, with some affected before or concurrently with the hippocampus. Further, there is a main focus on episodic memory deficits due Papez circuit changes.

There is a clear need to rectify this since spatial disorientation is a common and early symptom in AD and animal studies have consistently shown that the Papez circuit is involved in spatial navigation tasks. This suggests that those regions likely contribute to spatial disorientation in AD, which needs further investigation. Overall, our evidence reinforces the notion that current AD diagnostics and research is too hippocampal and episodic memory centric, not taking into account other Papez circuit regions or spatial navigation deficits. Addressing those shortcomings will not only inform better research but also more importantly, improve AD patients diagnostic and disease management in the future.

Author Contribution

GF, ALL and MH all contributed to the content and writing of this review.

References

- Acosta-Cabronero, J. & Nestor, P.J. (2014) Diffusion tensor imaging in Alzheimer's disease: insights into the limbic-diencephalic network and methodological considerations. *Front Aging Neurosci*, **6**, 266.
- Acosta-Cabronero, J., Williams, G.B., Pengas, G. & Nestor, P.J. (2010) Absolute diffusivities define the landscape of white matter degeneration in Alzheimer's disease. *Brain*, **133**, 529-539.
- Adluru, N., Destiche, D.J., Lu, S.Y., Doran, S.T., Birdsill, A.C., Melah, K.E., Okonkwo, O.C., Alexander, A.L., Dowling, N.M., Johnson, S.C., Sager, M.A. & Bendlin, B.B. (2014) White matter microstructure in late middle-age: Effects of apolipoprotein E4 and parental family history of Alzheimer's disease. *Neuroimage Clin*, **4**, 730-742.
- Aggleton, J.P. (2012) Multiple anatomical systems embedded within the primate medial temporal lobe: implications for hippocampal function. *Neurosci Biobehav Rev*, **36**, 1579-1596.
- Aggleton, J.P. (2014) Looking beyond the hippocampus: old and new neurological targets for understanding memory disorders. *Proc Biol Sci*, **281**.
- Aggleton, J.P., Dumont, J.R. & Warburton, E.C. (2011) Unraveling the contributions of the diencephalon to recognition memory: a review. *Learn Mem*, **18**, 384-400.
- Aggleton, J.P., O'Mara, S.M., Vann, S.D., Wright, N.F., Tsanov, M. & Erichsen, J.T. (2010) Hippocampal-anterior thalamic pathways for memory: uncovering a network of direct and indirect actions *Eur J Neurosci*, **31**, 2292-2307.
- Aggleton, J.P., Pralus, A., Nelson, A.J. & Hornberger, M. (2016) Thalamic pathology and memory loss in early Alzheimer's disease: moving the focus from the medial temporal lobe to Papez circuit. *Brain*, **139**, 1877-1890.
- Aggleton, J.P. & Sahgal, A. (1993) The contribution of the anterior thalamic nuclei to anterograde amnesia. *Neuropsychologia*, **31**, 1001-1019.
- Agosta, F., Scola, E., Canu, E., Marcone, A., Magnani, G., Sarro, L., Copetti, M., Caso, F., Cerami, C., Comi, G., Cappa, S.F., Falini, A. & Filippi, M. (2012) White matter damage in frontotemporal lobar degeneration spectrum. *Cereb Cortex*, **22**, 2705-2714.
- Aminoff, E.M., Kveraga, K. & Bar, M. (2013) The role of the parahippocampal cortex in cognition. *Trends Cogn Sci*, **17**, 379-390.
- Apostolova, L.G., Hwang, K.S., Medina, L.D., Green, A.E., Braskie, M.N., Dutton, R.A., Lai, J., Geschwind, D.H., Cummings, J.L., Thompson, P.M. & Ringman, J.M. (2011) Cortical and hippocampal atrophy in patients with autosomal dominant familial Alzheimer's disease. *Dement Geriatr Cogn Disord*, **32**, 118-125.

Araque Caballero, M.A., Suarez-Calvet, M., Duering, M., Franzmeier, N., Benzinger, T., Fagan, A.M., Bateman, R.J., Jack, C.R., Levin, J., Dichgans, M., Jucker, M., Karch, C., Masters, C.L., Morris, J.C., Weiner, M., Rossor, M., Fox, N.C., Lee, J.H., Salloway, S., Danek, A., Goate, A., Yakushev, I., Hassenstab, J., Schofield, P.R., Haass, C. & Ewers, M. (2018) White matter diffusion alterations precede symptom onset in autosomal dominant Alzheimer's disease. *Brain*, **141**, 3065-3080.

Baldassano, C., Beck, D.M. & Fei-Fei, L. (2013) Differential connectivity within the Parahippocampal Place Area. *Neuroimage*, **75**, 228-237.

Baloyannis, S.J., Mavroudis, I., Baloyannis, I.S. & Costa, V.G. (2016) Mammillary Bodies in Alzheimer's Disease: A Golgi and Electron Microscope Study. *Am J Alzheimers Dis Other Demen*, **31**, 247-256.

Bateman, R.J., Xiong, C., Benzinger, T.L., Fagan, A.M., Goate, A., Fox, N.C., Marcus, D.S., Cairns, N.J., Xie, X., Blazey, T.M., Holtzman, D.M., Santacruz, A., Buckles, V., Oliver, A., Moulder, K., Aisen, P.S., Ghetti, B., Klunk, W.E., McDade, E., Martins, R.N., Masters, C.L., Mayeux, R., Ringman, J.M., Rossor, M.N., Schofield, P.R., Sperling, R.A., Salloway, S., Morris, J.C. & Dominantly Inherited Alzheimer, N. (2012) Clinical and biomarker changes in dominantly inherited Alzheimer's disease. *N Engl J Med*, **367**, 795-804.

Bayat, S., Babulal, G.M., Schindler, S.E., Fagan, A.M., Morris, J.C., Mihailidis, A. & Roe, C.M. (2021) GPS driving: a digital biomarker for preclinical Alzheimer disease. *Alzheimers Res Ther*, **13**, 115.

Beckmann, M., Johansen-Berg, H. & Rushworth, M.F. (2009) Connectivity-based parcellation of human cingulate cortex and its relation to functional specialization. *J Neurosci*, **29**, 1175-1190.

Bendlin, B.B., Ries, M.L., Canu, E., Sodhi, A., Lazar, M., Alexander, A.L., Carlsson, C.M., Sager, M.A., Asthana, S. & Johnson, S.C. (2010) White matter is altered with parental family history of Alzheimer's disease. *Alzheimers Dement*, **6**, 394-403.

Benzinger, T.L., Blazey, T., Jack, C.R., Jr., Koeppe, R.A., Su, Y., Xiong, C., Raichle, M.E., Snyder, A.Z., Ances, B.M., Bateman, R.J., Cairns, N.J., Fagan, A.M., Goate, A., Marcus, D.S., Aisen, P.S., Christensen, J.J., Ercole, L., Hornbeck, R.C., Farrar, A.M., Aldea, P., Jasielec, M.S., Owen, C.J., Xie, X., Mayeux, R., Brickman, A., McDade, E., Klunk, W., Mathis, C.A., Ringman, J., Thompson, P.M., Ghetti, B., Saykin, A.J., Sperling, R.A., Johnson, K.A., Salloway, S., Correia, S., Schofield, P.R., Masters, C.L., Rowe, C., Villemagne, V.L., Martins, R., Ourselin, S., Rossor, M.N., Fox, N.C., Cash, D.M., Weiner, M.W., Holtzman, D.M., Buckles, V.D., Moulder, K. & Morris, J.C. (2013) Regional variability of imaging biomarkers in autosomal dominant Alzheimer's disease. *Proc Natl Acad Sci U S A*, **110**, E4502-4509.

Bernstein, A.S., Rapcsak, S.Z., Hornberger, M., Saranathan, M. & Alzheimer's Disease Neuroimaging, I. (2021) Structural Changes in Thalamic Nuclei Across Prodromal and Clinical Alzheimer's Disease. *J Alzheimers Dis*.

Bierbrauer, A., Kunz, L., Gomes, C.A., Luhmann, M., Deuker, L., Getzmann, S., Wascher, E., Gajewski, P.D., Hengstler, J.G., Fernandez-Alvarez, M., Atienza, M., Cammisuli, D.M., Bonatti, F., Pruneti, C., Percesepe, A., Bellaali, Y., Hanseeuw, B., Strange, B.A., Cantero, J.L. & Axmacher, N. (2020) Unmasking selective path integration deficits in Alzheimer's disease risk carriers. *Sci Adv*, **6**, eaba1394.

Braak, H. & Braak, E. (1991) Neuropathological staging of Alzheimer-related changes. *Acta Neuropathol*, **82**, 239-259.

Brown, J.A., Terashima, K.H., Burggren, A.C., Ercoli, L.M., Miller, K.J., Small, G.W. & Bookheimer, S.Y. (2011) Brain network local interconnectivity loss in aging APOE-4 allele carriers. *Proc Natl Acad Sci U S A*, **108**, 20760-20765.

Bubb, E.J., Kinnavane, L. & Aggleton, J.P. (2017) Hippocampal - diencephalic - cingulate networks for memory and emotion: An anatomical guide. *Brain Neurosci Adv*, **1**.

Bubb, E.J., Metzler-Baddeley, C. & Aggleton, J.P. (2018) The cingulum bundle: Anatomy, function, and dysfunction. *Neurosci Biobehav Rev*, **92**, 104-127.

Buckner, R.L., Andrews-Hanna, J.R. & Schacter, D.L. (2008) The brain's default network: anatomy, function, and relevance to disease. *Ann N Y Acad Sci*, **1124**, 1-38.

Buckner, R.L., Sepulcre, J., Talukdar, T., Krienen, F.M., Liu, H., Hedden, T., Andrews-Hanna, J.R., Sperling, R.A. & Johnson, K.A. (2009) Cortical hubs revealed by intrinsic functional connectivity: mapping, assessment of stability, and relation to Alzheimer's disease. *J Neurosci*, **29**, 1860-1873.

Bueno, A.P.A., de Souza, L.C., Pinaya, W.H.L., Teixeira, A.L., de Prado, L.G.R., Caramelli, P., Hornberger, M. & Sato, J.R. (2020) Papez Circuit Gray Matter and Episodic Memory in Amyotrophic Lateral Sclerosis and Behavioural Variant Frontotemporal Dementia. *Brain Imaging Behav*.

Burwell, R.D. & Amaral, D.G. (1998) Cortical afferents of the perirhinal, postrhinal, and entorhinal cortices of the rat. *J Comp Neurol*, **398**, 179-205.

Cai, S., Huang, L., Zou, J., Jing, L., Zhai, B., Ji, G., von Deneen, K.M., Ren, J., Ren, A. & Alzheimer's Disease Neuroimaging, I. (2015) Changes in thalamic connectivity in the early and late stages of amnesic mild cognitive impairment: a resting-state functional magnetic resonance study from ADNI. *PLoS One*, **10**, e0115573.

Callen, D.J., Black, S.E., Gao, F., Caldwell, C.B. & Szalai, J.P. (2001) Beyond the hippocampus: MRI volumetry confirms widespread limbic atrophy in AD. *Neurology*, **57**, 1669-1674.

- Carlesimo, G.A., Lombardi, M.G. & Caltagirone, C. (2011) Vascular thalamic amnesia: a reappraisal. *Neuropsychologia*, **49**, 777-789.
- Carlesimo, G.A., Piras, F., Orfei, M.D., Iorio, M., Caltagirone, C. & Spalletta, G. (2015) Atrophy of presubiculum and subiculum is the earliest hippocampal anatomical marker of Alzheimer's disease. *Alzheimers Dement (Amst)*, **1**, 24-32.
- Carter, S.F., Embleton, K.V., Anton-Rodriguez, J.M., Burns, A., Ralph, M.A. & Herholz, K. (2014) Regional neuronal network failure and cognition in late-onset sporadic Alzheimer disease. *AJNR Am J Neuroradiol*, **35**, S18-30.
- Cash, D.M., Ridgway, G.R., Liang, Y., Ryan, N.S., Kinnunen, K.M., Yeatman, T., Malone, I.B., Benzinger, T.L., Jack, C.R., Jr., Thompson, P.M., Ghetti, B.F., Saykin, A.J., Masters, C.L., Ringman, J.M., Salloway, S.P., Schofield, P.R., Sperling, R.A., Cairns, N.J., Marcus, D.S., Xiong, C., Bateman, R.J., Morris, J.C., Rossor, M.N., Ourselin, S., Fox, N.C. & Dominantly Inherited Alzheimer, N. (2013) The pattern of atrophy in familial Alzheimer disease: volumetric MRI results from the DIAN study. *Neurology*, **81**, 1425-1433.
- Cavedo, E., Lista, S., Rojkova, K., Chiesa, P.A., Houot, M., Brueggen, K., Blautzik, J., Bokde, A.L.W., Dubois, B., Barkhof, F., Pouwels, P.J.W., Teipel, S., Hampel, H. & Alzheimer Precision Medicine, I. (2017) Disrupted white matter structural networks in healthy older adult APOE epsilon4 carriers - An international multicenter DTI study. *Neuroscience*, **357**, 119-133.
- Cerman, J., Andel, R., Laczó, J., Vyhnaček, M., Nedelska, Z., Mokrisová, I., Sheardová, K. & Hort, J. (2018) Subjective Spatial Navigation Complaints - A Frequent Symptom Reported by Patients with Subjective Cognitive Decline, Mild Cognitive Impairment and Alzheimer's Disease. *Curr Alzheimer Res*, **15**, 219-228.
- Cherubini, A., Peran, P., Spoletini, I., Di Paola, M., Di Iulio, F., Hagberg, G.E., Sancesario, G., Gianni, W., Bossu, P., Caltagirone, C., Sabatini, U. & Spalletta, G. (2010) Combined volumetry and DTI in subcortical structures of mild cognitive impairment and Alzheimer's disease patients. *J Alzheimers Dis*, **19**, 1273-1282.
- Chetelat, G., Landeau, B., Eustache, F., Mezenge, F., Viader, F., de la Sayette, V., Desgranges, B. & Baron, J.C. (2005) Using voxel-based morphometry to map the structural changes associated with rapid conversion in MCI: a longitudinal MRI study. *Neuroimage*, **27**, 934-946.
- Chhatwal, J.P., Schultz, A.P., Johnson, K., Benzinger, T.L., Jack, C., Jr., Ances, B.M., Sullivan, C.A., Salloway, S.P., Ringman, J.M., Koeppe, R.A., Marcus, D.S., Thompson, P., Saykin, A.J., Correia, S., Schofield, P.R., Rowe, C.C., Fox, N.C., Brickman, A.M., Mayeux, R., McDade, E., Bateman, R., Fagan, A.M., Goate, A.M., Xiong, C., Buckles, V.D., Morris, J.C. & Sperling, R.A. (2013) Impaired default network functional connectivity in autosomal dominant Alzheimer disease. *Neurology*, **81**, 736-744.

Choo, I.H., Lee, D.Y., Oh, J.S., Lee, J.S., Lee, D.S., Song, I.C., Youn, J.C., Kim, S.G., Kim, K.W., Jhoo, J.H. & Woo, J.I. (2010) Posterior cingulate cortex atrophy and regional cingulum disruption in mild cognitive impairment and Alzheimer's disease. *Neurobiol Aging*, **31**, 772-779.

Connor, C.E. & Knierim, J.J. (2017) Integration of objects and space in perception and memory. *Nat Neurosci*, **20**, 1493-1503.

Copenhaver, B.R., Rabin, L.A., Saykin, A.J., Roth, R.M., Wishart, H.A., Flashman, L.A., Santulli, R.B., McHugh, T.L. & Mamourian, A.C. (2006) The fornix and mammillary bodies in older adults with Alzheimer's disease, mild cognitive impairment, and cognitive complaints: a volumetric MRI study. *Psychiatry Res*, **147**, 93-103.

Coughlan, G., Laczó, J., Hort, J., Minihane, A.M. & Hornberger, M. (2018) Spatial navigation deficits - overlooked cognitive marker for preclinical Alzheimer disease? *Nat Rev Neurol*, **14**, 496-506.

Coughlan, G., Zhukovsky, P., Puthusserypady, V., Gillings, R., Minihane, A.M., Cameron, D. & Hornberger, M. (2020) Functional connectivity between the entorhinal and posterior cingulate cortices underpins navigation discrepancies in at-risk Alzheimer's disease. *Neurobiol Aging*, **90**, 110-118.

Crivello, F., Lemaître, H., Dufouil, C., Grassiot, B., Delcroix, N., Tzourio-Mazoyer, N., Tzourio, C. & Mazoyer, B. (2010) Effects of ApoE- ϵ 4 allele load and age on the rates of grey matter and hippocampal volumes loss in a longitudinal cohort of 1186 healthy elderly persons. *Neuroimage*, **53**, 1064-1069.

Dahmani, L., Courcot, B., Near, J., Patel, R., Amaral, R.S.C., Chakravarty, M.M. & Bohbot, V.D. (2019) Fimbria-Fornix Volume Is Associated With Spatial Memory and Olfactory Identification in Humans. *Front Syst Neurosci*, **13**, 87.

Daianu, M., Mendez, M.F., Baboyan, V.G., Jin, Y., Melrose, R.J., Jimenez, E.E. & Thompson, P.M. (2016) An advanced white matter tract analysis in frontotemporal dementia and early-onset Alzheimer's disease. *Brain Imaging Behav*, **10**, 1038-1053.

Dalton, M.A., McCormick, C. & Maguire, E.A. (2019) Differences in functional connectivity along the anterior-posterior axis of human hippocampal subfields. *Neuroimage*, **192**, 38-51.

Danet, L., Barbeau, E.J., Eustache, P., Planton, M., Raposo, N., Sibon, I., Albucher, J.F., Bonneville, F., Peran, P. & Pariente, J. (2015) Thalamic amnesia after infarct: The role of the mammillothalamic tract and mediodorsal nucleus. *Neurology*, **85**, 2107-2115.

de Bourbon-Teles, J., Bentley, P., Koshino, S., Shah, K., Dutta, A., Malhotra, P., Egner, T., Husain, M. & Soto, D. (2014) Thalamic control of human attention driven by memory and learning. *Curr Biol*, **24**, 993-999.

- de Jong, L.W., van der Hiele, K., Veer, I.M., Houwing, J.J., Westendorp, R.G., Bollen, E.L., de Bruin, P.W., Middelkoop, H.A., van Buchem, M.A. & van der Grond, J. (2008) Strongly reduced volumes of putamen and thalamus in Alzheimer's disease: an MRI study. *Brain*, **131**, 3277-3285.
- de Oliveira, M.S., Balthazar, M.L.F., D'Abreu, A., Yasuda, C.L., Damasceno, B.P., Cendes, F. & Castellano, G. (2011) MR Imaging Texture Analysis of the Corpus Callosum and Thalamus in Amnesic Mild Cognitive Impairment and Mild Alzheimer Disease. *Am J Neuroradiol*, **32**, 60-66.
- den Heijer, T., der Lijn, F., Vernooij, M.W., de Groot, M., Koudstaal, P.J., van der Lugt, A., Krestin, G.P., Hofman, A., Niessen, W.J. & Breteler, M.M. (2012) Structural and diffusion MRI measures of the hippocampus and memory performance. *Neuroimage*, **63**, 1782-1789.
- Dennis, N.A., Browndyke, J.N., Stokes, J., Need, A., Burke, J.R., Welsh-Bohmer, K.A. & Cabeza, R. (2010) Temporal lobe functional activity and connectivity in young adult APOE varepsilon4 carriers. *Alzheimers Dement*, **6**, 303-311.
- Desgranges, B., Baron, J.C., Lavee, C., Giffard, B., Viader, F., de La Sayette, V. & Eustache, F. (2002) The neural substrates of episodic memory impairment in Alzheimer's disease as revealed by FDG-PET: relationship to degree of deterioration. *Brain*, **125**, 1116-1124.
- Dickerson, B.C., Bakkour, A., Salat, D.H., Feczko, E., Pacheco, J., Greve, D.N., Grodstein, F., Wright, C.I., Blacker, D., Rosas, H.D., Sperling, R.A., Atri, A., Growdon, J.H., Hyman, B.T., Morris, J.C., Fischl, B. & Buckner, R.L. (2009) The cortical signature of Alzheimer's disease: regionally specific cortical thinning relates to symptom severity in very mild to mild AD dementia and is detectable in asymptomatic amyloid-positive individuals. *Cereb Cortex*, **19**, 497-510.
- Drzezga, A., Riemenschneider, M., Strassner, B., Grimmer, T., Peller, M., Knoll, A., Wagenpfeil, S., Minoshima, S., Schwaiger, M. & Kurz, A. (2005) Cerebral glucose metabolism in patients with AD and different APOE genotypes. *Neurology*, **64**, 102-107.
- Dusoir, H., Kapur, N., Byrnes, D.P., McKinstry, S. & Hoare, R.D. (1990) The role of diencephalic pathology in human memory disorder. Evidence from a penetrating paranasal brain injury. *Brain*, **113 (Pt 6)**, 1695-1706.
- El Haj, M., Antoine, P., Amouyel, P., Lambert, J.C., Pasquier, F. & Kapogiannis, D. (2016) Apolipoprotein E (APOE) epsilon4 and episodic memory decline in Alzheimer's disease: A review. *Ageing Res Rev*, **27**, 15-22.
- Falgas, N., Sanchez-Valle, R., Bargallo, N., Balasa, M., Fernandez-Villullas, G., Bosch, B., Olives, J., Tort-Merino, A., Antonell, A., Munoz-Garcia, C., Leon, M., Grau, O., Castellvi, M., Coll-Padros, N., Rami, L., Redolfi, A. & Llado, A. (2019) Hippocampal atrophy has limited usefulness as a diagnostic biomarker on the early onset Alzheimer's disease patients: A comparison between visual and quantitative assessment. *Neuroimage Clin*, **23**, 101927.

- Filippini, N., MacIntosh, B.J., Hough, M.G., Goodwin, G.M., Frisoni, G.B., Smith, S.M., Matthews, P.M., Beckmann, C.F. & Mackay, C.E. (2009) Distinct patterns of brain activity in young carriers of the APOE-epsilon4 allele. *Proc Natl Acad Sci U S A*, **106**, 7209-7214.
- Fortea, J., Sala-Llonch, R., Bartres-Faz, D., Bosch, B., Llado, A., Bargallo, N., Molinuevo, J.L. & Sanchez-Valle, R. (2010) Increased cortical thickness and caudate volume precede atrophy in PSEN1 mutation carriers. *J Alzheimers Dis*, **22**, 909-922.
- Fouquet, M., Desgranges, B., Landeau, B., Duchesnay, E., Mezenge, F., de la Sayette, V., Viader, F., Baron, J.C., Eustache, F. & Chetelat, G. (2009) Longitudinal brain metabolic changes from amnesic mild cognitive impairment to Alzheimer's disease. *Brain*, **132**, 2058-2067.
- Fox, N.C., Crum, W.R., Scahill, R.I., Stevens, J.M., Janssen, J.C. & Rossor, M.N. (2001) Imaging of onset and progression of Alzheimer's disease with voxel-compression mapping of serial magnetic resonance images. *Lancet*, **358**, 201-205.
- Frisoni, G.B., Laakso, M.P., Beltramello, A., Geroldi, C., Bianchetti, A., Soininen, H. & Trabucchi, M. (1999) Hippocampal and entorhinal cortex atrophy in frontotemporal dementia and Alzheimer's disease. *Neurology*, **52**, 91-100.
- Greicius, M.D., Supekar, K., Menon, V. & Dougherty, R.F. (2009) Resting-state functional connectivity reflects structural connectivity in the default mode network. *Cereb Cortex*, **19**, 72-78.
- Grossi, D., Lopez, O.L. & Martinez, A.J. (1989) Mammillary bodies in Alzheimer's disease. *Acta Neurol Scand*, **80**, 41-45.
- Hafting, T., Fyhn, M., Molden, S., Moser, M.B. & Moser, E.I. (2005) Microstructure of a spatial map in the entorhinal cortex. *Nature*, **436**, 801-806.
- Haller, S., Montandon, M.L., Rodriguez, C., Ackermann, M., Herrmann, F.R. & Giannakopoulos, P. (2017) APOE*E4 Is Associated with Gray Matter Loss in the Posterior Cingulate Cortex in Healthy Elderly Controls Subsequently Developing Subtle Cognitive Decline. *AJNR Am J Neuroradiol*, **38**, 1335-1342.
- Hildebrandt, H., Muller, S., Bussmann-Mork, B., Goebel, S. & Eilers, N. (2001) Are some memory deficits unique to lesions of the mammillary bodies? *J Clin Exp Neuropsychol*, **23**, 490-501.
- Hodgetts, C.J., Shine, J.P., Williams, H., Postans, M., Sims, R., Williams, J., Lawrence, A.D. & Graham, K.S. (2019) Increased posterior default mode network activity and structural connectivity in young adult APOE-epsilon4 carriers: a multimodal imaging investigation. *Neurobiol Aging*, **73**, 82-91.
- Hodgetts, C.J., Stefani, M., Williams, A.N., Kolarik, B.S., Yonelinas, A.P., Ekstrom, A.D., Lawrence, A.D., Zhang, J. & Graham, K.S. (2020) The role of the fornix in human navigational learning. *Cortex*, **124**, 97-110.

Honea, R.A., Vidoni, E., Harsha, A. & Burns, J.M. (2009) Impact of APOE on the healthy aging brain: a voxel-based MRI and DTI study. *J Alzheimers Dis*, **18**, 553-564.

Hong, Y.J., Yoon, B., Lim, S.C., Shim, Y.S., Kim, J.Y., Ahn, K.J., Han, I.W. & Yang, D.W. (2013) Microstructural changes in the hippocampus and posterior cingulate in mild cognitive impairment and Alzheimer's disease: a diffusion tensor imaging study. *Neurol Sci*, **34**, 1215-1221.

Hornberger, M., Wong, S., Tan, R., Irish, M., Piguet, O., Kril, J., Hodges, J.R. & Halliday, G. (2012) In vivo and post-mortem memory circuit integrity in frontotemporal dementia and Alzheimer's disease. *Brain*, **135**, 3015-3025.

Hort, J., Laczó, J., Vyhnalek, M., Bojar, M., Bures, J. & Vlcek, K. (2007) Spatial navigation deficit in amnesic mild cognitive impairment. *Proc Natl Acad Sci U S A*, **104**, 4042-4047.

Howett, D., Castegnaro, A., Krzywicka, K., Hagman, J., Marchment, D., Henson, R., Rio, M., King, J.A., Burgess, N. & Chan, D. (2019) Differentiation of mild cognitive impairment using an entorhinal cortex-based test of virtual reality navigation. *Brain*, **142**, 1751-1766.

Im, K., Lee, J.M., Seo, S.W., Yoon, U., Kim, S.T., Kim, Y.H., Kim, S.I. & Na, D.L. (2008) Variations in cortical thickness with dementia severity in Alzheimer's disease. *Neurosci Lett*, **436**, 227-231.

Irish, M., Piguet, O., Hodges, J.R. & Hornberger, M. (2014) Common and unique gray matter correlates of episodic memory dysfunction in frontotemporal dementia and Alzheimer's disease. *Hum Brain Mapp*, **35**, 1422-1435.

Jankowski, M.M., Ronnqvist, K.C., Tsanov, M., Vann, S.D., Wright, N.F., Erichsen, J.T., Aggleton, J.P. & O'Mara, S.M. (2013) The anterior thalamus provides a subcortical circuit supporting memory and spatial navigation. *Front Syst Neurosci*, **7**, 45.

Jin, Z., Sethi, S.K., Li, B., Tang, R., Li, Y., Hsu, C.C., He, N., Haacke, E.M. & Yan, F. (2020) Susceptibility and Volume Measures of the Mammillary Bodies Between Mild Cognitively Impaired Patients and Healthy Controls. *Front Neurosci*, **14**, 572595.

Kantarci, K. (2014) Fractional anisotropy of the fornix and hippocampal atrophy in Alzheimer's disease. *Front Aging Neurosci*, **6**, 316.

Kiuchi, K., Morikawa, M., Taoka, T., Nagashima, T., Yamauchi, T., Makinodan, M., Norimoto, K., Hashimoto, K., Kosaka, J., Inoue, Y., Inoue, M., Kichikawa, K. & Kishimoto, T. (2009) Abnormalities of the uncinate fasciculus and posterior cingulate fasciculus in mild cognitive impairment and early Alzheimer's disease: a diffusion tensor tractography study. *Brain Res*, **1287**, 184-191.

- Klunk, W.E., Price, J.C., Mathis, C.A., Tsopelas, N.D., Lopresti, B.J., Ziolkowski, S.K., Bi, W., Hoge, J.A., Cohen, A.D., Ikonomic, M.D., Saxton, J.A., Snitz, B.E., Pollen, D.A., Moonis, M., Lippa, C.F., Swearer, J.M., Johnson, K.A., Rentz, D.M., Fischman, A.J., Aizenstein, H.J. & DeKosky, S.T. (2007) Amyloid deposition begins in the striatum of presenilin-1 mutation carriers from two unrelated pedigrees. *J Neurosci*, **27**, 6174-6184.
- Knight, W.D., Kim, L.G., Douiri, A., Frost, C., Rossor, M.N. & Fox, N.C. (2011a) Acceleration of cortical thinning in familial Alzheimer's disease. *Neurobiol Aging*, **32**, 1765-1773.
- Knight, W.D., Okello, A.A., Ryan, N.S., Turkheimer, F.E., Rodriguez Martinez de Llano, S., Edison, P., Douglas, J., Fox, N.C., Brooks, D.J. & Rossor, M.N. (2011b) Carbon-11-Pittsburgh compound B positron emission tomography imaging of amyloid deposition in presenilin 1 mutation carriers. *Brain*, **134**, 293-300.
- Kobayashi, S., Tateno, M., Utsumi, K., Takahashi, A., Saitoh, M., Morii, H., Fujii, K. & Teraoka, M. (2008) Quantitative analysis of brain perfusion SPECT in Alzheimer's disease using a fully automated regional cerebral blood flow quantification software, 3DSRT. *J Neurol Sci*, **264**, 27-33.
- Kulason, S., Xu, E., Tward, D.J., Bakker, A., Albert, M., Younes, L. & Miller, M.I. (2020) Entorhinal and Transentorhinal Atrophy in Preclinical Alzheimer's Disease. *Front Neurosci*, **14**, 804.
- La Joie, R., Landeau, B., Perrotin, A., Bejanin, A., Egret, S., Pelerin, A., Mezenge, F., Belliard, S., de La Sayette, V., Eustache, F., Desgranges, B. & Chetelat, G. (2014) Intrinsic connectivity identifies the hippocampus as a main crossroad between Alzheimer's and semantic dementia-targeted networks. *Neuron*, **81**, 1417-1428.
- Laczo, J., Andel, R., Vyhnalek, M., Vlcek, K., Nedelska, Z., Matoska, V., Gazova, I., Mokrisova, I., Sheardova, K. & Hort, J. (2014) APOE and spatial navigation in amnesic MCI: results from a computer-based test. *Neuropsychology*, **28**, 676-684.
- Lee, G.J., Lu, P.H., Medina, L.D., Rodriguez-Agudelo, Y., Melchor, S., Coppola, G., Braskie, M.N., Hua, X., Apostolova, L.G., Leow, A.D., Thompson, P.M. & Ringman, J.M. (2013) Regional brain volume differences in symptomatic and presymptomatic carriers of familial Alzheimer's disease mutations. *J Neurol Neurosurg Psychiatry*, **84**, 154-162.
- Leech, R. & Sharp, D.J. (2014) The role of the posterior cingulate cortex in cognition and disease. *Brain*, **137**, 12-32.
- Levine, T.F., Allison, S.L., Stojanovic, M., Fagan, A.M., Morris, J.C. & Head, D. (2020) Spatial navigation ability predicts progression of dementia symptomatology. *Alzheimers Dement*, **16**, 491-500.
- Li, W., Antuono, P.G., Xie, C., Chen, G., Jones, J.L., Ward, B.D., Singh, S.P., Franczak, M.B., Goveas, J.S. & Li, S.J. (2014) Aberrant functional connectivity in Papez circuit correlates with memory performance in cognitively intact middle-aged APOE4 carriers. *Cortex*, **57**, 167-176.

- Lin, Y.C., Shih, Y.C., Tseng, W.Y., Chu, Y.H., Wu, M.T., Chen, T.F., Tang, P.F. & Chiu, M.J. (2014) Cingulum correlates of cognitive functions in patients with mild cognitive impairment and early Alzheimer's disease: a diffusion spectrum imaging study. *Brain Topogr*, **27**, 393-402.
- Lind, J., Persson, J., Ingvar, M., Larsson, A., Cruts, M., Van Broeckhoven, C., Adolfsson, R., Backman, L., Nilsson, L.G., Petersson, K.M. & Nyberg, L. (2006) Reduced functional brain activity response in cognitively intact apolipoprotein E epsilon4 carriers. *Brain*, **129**, 1240-1248.
- Lindberg, O., Martensson, G., Stomrud, E., Palmqvist, S., Wahlund, L.O., Westman, E. & Hansson, O. (2017) Atrophy of the Posterior Subiculum Is Associated with Memory Impairment, Tau- and Abeta Pathology in Non-demented Individuals. *Front Aging Neurosci*, **9**, 306.
- Llado, A., Tort-Merino, A., Sanchez-Valle, R., Falgas, N., Balasa, M., Bosch, B., Castellvi, M., Olives, J., Antonell, A. & Hornberger, M. (2018) The hippocampal longitudinal axis-relevance for underlying tau and TDP-43 pathology. *Neurobiol Aging*, **70**, 1-9.
- Machulda, M.M., Jones, D.T., Vemuri, P., McDade, E., Avula, R., Przybelski, S., Boeve, B.F., Knopman, D.S., Petersen, R.C. & Jack, C.R., Jr. (2011) Effect of APOE epsilon4 status on intrinsic network connectivity in cognitively normal elderly subjects. *Arch Neurol*, **68**, 1131-1136.
- McKhann, G.M., Knopman, D.S., Chertkow, H., Hyman, B.T., Jack, C.R., Jr., Kawas, C.H., Klunk, W.E., Koroshetz, W.J., Manly, J.J., Mayeux, R., Mohs, R.C., Morris, J.C., Rossor, M.N., Scheltens, P., Carrillo, M.C., Thies, B., Weintraub, S. & Phelps, C.H. (2011) The diagnosis of dementia due to Alzheimer's disease: recommendations from the National Institute on Aging-Alzheimer's Association workgroups on diagnostic guidelines for Alzheimer's disease. *Alzheimers Dement*, **7**, 263-269.
- McNaughton, B.L., Battaglia, F.P., Jensen, O., Moser, E.I. & Moser, M.B. (2006) Path integration and the neural basis of the 'cognitive map'. *Nat Rev Neurosci*, **7**, 663-678.
- Metzler-Baddeley, C., Jones, D.K., Belaroussi, B., Aggleton, J.P. & O'Sullivan, M.J. (2011) Frontotemporal connections in episodic memory and aging: a diffusion MRI tractography study. *J Neurosci*, **31**, 13236-13245.
- Mielke, M.M., Kozauer, N.A., Chan, K.C., George, M., Toroney, J., Zerrate, M., Bandeen-Roche, K., Wang, M.C., Vanzijl, P., Pekar, J.J., Mori, S., Lyketsos, C.G. & Albert, M. (2009) Regionally-specific diffusion tensor imaging in mild cognitive impairment and Alzheimer's disease. *Neuroimage*, **46**, 47-55.
- Mielke, M.M., Okonkwo, O.C., Oishi, K., Mori, S., Tighe, S., Miller, M.I., Ceritoglu, C., Brown, T., Albert, M. & Lyketsos, C.G. (2012) Fornix integrity and hippocampal volume predict memory decline and progression to Alzheimer's disease. *Alzheimers Dement*, **8**, 105-113.

- Minoshima, S., Giordani, B., Berent, S., Frey, K.A., Foster, N.L. & Kuhl, D.E. (1997) Metabolic reduction in the posterior cingulate cortex in very early Alzheimer's disease. *Ann Neurol*, **42**, 85-94.
- Mosconi, L., Sorbi, S., de Leon, M.J., Li, Y., Nacmias, B., Myoung, P.S., Tsui, W., Ginestroni, A., Bessi, V., Fayyazz, M., Caffarra, P. & Pupi, A. (2006) Hypometabolism exceeds atrophy in presymptomatic early-onset familial Alzheimer's disease. *J Nucl Med*, **47**, 1778-1786.
- Mosconi, L., Sorbi, S., Nacmias, B., De Cristofaro, M.T., Fayyaz, M., Cellini, E., Bagnoli, S., Bracco, L., Herholz, K. & Pupi, A. (2003) Brain metabolic differences between sporadic and familial Alzheimer's disease. *Neurology*, **61**, 1138-1140.
- Moscovitch, M., Nadel, L., Winocur, G., Gilboa, A. & Rosenbaum, R.S. (2006) The cognitive neuroscience of remote episodic, semantic and spatial memory. *Curr Opin Neurobiol*, **16**, 179-190.
- Mutlu, J., Landeau, B., Tomadesso, C., de Flores, R., Mezenge, F., de La Sayette, V., Eustache, F. & Chetelat, G. (2016) Connectivity Disruption, Atrophy, and Hypometabolism within Posterior Cingulate Networks in Alzheimer's Disease. *Front Neurosci*, **10**, 582.
- Nakata, Y., Sato, N., Nemoto, K., Abe, O., Shikakura, S., Arima, K., Furuta, N., Uno, M., Hirai, S., Masutani, Y., Ohtomo, K., Barkovich, A.J. & Aoki, S. (2009) Diffusion abnormality in the posterior cingulum and hippocampal volume: correlation with disease progression in Alzheimer's disease. *Magn Reson Imaging*, **27**, 347-354.
- Nestor, P.J., Fryer, T.D. & Hodges, J.R. (2006) Declarative memory impairments in Alzheimer's disease and semantic dementia. *Neuroimage*, **30**, 1010-1020.
- Nestor, P.J., Fryer, T.D., Smielewski, P. & Hodges, J.R. (2003) Limbic hypometabolism in Alzheimer's disease and mild cognitive impairment. *Ann Neurol*, **54**, 343-351.
- Nierenberg, J., Pomara, N., Hoptman, M.J., Sidtis, J.J., Ardekani, B.A. & Lim, K.O. (2005) Abnormal white matter integrity in healthy apolipoprotein E epsilon4 carriers. *Neuroreport*, **16**, 1369-1372.
- Nir, T.M., Jahanshad, N., Villalon-Reina, J.E., Toga, A.W., Jack, C.R., Weiner, M.W., Thompson, P.M. & Alzheimer's Disease Neuroimaging, I. (2013) Effectiveness of regional DTI measures in distinguishing Alzheimer's disease, MCI, and normal aging. *Neuroimage Clin*, **3**, 180-195.
- Novellino, F., Lopez, M.E., Vaccaro, M.G., Miguel, Y., Delgado, M.L. & Maestu, F. (2019) Association Between Hippocampus, Thalamus, and Caudate in Mild Cognitive Impairment APOEepsilon4 Carriers: A Structural Covariance MRI Study. *Front Neurol*, **10**, 1303.

O'Dwyer, L., Lamberton, F., Matura, S., Tanner, C., Scheibe, M., Miller, J., Rujescu, D., Prvulovic, D. & Hampel, H. (2012) Reduced hippocampal volume in healthy young ApoE4 carriers: an MRI study. *PLoS One*, **7**, e48895.

O'Keefe, J. (1976) Place Units in the Hippocampus of the Freely Moving Rat. *Experimental Neurology*, **51**, 78-109.

O'Keefe, J. & Dostrovsky, J. (1971) The hippocampus as a spatial map. Preliminary evidence from unit activity in the freely-moving rat. *Brain Res*, **34**, 171-175.

O'Mara, S.M., Sanchez-Vives, M.V., Brotons-Mas, J.R. & O'Hare, E. (2009) Roles for the subiculum in spatial information processing, memory, motivation and the temporal control of behaviour. *Prog Neuropsychopharmacol Biol Psychiatry*, **33**, 782-790.

Ossenkoppele, R., Cohn-Sheehy, B.I., La Joie, R., Vogel, J.W., Moller, C., Lehmann, M., van Berckel, B.N., Seeley, W.W., Pijnenburg, Y.A., Gorno-Tempini, M.L., Kramer, J.H., Barkhof, F., Rosen, H.J., van der Flier, W.M., Jagust, W.J., Miller, B.L., Scheltens, P. & Rabinovici, G.D. (2015a) Atrophy patterns in early clinical stages across distinct phenotypes of Alzheimer's disease. *Hum Brain Mapp*, **36**, 4421-4437.

Ossenkoppele, R., Pijnenburg, Y.A., Perry, D.C., Cohn-Sheehy, B.I., Scheltens, N.M., Vogel, J.W., Kramer, J.H., van der Vlies, A.E., La Joie, R., Rosen, H.J., van der Flier, W.M., Grinberg, L.T., Rozemuller, A.J., Huang, E.J., van Berckel, B.N., Miller, B.L., Barkhof, F., Jagust, W.J., Scheltens, P., Seeley, W.W. & Rabinovici, G.D. (2015b) The behavioural/dysexecutive variant of Alzheimer's disease: clinical, neuroimaging and pathological features. *Brain*, **138**, 2732-2749.

Papez, J.W. (1937) A proposed mechanism of emotion. *Archives of Neurology and Psychiatry*, **38**, 725-743.

Papma, J.M., Smits, M., de Groot, M., Mattace Raso, F.U., van der Lugt, A., Vrooman, H.A., Niessen, W.J., Koudstaal, P.J., van Swieten, J.C., van der Veen, F.M. & Prins, N.D. (2017) The effect of hippocampal function, volume and connectivity on posterior cingulate cortex functioning during episodic memory fMRI in mild cognitive impairment. *Eur Radiol*, **27**, 3716-3724.

Pardilla-Delgado, E., Torrico-Teave, H., Sanchez, J.S., Ramirez-Gomez, L.A., Baena, A., Bocanegra, Y., Vila-Casteler, C., Fox-Fuller, J.T., Guzmán-Veléz, E., Martínez, J., Alvarez, S., Ochoa-Escudero, M., Lopera, F. & Quiroz, Y.T. (2021) Associations between subregional thalamic volume and brain pathology in autosomal dominant Alzheimer's disease. *Brain*, 1:10.

Patel, K.T., Stevens, M.C., Pearlson, G.D., Winkler, A.M., Hawkins, K.A., Skudlarski, P. & Bauer, L.O. (2013) Default mode network activity and white matter integrity in healthy middle-aged ApoE4 carriers. *Brain Imaging Behav*, **7**, 60-67.

Phillips, J.S., Da Re, F., Dratch, L., Xie, S.X., Irwin, D.J., McMillan, C.T., Vaishnavi, S.N., Ferrarese, C., Lee, E.B., Shaw, L.M., Trojanowski, J.Q., Wolk, D.A. & Grossman, M. (2018) Neocortical origin

and progression of gray matter atrophy in nonamnesic Alzheimer's disease. *Neurobiol Aging*, **63**, 75-87.

Powell, H.W., Guye, M., Parker, G.J., Symms, M.R., Boulby, P., Koepp, M.J., Barker, G.J. & Duncan, J.S. (2004) Noninvasive in vivo demonstration of the connections of the human parahippocampal gyrus. *Neuroimage*, **22**, 740-747.

Quan, M., Zhao, T., Tang, Y., Luo, P., Wang, W., Qin, Q., Li, T., Wang, Q., Fang, J. & Jia, J. (2020) Effects of gene mutation and disease progression on representative neural circuits in familial Alzheimer's disease. *Alzheimers Res Ther*, **12**, 14.

Quiroz, Y.T., Budson, A.E., Celone, K., Ruiz, A., Newmark, R., Castrillon, G., Lopera, F. & Stern, C.E. (2010) Hippocampal hyperactivation in presymptomatic familial Alzheimer's disease. *Ann Neurol*, **68**, 865-875.

Quiroz, Y.T., Sperling, R.A., Norton, D.J., Baena, A., Arboleda-Velasquez, J.F., Cosio, D., Schultz, A., Lapoint, M., Guzman-Velez, E., Miller, J.B., Kim, L.A., Chen, K., Tariot, P.N., Lopera, F., Reiman, E.M. & Johnson, K.A. (2018) Association Between Amyloid and Tau Accumulation in Young Adults With Autosomal Dominant Alzheimer Disease. *JAMA Neurol*, **75**, 548-556.

Rabipour, S., Rajagopal, S., Yu, E., Pasvanis, S., Lafaille-Magnan, M.E., Breitner, J., Group, P.-A.R. & Rajah, M.N. (2020) APOE4 Status is Related to Differences in Memory-Related Brain Function in Asymptomatic Older Adults with Family History of Alzheimer's Disease: Baseline Analysis of the PREVENT-AD Task Functional MRI Dataset. *J Alzheimers Dis*, **76**, 97-119.

Rajah, M.N., Wallace, L.M.K., Ankudowich, E., Yu, E.H., Swierkot, A., Patel, R., Chakravarty, M.M., Naumova, D., Pruessner, J., Joobar, R., Gauthier, S. & Pasvanis, S. (2017) Family history and APOE4 risk for Alzheimer's disease impact the neural correlates of episodic memory by early midlife. *Neuroimage Clin*, **14**, 760-774.

Reiman, E.M., Caselli, R.J., Yun, L.S., Chen, K., Bandy, D., Minoshima, S., Thibodeau, S.N. & Osborne, D. (1996) Preclinical evidence of Alzheimer's disease in persons homozygous for the epsilon 4 allele for apolipoprotein E. *N Engl J Med*, **334**, 752-758.

Reiman, E.M., Chen, K., Alexander, G.E., Caselli, R.J., Bandy, D., Osborne, D., Saunders, A.M. & Hardy, J. (2004) Functional brain abnormalities in young adults at genetic risk for late-onset Alzheimer's dementia. *Proc Natl Acad Sci U S A*, **101**, 284-289.

Ridha, B.H., Barnes, J., Bartlett, J.W., Godbolt, A., Pepple, T., Rossor, M.N. & Fox, N.C. (2006) Tracking atrophy progression in familial Alzheimer's disease: a serial MRI study. *Lancet Neurol*, **5**, 828-834.

Ringman, J.M., O'Neill, J., Geschwind, D., Medina, L., Apostolova, L.G., Rodriguez, Y., Schaffer, B., Varpetian, A., Tseng, B., Ortiz, F., Fitten, J., Cummings, J.L. & Bartzokis, G. (2007) Diffusion tensor imaging in preclinical and presymptomatic carriers of familial Alzheimer's disease mutations. *Brain*, **130**, 1767-1776.

- Ritchie, K., Carriere, I., Howett, D., Su, L., Hornberger, M., O'Brien, J.T., Ritchie, C.W. & Chan, D. (2018) Allocentric and Egocentric Spatial Processing in Middle-Aged Adults at High Risk of Late-Onset Alzheimer's Disease: The PREVENT Dementia Study. *J Alzheimers Dis*, **65**, 885-896.
- Rolls, E.T. (2019) The cingulate cortex and limbic systems for emotion, action, and memory. *Brain Struct Funct*, **224**, 3001-3018.
- Rose, S.E., Janke, A.L. & Chalk, J.B. (2008) Gray and white matter changes in Alzheimer's disease: a diffusion tensor imaging study. *J Magn Reson Imaging*, **27**, 20-26.
- Rose, S.E., McMahon, K.L., Janke, A.L., O'Dowd, B., de Zubicaray, G., Strudwick, M.W. & Chalk, J.B. (2006) Diffusion indices on magnetic resonance imaging and neuropsychological performance in amnesic mild cognitive impairment. *J Neurol Neurosurg Psychiatry*, **77**, 1122-1128.
- Rudebeck, S.R., Scholz, J., Millington, R., Rohenkohl, G., Johansen-Berg, H. & Lee, A.C. (2009) Fornix microstructure correlates with recollection but not familiarity memory. *J Neurosci*, **29**, 14987-14992.
- Ryan, N.S., Keihaninejad, S., Shakespeare, T.J., Lehmann, M., Crutch, S.J., Malone, I.B., Thornton, J.S., Mancini, L., Hyare, H., Yousry, T., Ridgway, G.R., Zhang, H., Modat, M., Alexander, D.C., Rossor, M.N., Ourselin, S. & Fox, N.C. (2013) Magnetic resonance imaging evidence for presymptomatic change in thalamus and caudate in familial Alzheimer's disease. *Brain*, **136**, 1399-1414.
- Sala-Llonch, R., Llado, A., Fortea, J., Bosch, B., Antonell, A., Balasa, M., Bargallo, N., Bartres-Faz, D., Molinuevo, J.L. & Sanchez-Valle, R. (2015) Evolving brain structural changes in PSEN1 mutation carriers. *Neurobiol Aging*, **36**, 1261-1270.
- Salmon, E., Kerrouche, N., Perani, D., Lekeu, F., Holthoff, V., Beuthien-Baumann, B., Sorbi, S., Lemaire, C., Collette, F. & Herholz, K. (2009) On the multivariate nature of brain metabolic impairment in Alzheimer's disease. *Neurobiol Aging*, **30**, 186-197.
- Sanchez-Valle, R., Monte, G.C., Sala-Llonch, R., Bosch, B., Fortea, J., Llado, A., Antonell, A., Balasa, M., Bargallo, N. & Molinuevo, J.L. (2016) White Matter Abnormalities Track Disease Progression in PSEN1 Autosomal Dominant Alzheimer's Disease. *J Alzheimers Dis*, **51**, 827-835.
- Sarazin, M., Berr, C., De Rotrou, J., Fabrigoule, C., Pasquier, F., Legrain, S., Michel, B., Puel, M., Volteau, M., Touchon, J., Verny, M. & Dubois, B. (2007) Amnesic syndrome of the medial temporal type identifies prodromal AD: a longitudinal study. *Neurology*, **69**, 1859-1867.
- Schoberl, F., Pradhan, C., Irving, S., Buerger, K., Xiong, G., Kugler, G., Kohlbecher, S., Engmann, J., Werner, P., Brendel, M., Schneider, E., Pernecky, R., Jahn, K., la Fougere, C., Bartenstein, P.,

- Brandt, T., Dieterich, M. & Zwergal, A. (2020) Real-space navigation testing differentiates between amyloid-positive and -negative aMCI. *Neurology*, **94**, e861-e873.
- Schroeter, M.L., Stein, T., Maslowski, N. & Neumann, J. (2009) Neural correlates of Alzheimer's disease and mild cognitive impairment: a systematic and quantitative meta-analysis involving 1351 patients. *Neuroimage*, **47**, 1196-1206.
- Sexton, C.E., Mackay, C.E., Lonie, J.A., Bastin, M.E., Terriere, E., O'Carroll, R.E. & Ebmeier, K.P. (2010) MRI correlates of episodic memory in Alzheimer's disease, mild cognitive impairment, and healthy aging. *Psychiatry Res*, **184**, 57-62.
- Shah, A., Jhavar, S.S. & Goel, A. (2012) Analysis of the anatomy of the Papez circuit and adjoining limbic system by fiber dissection techniques. *J Clin Neurosci*, **19**, 289-298.
- Sheline, Y.I., Morris, J.C., Snyder, A.Z., Price, J.L., Yan, Z., D'Angelo, G., Liu, C., Dixit, S., Benzinger, T., Fagan, A., Goate, A. & Mintun, M.A. (2010) APOE4 allele disrupts resting state fMRI connectivity in the absence of amyloid plaques or decreased CSF Abeta42. *J Neurosci*, **30**, 17035-17040.
- Small, G.W., Ercoli, L.M., Silverman, D.H., Huang, S.C., Komo, S., Bookheimer, S.Y., Lavretsky, H., Miller, K., Siddarth, P., Rasgon, N.L., Mazziotta, J.C., Saxena, S., Wu, H.M., Mega, M.S., Cummings, J.L., Saunders, A.M., Pericak-Vance, M.A., Roses, A.D., Barrio, J.R. & Phelps, M.E. (2000) Cerebral metabolic and cognitive decline in persons at genetic risk for Alzheimer's disease. *Proc Natl Acad Sci U S A*, **97**, 6037-6042.
- Small, S.A., Schobel, S.A., Buxton, R.B., Witter, M.P. & Barnes, C.A. (2011) A pathophysiological framework of hippocampal dysfunction in ageing and disease. *Nat Rev Neurosci*, **12**, 585-601.
- Stricker, N.H., Schweinsburg, B.C., Delano-Wood, L., Wierenga, C.E., Bangen, K.J., Haaland, K.Y., Frank, L.R., Salmon, D.P. & Bondi, M.W. (2009) Decreased white matter integrity in late-myelinating fiber pathways in Alzheimer's disease supports retrogenesis. *Neuroimage*, **45**, 10-16.
- Suthana, N.A., Ekstrom, A.D., Moshirvaziri, S., Knowlton, B. & Bookheimer, S.Y. (2009) Human hippocampal CA1 involvement during allocentric encoding of spatial information. *J Neurosci*, **29**, 10512-10519.
- Tan, R.H., Wong, S., Kril, J.J., Piguet, O., Hornberger, M., Hodges, J.R. & Halliday, G.M. (2014) Beyond the temporal pole: limbic memory circuit in the semantic variant of primary progressive aphasia. *Brain*, **137**, 2065-2076.
- Tanaka, Y., Miyazawa, Y., Akaoka, F. & Yamada, T. (1997) Amnesia following damage to the mammillary bodies. *Neurology*, **48**, 160-165.

Tentolouris-Piperas, V., Ryan, N.S., Thomas, D.L. & Kinnunen, K.M. (2017) Brain imaging evidence of early involvement of subcortical regions in familial and sporadic Alzheimer's disease. *Brain Res*, **1655**, 23-32.

Thal, D.R., Rub, U., Orantes, M. & Braak, H. (2002) Phases of A beta-deposition in the human brain and its relevance for the development of AD. *Neurology*, **58**, 1791-1800.

Thomas, A.G., Koumellis, P. & Dineen, R.A. (2011) The fornix in health and disease: an imaging review. *Radiographics*, **31**, 1107-1121.

Thomas, B.P., Welch, E.B., Niederhauser, B.D., Whetsell, W.O., Jr., Anderson, A.W., Gore, J.C., Avison, M.J. & Creasy, J.L. (2008) High-resolution 7T MRI of the human hippocampus in vivo. *J Magn Reson Imaging*, **28**, 1266-1272.

Thordardottir, S., Stahlbom, A.K., Ferreira, D., Almkvist, O., Westman, E., Zetterberg, H., Eriksdotter, M., Blennow, K. & Graff, C. (2015) Preclinical cerebrospinal fluid and volumetric magnetic resonance imaging biomarkers in Swedish familial Alzheimer's disease. *J Alzheimers Dis*, **43**, 1393-1402.

Tu, S., Spiers, H.J., Hodges, J.R., Piguet, O. & Hornberger, M. (2017) Egocentric versus Allocentric Spatial Memory in Behavioral Variant Frontotemporal Dementia and Alzheimer's Disease. *J Alzheimers Dis*, **59**, 883-892.

Tu, S., Wong, S., Hodges, J.R., Irish, M., Piguet, O. & Hornberger, M. (2015) Lost in spatial translation - A novel tool to objectively assess spatial disorientation in Alzheimer's disease and frontotemporal dementia. *Cortex*, **67**, 83-94.

Van der Werf, Y.D., Witter, M.P., Uylings, H.B. & Jolles, J. (2000) Neuropsychology of infarctions in the thalamus: a review. *Neuropsychologia*, **38**, 613-627.

Van Hoesen, G.W., Augustinack, J.C., Dierking, J., Redman, S.J. & Thangavel, R. (2000) The parahippocampal gyrus in Alzheimer's disease. Clinical and preclinical neuroanatomical correlates. *Ann N Y Acad Sci*, **911**, 254-274.

van Strien, N.M., Cappaert, N.L. & Witter, M.P. (2009) The anatomy of memory: an interactive overview of the parahippocampal-hippocampal network. *Nat Rev Neurosci*, **10**, 272-282.

Vann, S.D. (2010) Re-evaluating the role of the mammillary bodies in memory. *Neuropsychologia*, **48**, 2316-2327.

Vann, S.D. & Aggleton, J.P. (2003) Evidence of a spatial encoding deficit in rats with lesions of the mammillary bodies or mammillothalamic tract. *J Neurosci*, **23**, 3506-3514.

- Vann, S.D. & Aggleton, J.P. (2004) The mammillary bodies: two memory systems in one? *Nat Rev Neurosci*, **5**, 35-44.
- Vann, S.D., Erichsen, J.T., O'Mara, S.M. & Aggleton, J.P. (2011) Selective disconnection of the hippocampal formation projections to the mammillary bodies produces only mild deficits on spatial memory tasks: implications for fornix function. *Hippocampus*, **21**, 945-957.
- Vann, S.D. & Nelson, A.J. (2015) The mammillary bodies and memory: more than a hippocampal relay. *Prog Brain Res*, **219**, 163-185.
- Villain, N., Desgranges, B., Viader, F., de la Sayette, V., Mezenge, F., Landeau, B., Baron, J.C., Eustache, F. & Chetelat, G. (2008) Relationships between hippocampal atrophy, white matter disruption, and gray matter hypometabolism in Alzheimer's disease. *J Neurosci*, **28**, 6174-6181.
- Villain, N., Fouquet, M., Baron, J.C., Mezenge, F., Landeau, B., de La Sayette, V., Viader, F., Eustache, F., Desgranges, B. & Chetelat, G. (2010) Sequential relationships between grey matter and white matter atrophy and brain metabolic abnormalities in early Alzheimer's disease. *Brain*, **133**, 3301-3314.
- Vogt, B.A. (2009) *Cingulate Neurobiology and Disease*. Oxford University Press Inc., New York.
- Wang, L., Goldstein, F.C., Veledar, E., Levey, A.I., Lah, J.J., Meltzer, C.C., Holder, C.A. & Mao, H. (2009) Alterations in cortical thickness and white matter integrity in mild cognitive impairment measured by whole-brain cortical thickness mapping and diffusion tensor imaging. *AJNR Am J Neuroradiol*, **30**, 893-899.
- Wang, P., Zhou, B., Yao, H., Xie, S., Feng, F., Zhang, Z., Guo, Y., An, N., Zhou, Y., Zhang, X. & Liu, Y. (2020) Aberrant Hippocampal Functional Connectivity Is Associated with Fornix White Matter Integrity in Alzheimer's Disease and Mild Cognitive Impairment. *J Alzheimers Dis*, **75**, 1153-1168.
- Westlye, E.T., Lundervold, A., Rootwelt, H., Lundervold, A.J. & Westlye, L.T. (2011) Increased hippocampal default mode synchronization during rest in middle-aged and elderly APOE epsilon4 carriers: relationships with memory performance. *J Neurosci*, **31**, 7775-7783.
- Weston, P.S., Nicholas, J.M., Lehmann, M., Ryan, N.S., Liang, Y., Macpherson, K., Modat, M., Rossor, M.N., Schott, J.M., Ourselin, S. & Fox, N.C. (2016) Presymptomatic cortical thinning in familial Alzheimer disease: A longitudinal MRI study. *Neurology*, **87**, 2050-2057.
- Whitwell, J.L., Jack, C.R., Jr., Boeve, B.F., Parisi, J.E., Ahlskog, J.E., Drubach, D.A., Senjem, M.L., Knopman, D.S., Petersen, R.C., Dickson, D.W. & Josephs, K.A. (2010) Imaging correlates of pathology in corticobasal syndrome. *Neurology*, **75**, 1879-1887.

WHO (2017) Global action plan on the public health response to dementia 2017–2025. *Geneva: World Health Organization.*

Wishart, H.A., Saykin, A.J., McAllister, T.W., Rabin, L.A., McDonald, B.C., Flashman, L.A., Roth, R.M., Mamourian, A.C., Tsongalis, G.J. & Rhodes, C.H. (2006) Regional brain atrophy in cognitively intact adults with a single APOE epsilon4 allele. *Neurology*, **67**, 1221-1224.

Yoneoka, Y., Takeda, N., Inoue, A., Ibuchi, Y., Kumagai, T., Sugai, T., Takeda, K. & Ueda, K. (2004) Acute Korsakoff syndrome following mammillothalamic tract infarction. *AJNR Am J Neuroradiol*, **25**, 964-968.

Zarei, M., Patenaude, B., Damoiseaux, J., Morgese, C., Smith, S., Matthews, P.M., Barkhof, F., Rombouts, S.A., Sanz-Arigita, E. & Jenkinson, M. (2010) Combining shape and connectivity analysis: an MRI study of thalamic degeneration in Alzheimer's disease. *Neuroimage*, **49**, 1-8.

Zeidman, P. & Maguire, E.A. (2016) Anterior hippocampus: the anatomy of perception, imagination and episodic memory. *Nat Rev Neurosci*, **17**, 173-182.

Zhang, S., Chen, Y., Liu, Z., Zhang, J., Li, X., Cui, R. & Zhang, Z. (2015) Association of White Matter Integrity and Cognitive Functions in Chinese Non-Demented Elderly with the APOE varepsilon4 Allele. *J Alzheimers Dis*, **48**, 781-791.

Zhang, Y., Schuff, N., Jahng, G.H., Bayne, W., Mori, S., Schad, L., Mueller, S., Du, A.T., Kramer, J.H., Yaffe, K., Chui, H., Jagust, W.J., Miller, B.L. & Weiner, M.W. (2007) Diffusion tensor imaging of cingulum fibers in mild cognitive impairment and Alzheimer disease. *Neurology*, **68**, 13-19.

Zheng, L.J., Su, Y.Y., Wang, Y.F., Schoepf, U.J., Varga-Szemes, A., Pannell, J., Liang, X., Zheng, G., Lu, G.M., Yang, G.F. & Zhang, L.J. (2018) Different Hippocampus Functional Connectivity Patterns in Healthy Young Adults with Mutations of APP/Presenilin-1/2 and APOEepsilon4. *Mol Neurobiol*, **55**, 3439-3450.

Zhou, B., Liu, Y., Zhang, Z., An, N., Yao, H., Wang, P., Wang, L., Zhang, X. & Jiang, T. (2013) Impaired functional connectivity of the thalamus in Alzheimer's disease and mild cognitive impairment: a resting-state fMRI study. *Curr Alzheimer Res*, **10**, 754-766.

Zhou, Y., Dougherty, J.H., Jr., Hubner, K.F., Bai, B., Cannon, R.L. & Hutson, R.K. (2008) Abnormal connectivity in the posterior cingulate and hippocampus in early Alzheimer's disease and mild cognitive impairment. *Alzheimers Dement*, **4**, 265-270.

	Genetically at risk (Healthy APOE4 carriers)	PMC	MCI	SMC	sAD
Hippocampus	↓	↓	↓	↓	↓
Fornix	↓	↓	↓	↓	↓
MB	—	—	~	—	~
MTT	—	—	—	—	—
ATN	↓	↓	↓	↓	↓
Cingulum Bundle	↓	↓	↓	↓	↓
PCC	↓	↓	↓	↓	↓
aPHC	↓	~	↓	~	↓

Table 1

Evidence showing structural impairment of Papez circuit structures along different stages of Alzheimer's disease.

PMC: Presymptomatic mutation carriers; MCI: Mild Cognitive Impairment; SMC: Symptomatic mutation carriers; sAD: sporadic Alzheimer's disease.

MB: Mammillary bodies; MTT: Mammillothalamic tract; ATN: Anterior thalamic nucleus; PCC: Posterior cingulate cortex; aPHC: anterior Parahippocampal cortex; — : Indicates no findings; ~ : Indicates conflicting results.

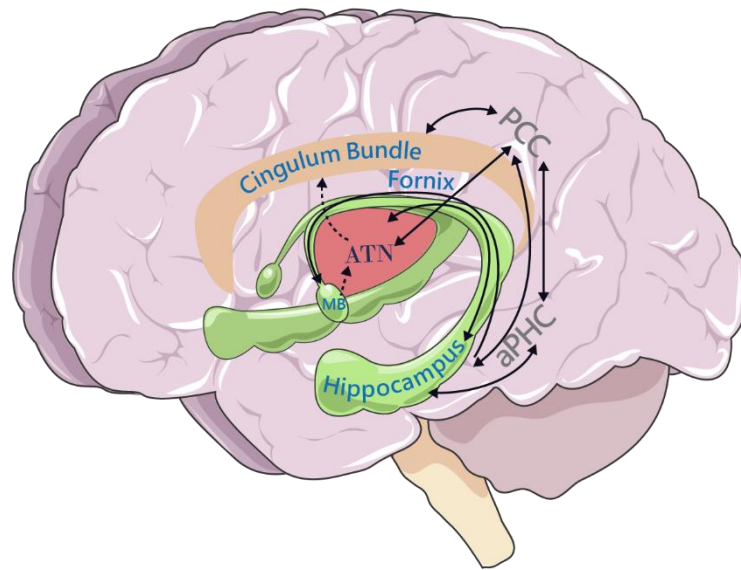


Figure 1

Diagrammatic representation of the Papez Circuit and its divisions. Solid black arrows represent reciprocal connections and dashed arrows shows connections that are solely afferent. MB: mammillary bodies; ATN: anterior thalamic nuclei; PCC: posterior cingulate cortex; aPHC: anterior parahippocampal cortex.

Graphical Abstract

This review strengthens the need for future investigations to move away from a hippocampal-centric view, considering an extended network involved in the pathophysiology and clinical symptomatology of Alzheimer's disease, the Papez circuit.

Graphical Abstract Figure

