














RESEARCH ARTICLE

REVISED **Feasibility and validation of trans-valvular flow derived by four-dimensional flow cardiovascular magnetic resonance imaging in patients with atrial fibrillation [version 2; peer review: 2 approved]**

Mark T Mills ¹, Ciaran Grafton-Clarke ², Gareth Williams ¹, Rebecca C Gosling¹, Abdulaziz Al Baraikan ¹, Andreas L Kyriacou¹, Paul D Morris ¹, Julian P Gunn ¹, Peter P Swoboda ³, Eylem Levelt³, Vasiliki Tsampasian ², Rob J van der Geest⁴, Andrew J Swift¹, John P Greenwood ³, Sven Plein³, Vass Vassiliou ², Pankaj Garg ^{1,2}

¹Department of Infection, Immunity & Cardiovascular Disease, University of Sheffield, Sheffield, UK

²Norwich Medical School, University of East Anglia, Norwich, UK

³Leeds Institute of Cardiovascular and Metabolic Medicine, University of Leeds, Leeds, UK

⁴Department of Radiology, Leiden University Medical Center, Leiden, The Netherlands

v2 **First published:** 31 Mar 2021, 6:73
<https://doi.org/10.12688/wellcomeopenres.16655.1>
Latest published: 18 May 2021, 6:73
<https://doi.org/10.12688/wellcomeopenres.16655.2>

Abstract







Background: Four-dimensional (4D) flow cardiovascular magnetic resonance imaging (MRI) is an emerging technique used for intra-cardiac blood flow assessment. The role of 4D flow cardiovascular MRI in the assessment of trans-valvular flow in patients with atrial fibrillation (AF) has not previously been assessed. The purpose of this study was to assess the feasibility, image quality, and internal validity of 4D flow cardiovascular MRI in the quantification of trans-valvular flow in patients with AF.


Methods: Patients with AF and healthy controls in sinus rhythm underwent cardiovascular MRI, including 4D flow studies. Quality assurance checks were done on the raw data and streamlines. Consistency was investigated by trans-valvular flow assessment between the mitral valve (MV) and the aortic valve (AV).

Results: Eight patients with AF (88% male, mean age 62±13 years, mean heart rate (HR) 83±16 beats per minute (bpm)) were included and compared with ten healthy controls (70% male, mean age 41±20 years, mean HR 68.5±9 bpm). All scans were of either good quality with minimal blurring artefacts, or excellent quality with no artefacts. No significant bias was observed between the AV and MV stroke volumes in either healthy controls (-4.8, 95% CI -15.64 to 6.04; P=0.34)

Open Peer Review**Reviewer Status**  

Invited Reviewers

	1	2
version 2		
(revision)		
18 May 2021	report	report
		
version 1		
31 Mar 2021		
	report	report

1. **Jordi Broncano** , Hospital de la Cruz Roja and San Juan de Dios, Cordoba, Spain

2. **Victoria M. Stoll**, University of Birmingham, Birmingham, UK

Any reports and responses or comments on the article can be found at the end of the article.

or in patients with AF (1.64, 95% CI -4.7 to 7.94; P=0.56). A significant correlation was demonstrated between MV and AV stroke volumes in both healthy controls ($r=0.87$, 95% CI 0.52 to 0.97; P=0.001) and in AF patients ($r=0.82$, 95% CI 0.26 to 0.97; P=0.01).

Conclusions: In patients with AF, 4D flow cardiovascular MRI is feasible with good image quality, allowing for quantification of trans-valvular flow.

Keywords

4D flow CMR, Haemodynamics, Flow quantification, Validation, Atrial fibrillation

Corresponding author: Pankaj Garg (P.Garg@uea.ac.uk)

Author roles: **Mills MT:** Conceptualization, Data Curation, Project Administration, Writing – Original Draft Preparation, Writing – Review & Editing; **Grafton-Clarke C:** Conceptualization, Writing – Review & Editing; **Williams G:** Conceptualization, Writing – Review & Editing; **Gosling RC:** Conceptualization, Writing – Review & Editing; **Al Baraikhan A:** Conceptualization, Writing – Review & Editing; **Kyriacou AL:** Conceptualization, Writing – Review & Editing; **Morris PD:** Data Curation, Writing – Original Draft Preparation, Writing – Review & Editing; **Gunn JP:** Data Curation, Writing – Original Draft Preparation, Writing – Review & Editing; **Swoboda PP:** Formal Analysis, Investigation, Methodology, Writing – Review & Editing; **Levelt E:** Formal Analysis, Investigation, Methodology, Writing – Review & Editing; **Tsampasian V:** Methodology, Writing – Review & Editing; **van der Geest RJ:** Conceptualization, Methodology, Resources, Software, Writing – Review & Editing; **Swift AJ:** Data Curation, Writing – Original Draft Preparation, Writing – Review & Editing; **Greenwood JP:** Formal Analysis, Investigation, Methodology, Writing – Review & Editing; **Plein S:** Formal Analysis, Investigation, Methodology, Writing – Review & Editing; **Vassiliou V:** Methodology, Writing – Review & Editing; **Garg P:** Conceptualization, Data Curation, Formal Analysis, Investigation, Methodology, Project Administration, Resources, Supervision, Validation, Visualization, Writing – Original Draft Preparation, Writing – Review & Editing

Competing interests: P.G. reports clinical advisor role to Medis Medical Imaging and Pie Medical Imaging.

Grant information: PG and PDM are funded by Wellcome Trust Clinical Research Career Development Fellowships (220703/Z/20/Z & 214567/Z/18/Z). For the purpose of Open Access, these authors have applied a CC BY public copyright licence to any Author Accepted Manuscript version arising from this submission.

The funders had no role in study design, data collection and analysis, decision to publish, or preparation of the manuscript.

Copyright: © 2021 Mills MT *et al.* This is an open access article distributed under the terms of the [Creative Commons Attribution License](https://creativecommons.org/licenses/by/4.0/), which permits unrestricted use, distribution, and reproduction in any medium, provided the original work is properly cited.

How to cite this article: Mills MT, Grafton-Clarke C, Williams G *et al.* **Feasibility and validation of trans-valvular flow derived by four-dimensional flow cardiovascular magnetic resonance imaging in patients with atrial fibrillation [version 2; peer review: 2 approved]** Wellcome Open Research 2021, 6:73 <https://doi.org/10.12688/wellcomeopenres.16655.2>

First published: 31 Mar 2021, 6:73 <https://doi.org/10.12688/wellcomeopenres.16655.1>

REVISED Amendments from Version 1

In this revised version, we address the reviewers' feedback and comments. This includes minor changes to [Figure 1](#), [Figure 2](#) and [Figure 3](#), and the addition of a limitation in the limitations section.

Any further responses from the reviewers can be found at the end of the article

Introduction

Atrial fibrillation (AF) is the most common sustained cardiac rhythm disturbance in adults¹. Recent data suggest the prevalence of AF is between 2% and 4% worldwide¹, with this figure expected to rise^{2,3}. Whilst AF can occur in individuals without other cardiovascular comorbidities, it is frequently associated with cardiac disease, including heart failure (with reduced and preserved ejection fraction), valvular disease, and ischaemic heart disease. Cardiovascular magnetic resonance imaging (MRI) is assuming a prominent role in the management of patients with AF, both in the assessment of atrial substrate in the pre-ablation setting⁴ and in those with associated cardiovascular conditions with concomitant AF⁵.

Four-dimensional flow (4D flow) cardiovascular MRI is an emerging technique used for intra-cardiac blood flow assessment in the research and clinical setting. Previous studies have demonstrated accurate and reliable assessment of valvular flow and regurgitation quantification using retrospective valve tracking methods^{6,7}. Furthermore, 4D flow-derived valvular flow assessment circumvents issues with Doppler-based echocardiography measurements and two-dimensional phase-contrast (PC) acquisition cardiovascular MRI⁸. As with most cardiovascular MRI techniques, 4D flow traditionally requires cardiac gating using electrocardiography (ECG) in order to depict the various cardiac structures and movements. Cardiac rhythms with high R-R interval variability such as AF can result in significant image quality degradation and challenging image analyses. As a result, the feasibility, precision, and reliability of valvular flow quantification in patients with AF have not previously been assessed.

We hypothesised that 4D flow cardiovascular MRI is feasible in patients with AF and can accurately and consistently quantify valvular flow. The aims of this study were to (i) assess the feasibility of acquiring 4D flow MRI in patients with AF and (ii) investigate the consistency and reliability of retrospective valve tracking in the quantification of aortic and mitral valvular flow, comparing patients with AF, against healthy controls.

Methods**Ethical considerations**

The study protocol was approved by the National Research Ethics Service (12/YH/0169) in the UK. The study was approved by the local ethics committee and complied with the

Declaration of Helsinki. All patients gave written informed consent immediately prior to MRI examinations.

Study design and population

This was an observational cross-sectional study. In order to assess for internal validity, a healthy cohort was used as a comparator. For the study group, we recruited eight patients with persistent AF from the cardiology department at Leeds Teaching Hospitals NHS Trust. Patients were approached during either hospital admission or outpatient clinic review. Inclusion criteria included patients over the age of 18 years old with AF and a stable heart rate between 70 to 110 beats per minute; the only exclusion criterion was contraindication to MRI. For the healthy control group, another cohort of volunteers in normal sinus rhythm with no previous cardiovascular disorders were recruited. Controls were approached through an appeal for healthy volunteers via the University of Leeds and were not matched to AF cases. As the purpose of the study was to determine feasibility of 4D flow cardiovascular MRI in AF, power calculations were not performed to determine sample size.

Cardiovascular MRI. All patients underwent cardiovascular MRI on a 1.5 Tesla system (Ingenia, Philips, Best, The Netherlands), with a 28-channel flexible torso coil, with digitisation of the MR signal in the receiver coil, at the University of Leeds between January 2014 and December 2017. As previously described^{9,10}, the cardiovascular MRI protocol included baseline survey, cine imaging (vertical long axis, horizontal long axis, short-axis contiguous left-ventricle volume stack) acquired using balanced steady-state free precession in a single slice breath-hold sequence, and whole heart 4D flow acquired using a fast field echo pulse sequence (echo-planar imaging [EPI] based with sensitivity encoding [SENSE] acceleration) with retrospective ECG triggering. Typical 4D image parameters were as follows: EPI acceleration factor of 5 and SENSE factor of 2, flip angle 10°, velocity encoding 150 cm/s, field of view 400 mm, echo time 3.5 ms, repetition time 10 ms, 90% partial k-space coverage in phase-encoding directions, number of signal averages 1; images were acquired during free breathing; the number of slices was 35–40, with a temporal resolution of 40 ms; the reconstructed number of phases was 30¹⁰.

Image analysis. Image analysis was performed offline using MASS software (Version 2018EXP, Leiden University Medical Centre, Leiden, The Netherlands). Similar types of analysis can be carried out by open source software packages like [FourFlow](#). All images were analysed by an imaging cardiologist (PG) with more than five years' experience working with 4D flow cardiovascular MRI. Left ventricular volumes and ejection fraction were calculated from cine images using standard methods¹¹: endocardial and epicardial contours were traced on the left ventricular and right ventricular cine stack at end-systole and end-diastole to determine end systolic volume, end diastolic volume, stroke volume, ejection fraction and left ventricular mass. Volumes were indexed to body surface area. For each 4D flow data set, a visual quality assessment on the

phase contrast and magnitude images was performed to determine image quality and presence of artefact, and scored on a 4-point scale^{9,10}: 0, excellent quality without artefacts; 1, good quality with mild blurring artefacts; 2, moderate quality with moderate blurring artefacts; 3, poor quality with severe artefacts leading to non-evaluable data.

Flow and velocity measurement. Contour segmentation was performed manually. 4D flow assessments were performed using validated techniques including retrospective valve tracking, with measurement planes located perpendicular to the inflow direction on two- and four-chamber cines^{10,12} (Figure 1). Background velocity corrections were performed from the velocity sampled in the myocardium and phase unwrapping was undertaken on source images if aliasing occurred within in the area of interest, as per our previous work^{10,13–16}. Trans-valvular forward flow and regurgitant flow were measured over the entire cardiac cycle for both the mitral and the aortic valve from the reconstructed dynamic phase-contrast plane. Trans-valvular stroke volume across the aortic valve (AV) and mitral valve (MV) was calculated as the difference between absolute forward flow and regurgitant flow through each valve (Figure 1). In patients with AF, trans-valvular flow was measured as the average of velocities over 10 to 12 heart beats in order to remove beat-to-beat variability. Through-plane myocardial motion was accounted for in the above calculations.

Statistical analysis. Statistical analysis was performed using MedCalc Version 19.6.3. Continuous variables are expressed

as mean \pm standard deviation and categorical variables as numbers and percentages. Data was treated as normally distributed. Demographic comparisons were performed using an independent samples t-test. Student t-test was used to compare paired data. Bland-Altman plots were used to visually assess the agreement between methods and investigate absolute bias. Correlation assessment between AV and MV transvalvular stroke volumes was performed using Pearson's correlation coefficient test. Applicable tests were two-tailed; P values < 0.05 were deemed significant.

Results

Patient characteristics

Eight patients with AF were included and compared with ten healthy controls in sinus rhythm¹⁷. Baseline demographics are detailed in Table 1. Seven (88%) of the AF patients were male and the mean age was 62 ± 13 years. Age, body mass index, and heart rate were significantly higher in patients with AF than healthy controls.

Image quality assessment

All scans were of either good quality with minimal blurring artefacts, or excellent quality with no artefacts (grade 1 and 0, respectively).

Baseline cardiovascular MR scan parameters

Baseline cardiovascular MR scan parameters are summarised in Table 2. Left ventricular end-systolic volumes (LV-ESV) were significantly higher in patients with AF compared to

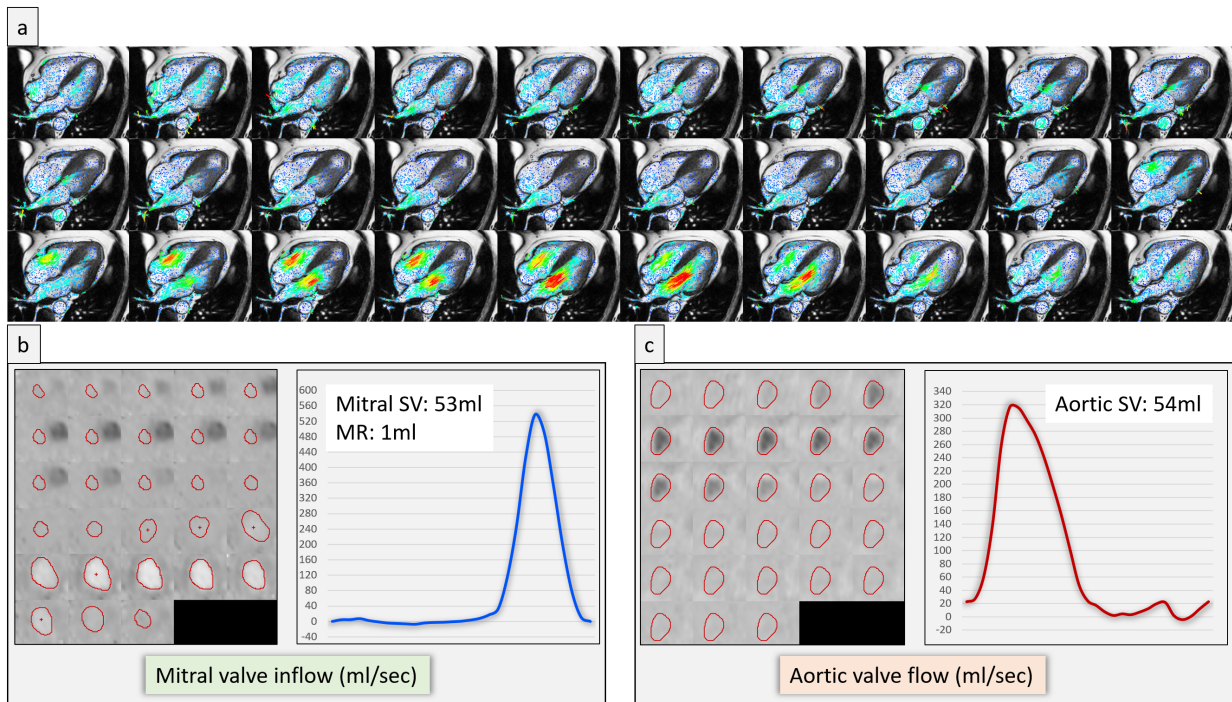


Figure 1. A case example of a patient in atrial fibrillation demonstrating two-dimensional velocity vectors superimposed over cine images (a), and an example of segmentation of valvular flow contours on the phase contrast multiplanar reconstruction alongside mitral valve stroke volumes (SV) (b) and aortic valve SV (c).

Table 1. Baseline demographics.

	Healthy controls (n=10)	AF patients (n=8)	P-Value
Age (years)	41±20	62±13	0.02
Sex (female)	3	1	0.4
Weight (kg)	72±12	94±16	<0.01
Height (cm)	170±8	174±10	0.32
Body mass index (kg/m ²)	25±2	31±5	<0.01
Heart rate (bpm)	68.5±9	83±16	0.03
Smoker (n)	0	3	0.02
Hypertension (n)	0	3	0.02
Hypercholesterolaemia (n)	0	1	0.24
Diabetes mellitus (n)	0	1	0.24

Table 2. Cardiovascular MRI parameters.

	Health controls (n=10)	AF patients (n=8)	P-Value
LV-EDV (ml)	155±39	202±39	0.02
LV-ESV (ml)	59±15	133±42	<0.01
LV-SV (ml)	97±29	69±20	0.03
LV-EF (%)	62±6	35±9	<0.01
LV-EDM (g)	94±24	129±30	0.01
LV-ESM (g)	96±25	134±30	0.01
LV-EDVi (ml/m ²)	84±16	95±20	0.18
LV-ESVi (ml/m ²)	32±7	63±21	<0.01
LV-SVi (ml/m ²)	52±12	32±9	<0.01
LV-EDMi (g/m ²)	50±10	61±13	0.06
MV SV (ml)	73±26	53±12	0.06
MR volume (ml)	0±0	6±6	<0.01
AV SV (ml)	78±30	51±13	0.04

Abbreviations: AV, aortic valve; EDM, end-diastolic mass; EDV, end-diastolic volume; EF, ejection fraction; ESM, end-systolic mass; ESV, end-systolic volume; LV, left ventricular; MV, mitral valve; MR, mitral regurgitant; SV, stroke volume. The suffix *i* represents indexed values to body surface area.

healthy controls (LV-ESV AF: 133 ± 42 ml, control: 59 ± 15 ml; P < 0.01). Left ventricular stroke volume (LV-SV) and ejection fraction (LV-EF) were significantly lower in AF patients

(LV-SV AF: 69 ± 20 ml, control: 97 ± 29 ml; P = 0.03; LV-EF AF: 35 ± 9%, control: 62 ± 6%; P < 0.01). AV stroke volumes were significantly lower in AF patients (AF: 51 ± 13 ml, control: 78 ± 30 ml; P=0.04); MV stroke volume was also lower in those with AF, but this did not meet statistical significance (AF: 53 ± 12 ml, control: 73 ± 26 ml; P=0.06). Patients with AF had a mitral regurgitant volume of 6 ± 6 ml; none of the healthy controls had mitral regurgitation.

Consistency in 4D flow derived valvular stroke volumes
There was no significant difference in MV and AV stroke volumes in healthy controls (72.85 ± 25.87 ml vs. 77.65 ± 30.45 ml respectively; P=0.34) or in patients with AF (52.92 ± 11.8 ml vs. 51.29 ± 12.86 ml; P=0.56) (Figure 2). MV forward flow, regurgitant flow and stroke volume for individual AF patients are detailed in Figure 3. In both AF patients and controls, the mean MV and AV stroke volumes were compared with the difference between MV and AV stroke volumes by Bland-Altman analysis (Figure 4). No significant bias was observed, although bias was higher in healthy controls (-4.8, 95% CI -15.64 to 6.04; P=0.34) than in patients with AF (1.64, 95% CI -4.7 to 7.94; P=0.56). There was a strong correlation between MV and AV stroke volumes in healthy controls (Pearson's correlation $r = 0.87$, 95% CI 0.52 to 0.97; P=0.0011) and AF patients ($r = 0.82$, 95% CI 0.26 to 0.97; P=0.0134) (Figure 5).

Discussion

This study investigated the feasibility of performing 4D flow cardiovascular MRI in patients with AF for the accurate assessment of trans-valvular flow. We demonstrated that 4D flow cardiovascular MRI is feasible in patients with rate-controlled AF, and that it allows accurate quantification of trans-valvular flow and regurgitation in patients with AF.

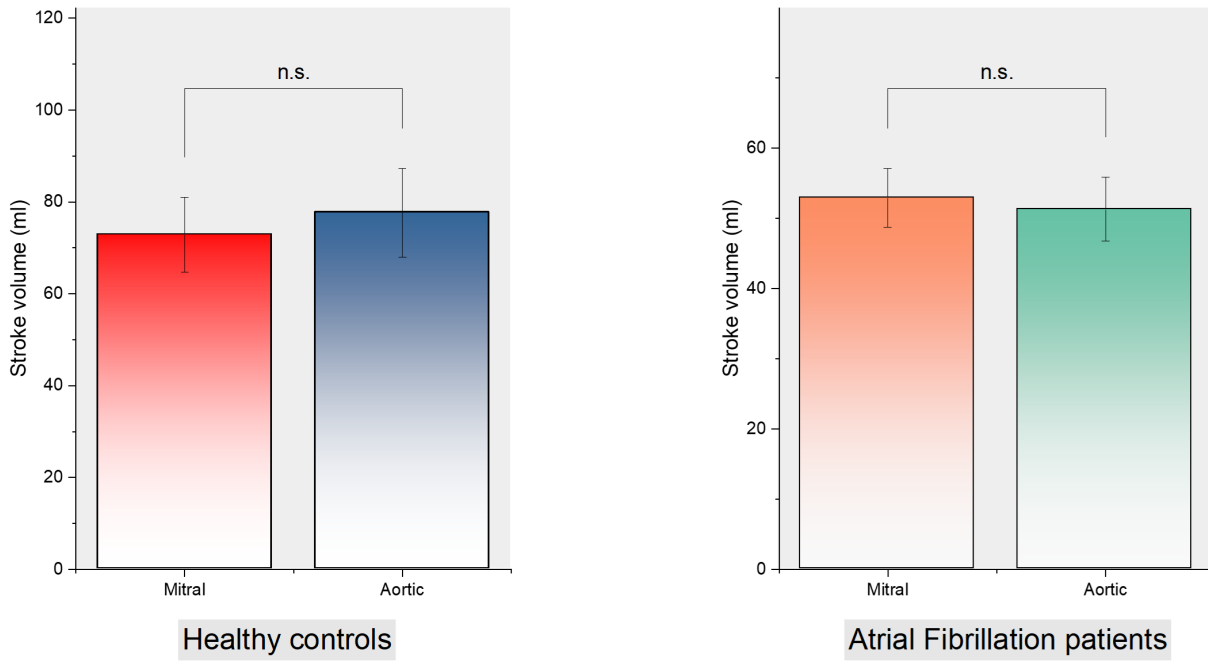


Figure 2. Mitral and aortic valve stroke volumes in healthy controls and patients with atrial fibrillation.

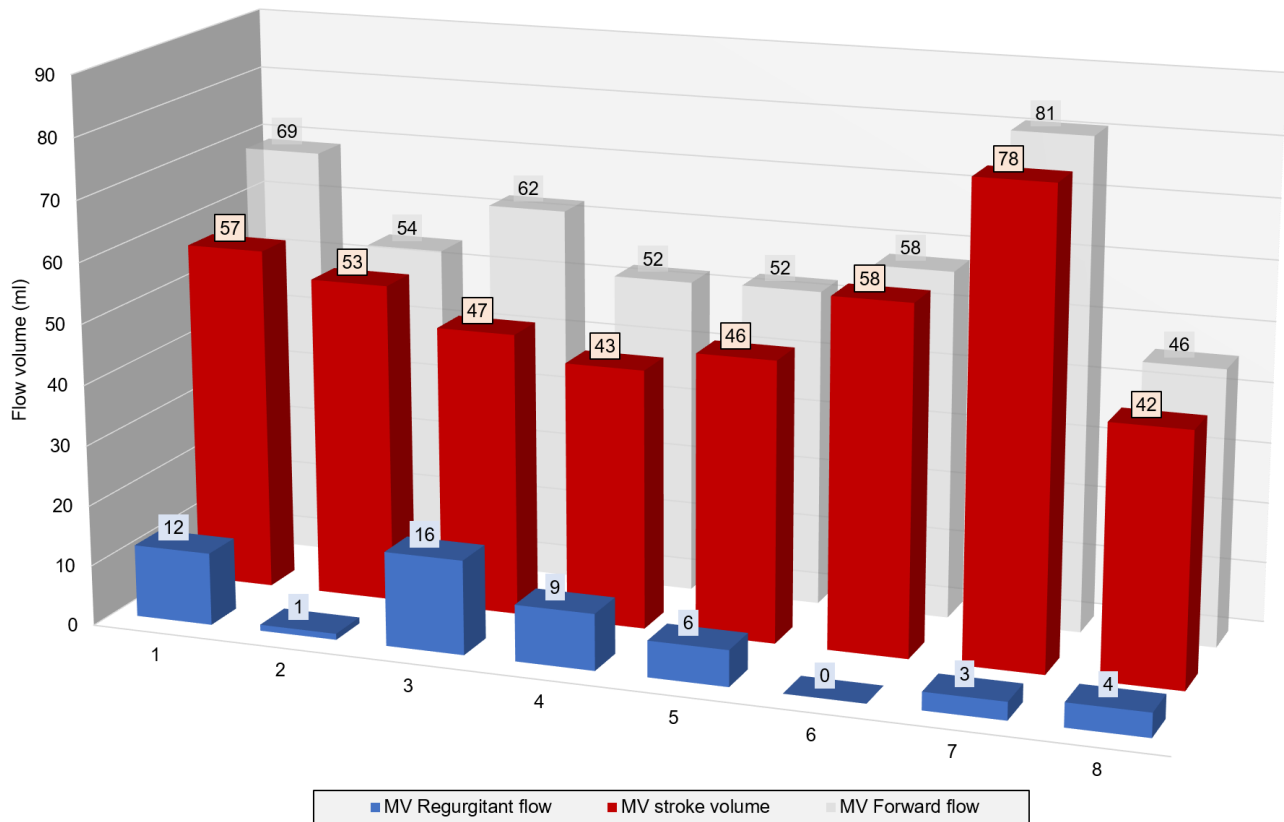


Figure 3. Mitral valve (MV) forward flow, regurgitant flow and stroke volume for individual patients with atrial fibrillation.

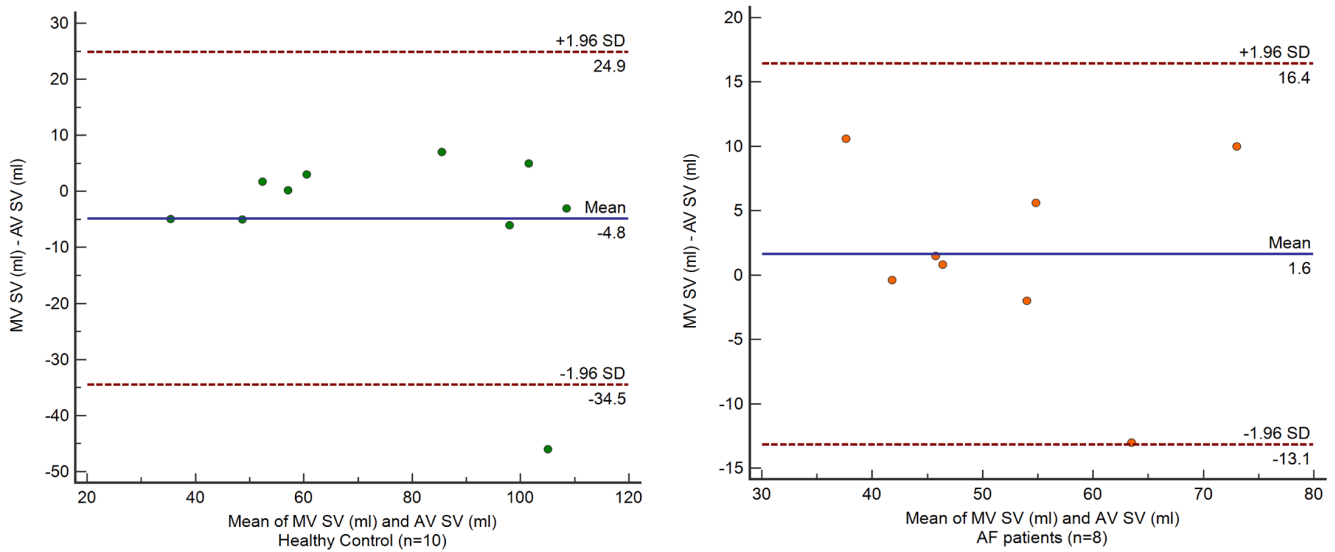


Figure 4. Bland-Altman plot of the mean of mitral valve (MV) and aortic valve (AV) stroke volumes (SV) in healthy control and patients with atrial fibrillation.

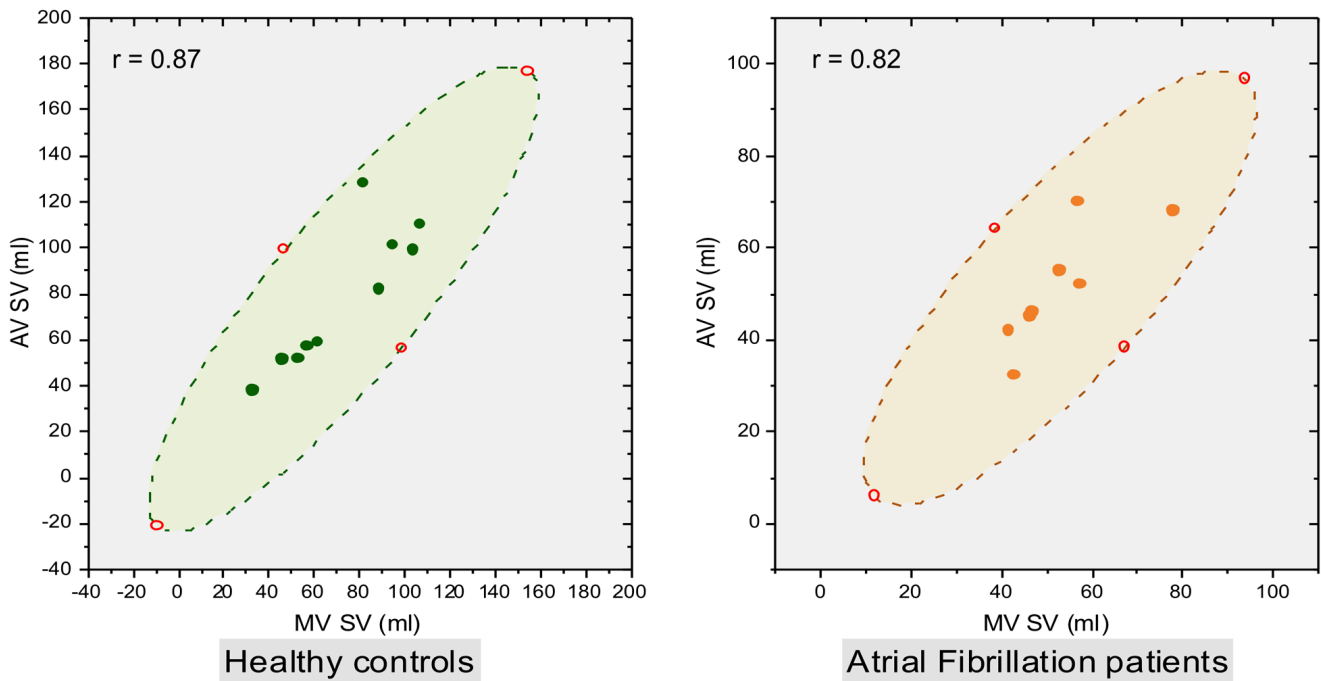


Figure 5. Pearson correlation (r) between mitral valve (MV) stroke volume (SV) and aortic valve (AV) SV in healthy controls and patients with atrial fibrillation. The shaded areas represent 95% confidence intervals.

Known applications of 4D flow cardiovascular MRI in AF. Previous research applications of 4D flow cardiovascular MRI in patients with AF are limited and include the assessment of left atrial (LA) flow and stasis^{18–23}, the assessment of LA and LV function following cardioversion^{18,24}, and the effect of AF on aortic flow²⁵. Kim *et al.* observed that LV stroke volume and components of LV flow (including delayed ejection, retained inflow, and residual volume) were significantly different between patients with paroxysmal AF (in sinus rhythm at the time of 4D flow cardiovascular MRI) and healthy controls²⁶, suggesting that the substrate leading to AF in itself may lead to LV flow impairment, rather than the rhythm disturbance alone.

Quantitative assessment of trans-valvular stroke volume

No previous 4D flow cardiovascular MRI studies have examined the assessment of trans-valvular flow in patients with AF. In order to ensure the appropriate application of 4D flow cardiovascular MRI in patients with AF in both the research and clinical settings, the validity, accuracy, and reliability of trans-valvular flow measurements are fundamental. Our study demonstrates that there is no significant bias between AV and MV stroke volumes in patients with AF, similar to healthy controls, and found a strong correlation between MV and AV stroke volumes in both groups. As no reference method for MV or AV trans-valvular stroke volumes exists in patients with AF, we used a mean of both measurements when examining for agreement between measurements (Figure 4). In echocardiography studies, the optimal mean number of beats required to estimate AV flow and cardiac output in AF is 13 beats (with a range of 4 to 17) to achieve a variability of less than 2%, compared to a mean of 4 beats in sinus rhythm^{27,28}. Similarly, we measured trans-valvular flow as the average of velocities over many heart beats, in order to remove beat-to-beat variability. 4D flow MRI may therefore have an advantage to quantify transvalvular flow in atrial fibrillation. We noticed that the LV stroke volume from cine segmentation were higher in both the healthy and AF cohorts when compared to respective mitral and aortic flows. We suspect this is mainly due to variation of basal slice segmentation on cine, as it is well known that slight variations in basal segmentation of endocardium can result in significant differences in stroke volume.

Quantitative assessment of mitral regurgitation

Mitral regurgitation remains a common clinical entity in patients with AF. The superiority of cardiovascular MRI in the quantitative evaluation of mitral regurgitant volume in comparison with 2-dimensional echocardiography is well established^{29,30}. Our data highlights the precision with which 4D flow cardiovascular MRI is able to calculate mitral regurgitant volume in AF, within 3–4 ml (Figure 3). This allows the severity of mitral regurgitation to be graded with incredible accuracy compared with echocardiography. These findings warrant investigation in larger cohorts.

Limitations

The number of patients with AF included in this study was low. However, the key findings were based on intra-group comparisons showing internal validity. Secondly, we recruited patients with rate-controlled AF and in stable conditions. The results of this study cannot therefore be extrapolated to patients in AF with a ventricular rate greater than 110bpm. Third, patients underwent a single scan only, without longitudinal follow-up. Given previous evidence of physiological variability over time in patients with AF³¹, a temporal assessment would be beneficial.

Conclusion

Whole-heart, 4D flow cardiovascular MRI is feasible in patients with AF and allows reliable quantification of trans-valvular flow and regurgitation.

Data availability

Underlying data

Access to the raw images of patients is not permitted since specialised post-processing imaging-based solutions can identify the study patients in the future.

Harvard Dataverse: Feasibility and validation of trans-valvular flow derived by four-dimensional flow cardiovascular magnetic resonance imaging in patients with atrial fibrillation. <https://doi.org/10.7910/DVN/YHDLIT>¹⁷.

This project contains the following underlying data:

- Data for repository.tab (spreadsheet demographic and outcome variables)

Data are available under the terms of the [Creative Commons Zero “No rights reserved” data waiver](#) (CC0 1.0 Public domain dedication).

Consent

All patients gave written informed consent prior to MRI examinations.

Author contributions

M.T.M., C.G.C., G.W., R.C.G., A.A.B. and A.L.K. were involved in study conception. M.T.M., P.D.M., A.J.S. and P.G. collated the datasets, drafted the manuscript, and submitted the data to the repository. J.P.G. (Leeds), S.P., E.L. and P.P.S. were involved in acquisition and analysis, as well as data interpretation. R.J.v.d.G. assisted with the conception and design of the study, in addition to developing the methods for the study and proving the software for analysis. S.P. supervised the study. P.D.M., J.P.G. (Sheffield), V.T., V.V., and A.J.S. provided critical input in methodology, drafting of the manuscript and discussion. P.G. contributed significantly to the conception, analysis, statistics and writing of this study. All authors read and approved the final manuscript.

References

1. Benjamin EJ, Muntner P, Alonso A, *et al.*: **Heart Disease and Stroke Statistics-2019 Update: A Report From the American Heart Association.** *Circulation.* 2019; **139**(10): e56–e528.
[PubMed Abstract](#) | [Publisher Full Text](#)
2. Krijthe BP, Kunst A, Benjamin EJ, *et al.*: **Projections on the number of individuals with atrial fibrillation in the European Union, from 2000 to 2060.** *Eur Heart J.* 2013; **34**(35): 2746–51.
[PubMed Abstract](#) | [Publisher Full Text](#) | [Free Full Text](#)
3. Staerk L, Sherer JA, Ko D, *et al.*: **Atrial Fibrillation: Epidemiology, Pathophysiology, and Clinical Outcomes.** *Circ Res.* 2017; **120**(9): 1501–17.
[PubMed Abstract](#) | [Publisher Full Text](#) | [Free Full Text](#)
4. Hindricks G, Potpara T, Dagres N, *et al.*: **2020 ESC Guidelines for the diagnosis and management of atrial fibrillation developed in collaboration with the European Association for Cardio-Thoracic Surgery (EACTS).** *Eur Heart J.* 2021; **42**(5): 373–498.
[PubMed Abstract](#) | [Publisher Full Text](#)
5. von Knobelsdorff-Brenkenhoff F, Schulz-Menger J: **Role of cardiovascular magnetic resonance in the guidelines of the European Society of Cardiology.** *J Cardiovasc Magn Reson.* 2016; **18**: 6.
[PubMed Abstract](#) | [Publisher Full Text](#) | [Free Full Text](#)
6. Westenberg JJM, Roes SD, Marsan NA, *et al.*: **Mitral Valve and Tricuspid Valve Blood Flow: Accurate Quantification with 3D Velocity-encoded MR Imaging with Retrospective Valve Tracking.** *Radiology.* 2008; **249**(3): 792–800.
[PubMed Abstract](#) | [Publisher Full Text](#)
7. Feneis JF, Kyubwa E, Atianzar K, *et al.*: **4D flow MRI quantification of mitral and tricuspid regurgitation: Reproducibility and consistency relative to conventional MRI.** *J Magn Reson Imaging.* 2018; **48**(4): 1147–1158.
[PubMed Abstract](#) | [Publisher Full Text](#)
8. Fidock B, Barker N, Balasubramanian N, *et al.*: **A Systematic Review of 4D-Flow MRI Derived Mitral Regurgitation Quantification Methods.** *Front Cardiovasc Med.* 2019; **6**: 103.
[PubMed Abstract](#) | [Publisher Full Text](#) | [Free Full Text](#)
9. Saunderson CED, Paton MF, Chowdhary A, *et al.*: **Feasibility and validation of trans-valvular flow derived by four-dimensional flow cardiovascular magnetic resonance imaging in pacemaker recipients.** *Magn Reson Imaging.* 2020; **74**: 46–55.
[PubMed Abstract](#) | [Publisher Full Text](#) | [Free Full Text](#)
10. Garg P, Westenberg JJM, van den Boogaard PJ, *et al.*: **Comparison of fast acquisition strategies in whole-heart four-dimensional flow cardiac MR: Two-center, 1.5 Tesla, phantom and in vivo validation study.** *J Magn Reson Imaging.* 2018; **47**(1): 272–81.
[PubMed Abstract](#) | [Publisher Full Text](#) | [Free Full Text](#)
11. Swoboda PP, Erhayiem B, McDiarmid AK, *et al.*: **Relationship between cardiac deformation parameters measured by cardiovascular magnetic resonance and aerobic fitness in endurance athletes.** *J Cardiovasc Magn Reson.* 2016; **18**(1): 48.
[PubMed Abstract](#) | [Publisher Full Text](#) | [Free Full Text](#)
12. Roes SD, Hammer S, van der Geest RJ, *et al.*: **Flow Assessment Through Four Heart Valves Simultaneously Using 3-Dimensional 3-Directional Velocity-Encoded Magnetic Resonance Imaging With Retrospective Valve Tracking in Healthy Volunteers and Patients With Valvular Regurgitation.** *Invest Radiol.* 2009; **44**(10): 669–75.
[PubMed Abstract](#) | [Publisher Full Text](#)
13. Garg P, van der Geest RJ, Swoboda PP, *et al.*: **Left ventricular thrombus formation in myocardial infarction is associated with altered left ventricular blood flow energetics.** *Eur Heart J Cardiovasc Imaging.* 2019; **20**(1): 108–17.
[PubMed Abstract](#) | [Publisher Full Text](#) | [Free Full Text](#)
14. Barker N, Zafar H, Fidock B, *et al.*: **Age-associated changes in 4D flow CMR derived Tricuspid Valvular Flow and Right Ventricular Blood Flow Kinetic Energy.** *Sci Rep.* 2020; **10**(1): 9908.
[PubMed Abstract](#) | [Publisher Full Text](#) | [Free Full Text](#)
15. Archer GT, Elhawaz A, Barker N, *et al.*: **Validation of four-dimensional flow cardiovascular magnetic resonance for aortic stenosis assessment.** *Sci Rep.* 2020; **10**(1): 10569.
[PubMed Abstract](#) | [Publisher Full Text](#) | [Free Full Text](#)
16. Crandon S, Westenberg JJM, Swoboda PP, *et al.*: **Impact of Age and Diastolic Function on Novel, 4D flow CMR Biomarkers of Left Ventricular Blood Flow Kinetic Energy.** *Sci Rep.* 2018; **8**(1): 14436.
[PubMed Abstract](#) | [Publisher Full Text](#) | [Free Full Text](#)
17. Mills M: **Feasibility and validation of trans-valvular flow derived by four-dimensional flow cardiovascular magnetic resonance imaging in patients with atrial fibrillation.** Harvard Dataverse, V1. 2021.
<http://www.doi.org/10.7910/DVN/YHDLIT>
18. Cibis M, Lindahl TL, Ebberts T, *et al.*: **Left Atrial 4D Blood Flow Dynamics and Hemostasis following Electrical Cardioversion of Atrial Fibrillation.** *Front Physiol.* 2017; **8**: 1052.
[PubMed Abstract](#) | [Publisher Full Text](#) | [Free Full Text](#)
19. Costello BT, Voskoboinik A, Qadri AM, *et al.*: **Measuring atrial stasis during sinus rhythm in patients with paroxysmal atrial fibrillation using 4 Dimensional flow imaging: 4D flow imaging of atrial stasis.** *Int J Cardiol.* 2020; **315**: 45–50.
[PubMed Abstract](#) | [Publisher Full Text](#)
20. Garcia J, Sheitt H, Bristow MS, *et al.*: **Left atrial vortex size and velocity distributions by 4D flow MRI in patients with paroxysmal atrial fibrillation: Associations with age and CHA₂DS₂-VASc risk score.** *J Magn Reson Imaging.* 2020; **51**(3): 871–84.
[PubMed Abstract](#) | [Publisher Full Text](#)
21. Markl M, Lee DC, Furiasse N, *et al.*: **Left Atrial and Left Atrial Appendage 4D Blood Flow Dynamics in Atrial Fibrillation.** *Circ Cardiovasc Imaging.* 2016; **9**(9): e004984.
[PubMed Abstract](#) | [Publisher Full Text](#) | [Free Full Text](#)
22. Markl M, Carr M, Ng J, *et al.*: **Assessment of left and right atrial 3D hemodynamics in patients with atrial fibrillation: a 4D flow MRI study.** *Int J Cardiovasc Imaging.* 2016; **32**(5): 807–15.
[PubMed Abstract](#) | [Publisher Full Text](#)
23. Lee DC, Markl M, Ng J, *et al.*: **Three-dimensional left atrial blood flow characteristics in patients with atrial fibrillation assessed by 4D flow CMR.** *Eur Heart J Cardiovasc Imaging.* 2016; **17**(11): 1259–68.
[PubMed Abstract](#) | [Publisher Full Text](#) | [Free Full Text](#)
24. Karlsson LO, Erixon H, Ebberts T, *et al.*: **Post-cardioversion Improvement in LV Function Defined by 4D Flow Patterns and Energetics in Patients With Atrial Fibrillation.** *Front Physiol.* 2019; **10**: 659.
[PubMed Abstract](#) | [Publisher Full Text](#) | [Free Full Text](#)
25. Deyranlou A, Naish JH, Miller CA, *et al.*: **Numerical Study of Atrial Fibrillation Effects on Flow Distribution in Aortic Circulation.** *Ann Biomed Eng.* 2020; **48**(4): 1291–308.
[PubMed Abstract](#) | [Publisher Full Text](#) | [Free Full Text](#)
26. Kim H, Sheitt H, Jamaludin F, *et al.*: **Left Ventricular Flow Analysis in Atrial Fibrillation.** *Annu Int Conf IEEE Eng Med Biol Soc.* 2020; **2020**: 1182–1185.
[PubMed Abstract](#) | [Publisher Full Text](#)
27. Sumida T: **Single-beat determination of doppler-derived aortic flow measurement in patients with atrial fibrillation.** *J Am Soc Echocardiogr.* 2003; **16**(7): 712–5.
[PubMed Abstract](#) | [Publisher Full Text](#)
28. Dubrey SW, Falk RH: **Optimal number of beats for the Doppler measurement of cardiac output in atrial fibrillation.** *J Am Soc Echocardiogr.* 1997; **10**(1): 67–71.
[PubMed Abstract](#) | [Publisher Full Text](#)
29. Le Goffic C, Toledano M, Ennezat PV, *et al.*: **Quantitative Evaluation of Mitral Regurgitation Secondary to Mitral Valve Prolapse by Magnetic Resonance Imaging and Echocardiography.** *Am J Cardiol.* 2015; **116**(9): 1405–10.
[PubMed Abstract](#) | [Publisher Full Text](#)
30. Uretsky S, Gillam L, Lang R, *et al.*: **Discordance between echocardiography and MRI in the assessment of mitral regurgitation severity: a prospective multicenter trial.** *J Am Coll Cardiol.* 2015; **65**(11): 1078–88.
[PubMed Abstract](#) | [Publisher Full Text](#)
31. Stoll VM, Loudon M, Eriksson J, *et al.*: **Test-retest variability of left ventricular 4D flow cardiovascular magnetic resonance measurements in healthy subjects.** *J Cardiovasc Magn Reson.* 2018; **20**(1): 15.
[PubMed Abstract](#) | [Publisher Full Text](#) | [Free Full Text](#)

Open Peer Review

Current Peer Review Status:  

Version 2

Reviewer Report 25 May 2021

<https://doi.org/10.21956/wellcomeopenres.18674.r43954>

© 2021 Stoll V. This is an open access peer review report distributed under the terms of the [Creative Commons Attribution License](#), which permits unrestricted use, distribution, and reproduction in any medium, provided the original work is properly cited.



Victoria M. Stoll

Institute of Cardiovascular Sciences, University of Birmingham, Birmingham, UK

The authors have fully addressed my concerns and I am happy to approve the article without reservation.

Competing Interests: No competing interests were disclosed.

Reviewer Expertise: 4D flow, congenital heart disease, cardiac MRI

I confirm that I have read this submission and believe that I have an appropriate level of expertise to confirm that it is of an acceptable scientific standard.

Reviewer Report 19 May 2021

<https://doi.org/10.21956/wellcomeopenres.18674.r43955>

© 2021 Broncano J. This is an open access peer review report distributed under the terms of the [Creative Commons Attribution License](#), which permits unrestricted use, distribution, and reproduction in any medium, provided the original work is properly cited.



Jordi Broncano 

Cardiothoracic Imaging Section, Health Time, Hospital de la Cruz Roja and San Juan de Dios, Cordoba, Spain

No new comments to make. Appreciate the work done by the authors.

Competing Interests: No competing interests were disclosed.

Reviewer Expertise: Cardiac MRI

I confirm that I have read this submission and believe that I have an appropriate level of expertise to confirm that it is of an acceptable scientific standard.

Version 1

Reviewer Report 14 May 2021

<https://doi.org/10.21956/wellcomeopenres.18364.r43358>

© 2021 Stoll V. This is an open access peer review report distributed under the terms of the [Creative Commons Attribution License](#), which permits unrestricted use, distribution, and reproduction in any medium, provided the original work is properly cited.



Victoria M. Stoll

Institute of Cardiovascular Sciences, University of Birmingham, Birmingham, UK

This article aims to assess the use of 4D flow in patients with atrial fibrillation. In particular it looks at the trans-valvular flow across the mitral compared to aortic valve.

10 healthy controls and 8 patients with atrial fibrillation were enrolled in the study. All scans were deemed to be of sufficient quality for analysis. The study found good correlations between MV and AV flow and no significant bias in these stroke volumes.

I only have very minor suggestions for the manuscript:

- Given there was no statistical difference in LV end diastolic volume when indexed values are used I would remove the comment about non-indexed end diastolic volumes being significantly different.
- Do you have any echo data on these patients? The very low EF is quite striking and I wondered how accurate that is or whether it is a reflection of the difficulty of imaging these patients with MR cine images.
- When presenting the data for the flow across the mitral valve then aortic valve it would be easier if you kept the order the same between all figures - figure 1 has Ao valve, then mitral whereas all other figures have the other order. Additionally fig 2 shows the bars as MV then Ao valve but the figure legend says Aortic valve first. Also on Figure 2 the bar graph for AF patients has a stroke volume 1 as the y axis label - I presume this should just be stroke volume?
- Table 1 has a tiny typo of 'health' rather than 'healthy'.
- Figure 3 - can all data be presented to the same number of significant figures please - I would assume whole numbers are most appropriate as I doubt the techniques can be as accurate as to two decimal places.
- Otherwise this is a soundly conducted study showing that 4D flow parameters can be

measured in patients with AF. Did any patients undergo repeat scans to look at stability over time? If not it would be worth adding this lack of temporal assessment to the limitations section as it would be interesting to see if AF patients have more or less variability than healthy controls (see Stoll *et al.*, 2018¹ who found likely physiological variability to be important over time).

References

1. Stoll V, Loudon M, Eriksson J, Bissell M, et al.: Test-retest variability of left ventricular 4D flow cardiovascular magnetic resonance measurements in healthy subjects. *Journal of Cardiovascular Magnetic Resonance*. 2018; **20** (1). [Publisher Full Text](#)

Is the work clearly and accurately presented and does it cite the current literature?

Yes

Is the study design appropriate and is the work technically sound?

Yes

Are sufficient details of methods and analysis provided to allow replication by others?

Yes

If applicable, is the statistical analysis and its interpretation appropriate?

Yes

Are all the source data underlying the results available to ensure full reproducibility?

Partly

Are the conclusions drawn adequately supported by the results?

Yes

Competing Interests: No competing interests were disclosed.

Reviewer Expertise: 4D flow, congenital heart disease, cardiac MRI

I confirm that I have read this submission and believe that I have an appropriate level of expertise to confirm that it is of an acceptable scientific standard, however I have significant reservations, as outlined above.

Author Response 17 May 2021

Mark Mills, University of Sheffield, Sheffield, UK

This article aims to assess the use of 4D flow in patients with atrial fibrillation. In particular it looks at the trans-valvular flow across the mitral compared to aortic valve.

10 healthy controls and 8 patients with atrial fibrillation were enrolled in the study. All scans were deemed to be of sufficient quality for analysis. The study found good correlations between MV

and AV flow and no significant bias in these stroke volumes.

I only have very minor suggestions for the manuscript:

Given there was no statistical difference in LV end diastolic volume when indexed values are used I would remove the comment about non-indexed end diastolic volumes being significantly different.

Response: We thank the reviewer for their feedback and for giving us the opportunity to improve our manuscript. We have removed the comment regarding end-diastolic volumes being different from the text.

Do you have any echo data on these patients? The very low EF is quite striking and I wondered how accurate that is or whether it is a reflection of the difficulty of imaging these patients with MR cine images.

Response: We thank the reviewer for this comment. Unfortunately, we do not have echo data on these patients.

When presenting the data for the flow across the mitral valve then aortic valve it would be easier if you kept the order the same between all figures - figure 1 has Ao valve, then mitral whereas all other figures have the other order. Additionally fig 2 shows the bars as MV then Ao valve but the figure legend says Aortic valve first. Also on Figure 2 the bar graph for AF patients has a stroke volume 1 as the y axis label - I presume this should just be stroke volume?

Response: We thank the reviewer for their feedback.

In figure 1, we have switched figure b and c around so that mitral valve is first, and aortic valve second (consistent with subsequent figures). The figure 1 legend has also been amended to reflect this change.

The legend to figure 2 has been amended to state "Mitral and aortic valve stroke volumes [...]".

The y axis on Figure 2 (AF patients) has been corrected to "stroke volume".

Table 1 has a tiny typo of 'health' rather than 'healthy'.

Response: Thank you for identifying this. We have modified it.

Figure 3 - can all data be presented to the same number of significant figures please - I would assume whole numbers are most appropriate as I doubt the techniques can be as accurate as to two decimal places.

Response: We thank the reviewer for pointing this out. We have changed this to whole numbers.

Otherwise this is a soundly conducted study showing that 4D flow parameters can be measured

in patients with AF. Did any patients undergo repeat scans to look at stability over time? If not it would be worth adding this lack of temporal assessment to the limitations section as it would be interesting to see if AF patients have more or less variability than healthy controls (see Stoll et al., 20181 who found likely physiological variability to be important over time).

Response: Thank you for your comment. Patients did not undergo repeat scans. We have added the following sentence to the limitations section:

“Third, patients underwent a single scan only, without longitudinal follow-up. Given previous evidence of physiological variability over time in patients with AF (Stoll et al., 2018), a temporal assessment would be beneficial.”

This new reference has also been added to the reference list (reference 31).

31. Stoll VM, Loudon M, Eriksson J, et al.: Test-retest variability of left ventricular 4D flow cardiovascular magnetic resonance measurements in healthy subjects. *J Cardiovasc Magn Reson.* 2018;20(1):15. 10.1186/s12968-018-0432-4

Competing Interests: None.

Reviewer Report 30 April 2021

<https://doi.org/10.21956/wellcomeopenres.18364.r43357>

© 2021 Broncano J. This is an open access peer review report distributed under the terms of the [Creative Commons Attribution License](#), which permits unrestricted use, distribution, and reproduction in any medium, provided the original work is properly cited.



Jordi Broncano 

Cardiothoracic Imaging Section, Health Time, Hospital de la Cruz Roja and San Juan de Dios, Cordoba, Spain

With this original paper, the authors provide further insight on the feasibility of 4D flow analysis in a complex cohort for obtaining cardiac images such as in patients with atrial fibrillation.

Introduction:

Well balanced with clear identification of the clinical problem and the main purpose of the study.

Materials & methods and results:

Well presented and detailed. Image analysis methodology clearly displayed. Graphics and results help to explain the main objective of the study.

Minor comment: The AV and MV abbreviations are defined in the abstract but should be defined in the main text.

Discussion and conclusion:

Well-conducted. Comprehensive exposure of the limitations. Conclusion well presented.

Tables:

Well balanced with clear information and adequate regarding the objectives stated in the study.

Images:

Figure 1a. The only comment I have with this figure is that the large amount of images in it makes difficult to visualize the great quality of the 4D flow images. I would suggest to reduce the number of images included in figure 1a.

Is the work clearly and accurately presented and does it cite the current literature?

Yes

Is the study design appropriate and is the work technically sound?

Yes

Are sufficient details of methods and analysis provided to allow replication by others?

Yes

If applicable, is the statistical analysis and its interpretation appropriate?

Yes

Are all the source data underlying the results available to ensure full reproducibility?

Yes

Are the conclusions drawn adequately supported by the results?

Yes

Competing Interests: No competing interests were disclosed.

Reviewer Expertise: Cardiac MRI

I confirm that I have read this submission and believe that I have an appropriate level of expertise to confirm that it is of an acceptable scientific standard.

Author Response 17 May 2021

Mark Mills, University of Sheffield, Sheffield, UK

With this original paper, the authors provide further insight on the feasibility of 4D flow analysis in a complex cohort for obtaining cardiac images such as in patients with atrial fibrillation.

Response: We thank the insightful reviewer for their positive feedback.

Introduction:

Well balanced with clear identification of the clinical problem and the main purpose of the study.

Response: We thank the reviewer for their feedback.

Materials & methods and results:

Well presented and detailed. Image analysis methodology clearly displayed. Graphics and results help to explain the main objective of the study.

Response: We thank the reviewer for their feedback.

Minor comment: The AV and MV abbreviations are defined in the abstract but should be defined in the main text.

Response: Thank you for highlighting this. This has now been modified.

Discussion and conclusion:

Well-conducted. Comprehensive exposure of the limitations. Conclusion well presented.

Response: We thank the reviewer for their feedback.

Tables:

Well balanced with clear information and adequate regarding the objectives stated in the study.

Response: We thank the reviewer for their feedback.

Images:

Figure 1a. The only comment I have with this figure is that the large amount of images in it makes difficult to visualize the great quality of the 4D flow images. I would suggest to reduce the number of images included in figure 1a.

Response: We thank the reviewer for this comment. The reason for inclusion of all the images is to show how 4D flow 2D vectors performed throughout the cardiac cycle. Hence, we have not made changes to this figure. Nevertheless, we have addressed comments from reviewer 2 regarding all figures.

Competing Interests: None.