

This is a post-peer-review, pre-copyedit version of an article published in The European Journal of Pediatrics. The final authenticated version is available online at:

<http://dx.doi.org/10.1007/s00431-016-2737-3>

This article is protected by copyright. All rights reserved.

ORIGINAL ARTICLE

Title: Cerebral function monitoring on a general paediatric ward: feasibility and potential

AUTHORS:

Vivek Kalra¹

Shahul Sikkander Shaw¹

Stacey Dixon²

Divyen Shah^{3,4}

Paul Clarke²

AFFILIATIONS:

1. Dept. of Paediatric Neurology, and 2. Neonatal Intensive Care Unit, Jenny Lind Children's Hospital, Norfolk and Norwich University Hospital NHS Foundation Trust, Norwich, NR4 7UY, UK. 3. Neonatal Intensive Care Unit, Royal London Hospital, London, UK, and 4. Barts and the London Medical School, London, UK.

Correspondence to: Dr P Clarke, Consultant Neonatologist, Neonatal Intensive Care Unit, Norfolk & Norwich University Hospitals NHS Foundation Trust, Norwich, NR4 7UY, UK.

Email: paul.clarke@nnuh.nhs.uk Tel: 01603 286337 Fax: 01603 287584

Word count: 1865

ABSTRACT

Cerebral function monitoring is widely used in neonatal intensive care, but its potential role in assessment of older infants is scarcely reported. We reviewed use of cerebral function monitoring on a general paediatric ward in a series of young infants admitted with abnormal movements. Review of the amplitude-integrated EEG obtained by cerebral function monitoring revealed electrographic seizures in four of seven infants monitored. We also surveyed general paediatric wards in hospitals in our region of the United Kingdom to ask about current use of cerebral function monitoring and local availability of formal electroencephalography services. Cerebral function monitoring was not being used in the 16 other paediatric departments surveyed and there was very limited provision for obtaining a full-array electroencephalogram out-of-hours.

Conclusion: With adequate training and education, it is feasible to undertake cerebral function monitoring on a general paediatric ward. Continuous cerebral function monitoring is a tool that has potential use for detecting clinical seizures and augmenting clinical neuro-observations of young children admitted to a general paediatric ward.

Keywords: seizure • neurological • infant • neurophysiology • electroencephalography

List of Abbreviations:

aEEG, amplitude-integrated electroencephalogram

CFM, cerebral function monitoring

cEEG, conventional electroencephalogram

EEG, electroencephalogram

NICU, neonatal intensive care unit

What is known?

- In intensive care settings, CFM has long been used for the continuous bedside monitoring of brain function in critically ill neonates, children and adults
- Very few studies have looked at the use of CFM outside of the intensive care setting and it is presently unclear if CFM is used in the general paediatric ward

What is new?

- CFM is presently not widely used in the general paediatric setting
- With appropriate training and support, CFM can be successfully introduced to the general paediatric ward with the potential to enhance the clinical monitoring of young infants admitted with abnormal movements

INTRODUCTION:

Cerebral function monitoring (CFM) uses a portable bed-side cerebral function monitor to record background electro-cortical activity in the brain continuously. In its simplest form the device records a single channel of cross-cerebral raw electroencephalogram (EEG) from two electrodes placed on either side of the head. The raw EEG signal is filtered, rectified and processed to remove artefact, and the magnitude of the resultant signal is displayed graphically in real-time on a semi-logarithmic microvolt scale. The tracing obtained is referred to as the amplitude-integrated EEG (aEEG), and provides a useful insight into the brain's functional integrity.

Analogue CFM technology was initially developed in the 1960s for monitoring brain function in adults with neurological depression/injury or undergoing surgery [2]. Due to technical constraints and the need for constant recalibration the technology did not gain wide acceptance until a resurgence in the 1990s when the aEEG background was shown to be predictive of neurodevelopmental outcome as early as 3 hours after birth in term newborns with hypoxic-ischaemic encephalopathy [8]. Since then it has proved to be a valuable tool in the neonatal intensive care unit (NICU) for predicting the severity and prognosis of hypoxic-ischaemic encephalopathy and for detecting neonatal seizures and monitoring their treatment. Digital CFM is now widely practised in UK NICUs [5].

Surprisingly few studies have examined the utility of CFM outside the NICU setting and it is unclear whether this technology is presently employed in UK paediatric wards. CFM has been used in paediatric intensive care, where features of background aEEG activity and the presence of seizures were found to be useful predictors of outcome [3]. CFM also proved crucial in the timely diagnosis and treatment of clinically-occult status epilepticus in a young infant admitted to our hospital after near-drowning [4].

Recently, our department has offered CFM for the adjunct clinical monitoring of young infants admitted to the children's ward with abnormal movements or suspected seizures. The

aims of the present study were: i) to review whether CFM use was feasible in a series of such infants; ii) to survey all general paediatric departments in our region to ask regarding their current use of CFM and the availability of their local services for obtaining a conventional electroencephalogram (cEEG).

MATERIALS AND METHODS:

From September 2014 CFM was made available for routine clinical monitoring of infants aged <6 months who presented to the general paediatric department of the Norfolk and Norwich University Hospital with suspected seizures. With parental assent and provision of an information leaflet, [[Supporting Information File](#)] CFM was undertaken after paediatric ward admission using a digital cerebral function monitor (BRM2/3 BrainZ Instruments, Natus Medical, USA). Clinical paediatric staff underwent prior instruction in the practical use of the CFM and in the basic recognition of aEEG background voltage patterns and seizures. An experienced NICU nurse provided ad hoc support for paediatric nurses in attachment of the scalp electrodes (hydrogel and/or subdermal needle) and training in operation of the monitor.

Two channels of aEEG (C3-P3 and C4-P4) and corresponding raw EEG were recorded. Background voltage and presence of electrographic seizures were verified post hoc by two independent clinicians with experience in CFM interpretation (DS and PC); anonymised digital aEEG records were reviewed manually using Analyze software (BrainZ, Natus Medical, USA). Background voltage was determined from the cross-cerebral aEEG trace and graded using an empirical grading system described for term infants [1]. A normal background aEEG pattern was considered as one with a lower margin of the 'bandwidth' pattern $>5 \mu\text{V}$ and an upper margin $>10 \mu\text{V}$. Seizures were classified as frequent, status epilepticus, sporadic, or absent as described previously [6]. Clinical data were obtained by reviewing case notes. All clinically-obtained aEEG data files are routinely stored on our hospital's secure, backed-up hard drive and are retained in full for 25 years.

In May 2015 we telephone surveyed the 16 other hospitals with in-patient paediatric wards in the East of England region (15 district general hospitals; 1 tertiary hospital). In 2014 the cumulative birth rate for these 16 hospitals was 64,251, indicating that they served an estimated population of ~32,000 infants aged <6 months. We asked about CFM use on their general paediatric ward and about cEEG availability from local neurophysiology services.

RESULTS:

Cerebral function monitoring

Over a 6-month period, seven infants underwent CFM on the paediatric ward after admission with abnormal movements. All infants except one had been born at term. Needle electrodes were used in five cases and hydrogel electrodes were used in two cases because of parental preference. Table 1 summarises their characteristics, including age at admission, clinical presentations, duration of CFM, background voltage and seizure classification, further investigations, and final diagnosis. The aEEG trace demonstrated the presence of an abnormal background voltage and/or seizures in four of the seven infants; in all cases these electrographic abnormalities were recognised or suspected contemporaneously by an attendant clinician. Figure 1 shows an illustrative CFM screenshot from these infants. All four with electrical seizure activity on the aEEG also had accompanying signs that were suspicious for clinical seizures and their CFM had been performed out-of-hours (overnight and/or weekend) when cEEG was unavailable. Conventional EEGs were done 14-65 hours after admission.

Telephone survey of CFM use and conventional EEG availability

Our telephone survey obtained responses from all 16 centres contacted. Data were obtained from the nurse in charge/ward manager (n=9) or a paediatric registrar/junior (n=7). We found that no other general paediatric ward in our region (0/16; 0%) was presently using CFM in any children admitted. Only 1 (6%) of 17 hospitals had on-call/weekend cEEG availability.

DISCUSSION:

Our study shows that CFM can be successfully deployed within the general paediatric ward after adequate training, and that it can thus be used for the clinical monitoring of older infants as well as neonates. Despite an initial wariness shown by some nurses and doctors following appearance of this 'novel' equipment on the paediatric ward, with ongoing education and support the bedside use of the technology became accepted. We have shown that CFM use is feasible in a general paediatric setting.

CFM permitted enhanced clinical monitoring of young infants admitted with possible seizures. It allowed confirmation of abnormal brain electrical activity and the documentation of clinical seizures for the medical record, particularly at times when cEEG was unavailable. CFM demonstrated electrical seizures in four infants; all had accompanying clinical seizure activity as well and were later confirmed to have a seizure disorder. Documentary evidence of seizures captured on CFM was particularly useful in case 3, who had a normal cEEG a few days later. Two of three other infants who had a normal aEEG trace were later found to have other non-neurological pathologies to explain their abnormal movements. Hence CFM may have a role in confirming or excluding seizures in this setting.

Other situations where routine CFM may potentially be useful in the paediatric setting include in the detection of electrographic-only seizures and non-convulsive status epilepticus, and in augmenting seizure charting, which is the current standard practice in the UK for recording clinical seizure frequency. It may yet be shown to have a valuable place for monitoring high-dependency paediatric patients with neurological concerns, for example including children admitted with decreased conscious state, head injury, asphyxiation, meningitis, or poisoning. CFM can provide objective evidence of improvement (or deterioration) in electro-cortical function to augment the routine clinical neuro-observations. In contrast to the formal cEEG, which typically provides a detailed 'snapshot' in a limited time, CFM can continue uninterrupted for days if necessary [5]. However, CFM is not a replacement

for the detailed cEEG or its interpretation by an expert neurophysiologist, and we would still recommend that cEEG is obtained routinely in any child with seizures or a severely abnormal CFM background, and in those with ongoing clinical concerns despite an apparently-normal aEEG trace. A study in neonates shows that CFM detects most electrographic seizures apparent on cEEG, but may miss brief or localised seizures [9]; studies in older infants and young children are required to examine comparative seizure detection rates in the paediatric setting and population.

Our study has some limitations. It was a small observational study that reviewed the feasibility and explored potential roles of CFM on a general paediatric ward. Proof of the clinical benefit of CFM in this setting must rely on future, larger, prospective studies in various paediatric conditions. Similarly formal evaluation of its efficacy as a screening tool for detecting seizures in the general paediatric ward will need to come from simultaneous comparisons with continuous EEG video telemetry which is still considered the ‘gold-standard’ for monitoring seizures. For pragmatic reasons we applied to our study population a background voltage grading system described for term neonates because there are hitherto no reports providing normative background aEEG voltages in older children. While normal background aEEG voltages may be expected to increase between the neonatal period and early childhood, implying that slightly higher background voltage thresholds may be more applicable to older infants and children, the same 5 and 10 microvoltage thresholds have nevertheless been used in adult studies [7].

Our survey showed that CFM was not currently being used in any other general paediatric wards in our large geographical region. Because nearly all of these hospitals also had no access to out-of-hours cEEG, we consider that CFM could have a useful role in bridging such gaps in clinical service provision, not least because of its accessibility, relative ease of its application, and portability.

CFM technology can have a useful role in any setting with a high prevalence of brain injury or neurological morbidity. Newer digital monitors readily permit real-time bedside evaluation of dynamically-evolving brain function. CFM augments clinical monitoring and so may potentially be able to facilitate the timely diagnosis and treatment of young infants as well as neonates. Through our small observational study, we have demonstrated that CFM use is feasible on the general paediatric ward and we offer proof of principle that it can be used to detect and document seizures in this setting. This facility may be particularly helpful out of hours, when there is no ready access to cEEG, or to a paediatric neurologist able to confirm or refute the presence of seizures. Many parents now own smartphones which allow video recording and thereby the ability to capture abnormal movements occurring during their child's admission. We suggest that retrospective review of a timed video record coupled with the accompanying easily-accessed date and time-stamped digital aEEG stored on the cerebral function monitor, may provide valuable information to clinicians when formal video EEG is unavailable.

Particular challenges for CFM use in older infants and children in the general paediatric setting include the practical fixation of the electrodes, and the ongoing training required for multiple attendant paediatric medical and nursing personnel. For CFM to assist clinical diagnosis, then bedside clinicians must be trained and confident to interpret aEEG correctly so that they identify electrical seizures and gross background abnormalities and can properly recognise aEEG artefacts. Regular audits of trace quality and interpretation are essential for quality assurance. Areas for future research should include the establishment of the normative aEEG backgrounds at various ages, and a better understanding of the value of CFM within the various paediatric conditions causing neurological morbidity.

Acknowledgements: We are grateful to the consultant paediatricians, especially Drs Mary-Anne Morris, Bina Mukhtyar, and Ruchi Arora for supporting this project and thank Kathryn Desira for supporting the training of the paediatric nurses. We also thank Lisa Chalkley, R&D Services Manager, and Vimmi Lutchmeah-Beeharry, Information Governance Manager, for their helpful advice.

Author contributions: PC conceived the idea for this project, assisted with training of medical staff, and designed the survey. SS and VK supervised the introduction of CFM on Buxton Children's Ward; SS conducted the telephone survey; SD provided practical CFM training and support for the paediatric nurses; PC and DS reviewed the aEEG traces; VK and PC wrote the first manuscript draft. All authors contributed to manuscript revision and approve of the final version. PC is guarantor.

Competing interests/ Conflict of interest statement: SD gratefully received a generous travel bursary from Natus Inc. which enabled presentation of this work in abstract form at the JENS Congress, Budapest, September 2015. Natus Inc. had no other involvement with this study. There are no other competing interests and no conflict of interests to declare in relation to this work.

Funding Statement: No specific funding was received for this study.

Ethics approval: This study was reviewed by our NHS Hospital Trust R+D Manager and, as a service evaluation, was judged not to require formal ethics approval under current UK National Research Ethics Service guidance. Our Trust's Caldicott Approval Group gave permission for external peer review of the anonymised aEEG traces.

Patient Consent: Consent was obtained for publication of the photograph of the infant used in our CFM Parent Information leaflet (Supporting Information File).

REFERENCES:

1. Al Naqeeb N, Edwards AD, Cowan FM, Azzopardi D (1999) Assessment of neonatal encephalopathy by amplitude-integrated electroencephalography. *Pediatrics* 103:1263–1271
2. Maynard D, Prior PF, Scott DF (1969) Device for continuous monitoring of cerebral activity in resuscitated patients. *Brit Med J* 4:545–546. doi: 10.1136/archdischild-2013-305206
3. Murdoch-Eaton D, Darowski M, Livingston J (2001) Cerebral function monitoring in paediatric intensive care: useful features for predicting outcome. *Dev Med Child Neurol* 43:91–96
4. Ponnusamy V, Beach RC, Blake J, Clarke P (2010) A case of near-drowning; a case for routine cerebral monitoring. *Acta Paediatrica* 99:463–466. doi: 10.1111/j.1651-2227.2009.01556.x
5. Ponnusamy V, Nath P, Bissett L, Willis K, Clarke P (2010) Current availability of cerebral function monitoring and hypothermia therapy in UK neonatal units. *Arch Dis Child Fetal & Neonatal Ed* 95:383–384. doi: 10.1136/adc.2009.181578
6. Shah DK, Wusthoff CJ, Clarke P, Wyatt JS, Ramaiah SM, Dias RJ, Becher JC, Kapellou O, Boardman JP (2014) Electrographic seizures are associated with brain injury in newborns undergoing therapeutic hypothermia. *Arch Dis Child Fetal Neonatal Ed* 99:F219–24. doi: 10.1136/archdischild-2013-305206
7. Tian G, Qin K, Wu YM, Ji Z, Wang JX, Pan SY (2012) Outcome prediction by amplitude-integrated EEG in adults with hypoxic ischemic encephalopathy. *Clin Neurol Neurosurg*. 114:585-9. doi: 10.1016/j.clineuro.2011.12.011.
8. Toet MC, Hellström-Westas L, Groenendaal F, Eken P, de Vries LS (1999) Amplitude integrated EEG 3 and 6 hours after birth in full term neonates with hypoxic-ischaemic encephalopathy. *Arch Dis Child Fetal Neonatal Ed* 81:F19–23.

9. Toet MC, van der Meij W, de Vries LS, Uiterwaal CS, van Huffelen KC (2002)
Comparison between simultaneously recorded amplitude integrated
electroencephalogram (cerebral function monitor) and standard
electroencephalogram in neonates. *Pediatrics* 109:772–779

Table 1 Clinical characteristics and findings for seven infants who underwent cerebral function monitoring on the children's ward

Case No	Age at admission	Duration of CFM Recording (hours)	Clinical Presentation	Background voltage on CFM	Seizure activity on CFM	Conventional EEG findings	Imaging findings	Final clinical diagnosis and notes
1	5 days	17.6	Clonic movements of right arm and leg	Normal	Yes - Frequent	Not done	USS and MRI/MRV: abnormal	Left thalamic haemorrhage with intra-ventricular extension secondary to dural sinus thrombosis of great vein of Galen
2	13 days	12.9	Multiple episodes of jerky limb movements with rolling of eyeballs and flickering of eyelids; increasing head size	Severely abnormal (BS)	Yes - Frequent, though on a background of persistent BS (with frequent bursts)	BS plus multifocal epileptiform discharges	MRI: Focal WM oedema of right hemisphere, especially right parietal and frontal lobes	Epileptic encephalopathy: Ohtahara syndrome
3	14 days	34.1	Abnormal brief movements of hands and arms	Normal	Yes - Sporadic	Normal	No imaging	Focal epilepsy associated with inherited deletion of 16p13.3,16p11.2
4	1 month	20.2	Apnoeic episode at home requiring CPR	Normal	None	Normal	No imaging	Apparent life-threatening event secondary to rhinovirus-positive bronchiolitis
5	2 months	7.9	Recurrent staring episodes associated with	Normal	None	Normal	Contrast enema showed intussusception	Intussusception (diagnosed after

6	3 months	9.5	pallor, floppiness and drowsiness Frequent episodes of left arm twitching with eye blinking ?focal seizures	Normal	Yes - Sporadic	Right central epileptiform discharges	MRI: Multiple bilateral linear T1 WM hyperintensities. Abnormal thickened cortex and adjacent WM in the medial right frontal lobe. Subependymal right frontal horn nodule.	subsequent passage of mucousy/bloody stool) Tuberous sclerosis
7	5 months	9.8	Ex-23 week gestation infant with post-haemorrhagic hydrocephalus and ventricular reservoir; recent-onset abnormal eye movements	Normal	No	Not done	No imaging	Normal

BS, burst-suppression; CFM, cerebral function monitoring; CPR, cardio-pulmonary resuscitation; MRI, magnetic resonance imaging; MRV, magnetic resonance venography; USS, ultrasound scan; WM, white matter

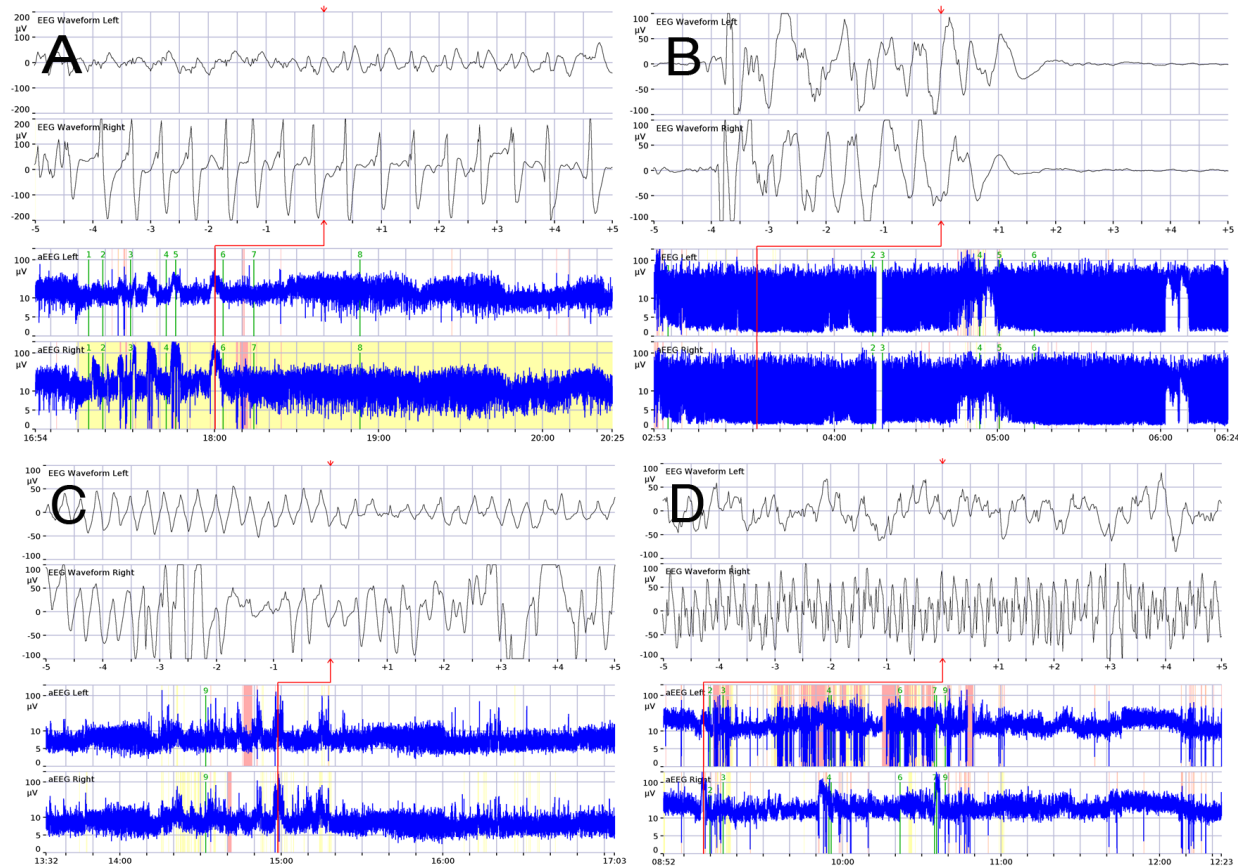


Fig 1 Screenshots from cerebral function monitoring in four infants with seizures. For each panel, the upper two rows show left and right hemispheric raw EEG over 10 s periods and the lower two rows show the corresponding hemispheric amplitude-integrated traces over 3.5 h periods. (A) Case 1: Frequent seizures on a normal background; (B) Case 2: prolonged burst-suppression (a severely abnormal pattern) with seizures at ~05:00h and 06:00h; (C) Case 3: sporadic brief seizures on a normal background, raw EEG shown at ~15:00h; (D) Case 6: Sporadic brief seizures on a normal background.