



# The prevalence of femoroacetabular impingement anatomy in Division 1 aquatic athletes who tread water

Joanna L. Langner <sup>1\*</sup>, Marianne S. Black<sup>1,2</sup>, James W. MacKay<sup>1,3</sup>,  
Kimberly E. Hall <sup>4</sup>, Marc R. Safran<sup>4</sup>, Feliks Kogan<sup>1</sup> and Garry E. Gold<sup>1,4,5</sup>

<sup>1</sup>Department of Radiology and

<sup>2</sup>Department of Mechanical Engineering, Stanford University, 450 Serra Mall, Stanford, CA 94305, USA,

<sup>3</sup>Department of Radiology, Cambridge University, The Old Schools, Trinity Ln, Cambridge CB2 1TN, UK,

<sup>4</sup>Department of Orthopaedic Surgery and

<sup>5</sup>Department of Bioengineering, Stanford University, 450 Serra Mall, Stanford, CA 94305, USA.

\*Correspondence to: J. L. Langner. E-mail: jlangner@stanford.edu

Submitted 16 December 2019; revised version accepted 22 January 2020

## ABSTRACT

Femoroacetabular impingement (FAI) is a disorder that causes hip pain and disability in young patients, particularly athletes. Increased stress on the hip during development has been associated with increased risk of cam morphology. The specific forces involved are unclear, but may be due to continued rotational motion, like the eggbeater kick. The goal of this prospective cohort study was to use magnetic resonance imaging (MRI) to identify the prevalence of FAI anatomy in athletes who tread water and compare it to the literature on other sports. With university IRB approval, 20 Division 1 water polo players and synchronized swimmers (15 female, 5 male), ages 18–23 years (mean age  $20.7 \pm 1.4$ ), completed the 33-item International Hip Outcome Tool and underwent non-contrast MRI scans of both hips using a 3 Tesla scanner. Recruitment was based on sport, with both symptomatic and asymptomatic individuals included. Cam and pincer morphology were identified. The Wilcoxon Signed-Rank/Rank Sum tests were used to assess outcomes. Seventy per cent (14/20) of subjects reported pain in their hips yet only 15% (3/20) sought clinical evaluation. Cam morphology was present in 67.5% (27/40) of hips, while 22.5% (9/40) demonstrated pincer morphology. The prevalence of cam morphology in water polo players and synchronized swimmers is greater than that reported for the general population and at a similar level as some other sports. From a clinical perspective, acknowledgment of the high prevalence of cam morphology in water polo players and synchronized swimmers should be considered when these athletes present with hip pain.

## INTRODUCTION

Femoroacetabular impingement (FAI) is a disorder that causes hip pain and disability in young patients, particularly athletes and highly active individuals [1, 2]. FAI syndrome is defined as ‘a motion-related clinical disorder of the hip’ with the primary symptoms of ‘motion-related or position-related pain in the hip or groin’ [3]. FAI is a leading cause of labral tears and potentially hip osteoarthritis (OA) [4–6]. Anatomical changes in the hip, including cam and pincer morphology revealed by radiographs and magnetic resonance imaging (MRI), have been identified as

contributing to FAI and OA, yet the factors that contribute to these morphological changes are still not understood [7, 8]. Cam morphology is felt to be the result of abnormal forces on the proximal femoral physis during development, however the types of forces that may cause cam morphology have not been elucidated [9–11].

Athletes are considered at-risk populations with high prevalences of FAI anatomy. In past research, it has been well documented that athletes have a higher prevalence of FAI anatomy than the general population [6, 12–24]. Soccer players, basketball players and ice hockey players

have been reported having a high prevalence of abnormal angles (alpha angle  $>55$  degrees) indicative of FAI [16, 18, 22]. However, while there is some evidence regarding weight bearing/axial loading, the effects from rotational forces have received limited focus. Water polo and synchronized swimming require extensive eggbeater kicking during development and training as an adolescent to effectively participate in these activities at the collegiate level. The eggbeater kick (Supplementary Video S1), done while treading water, increases stress on the hip due to continued rotational motion with potential conflict between the femur and the acetabulum. This motion done throughout development might place athletes at risk for development of cam and pincer morphology.

Past research on treading water has focused on the hydrodynamic forces behind it, knee extension and flexion and other kinematics behind the motion [25–29]. The goal of this prospective cohort study was to use MRI to identify whether athletes who tread water have an increased prevalence of cam or pincer morphology. If so, this would suggest that treading water may contribute to the development of FAI anatomy. We hypothesized that the prevalence of cam and pincer morphology in Division 1 water polo players and synchronized swimmers would be greater than that of the general population and comparable with other sports.

## MATERIALS AND METHODS

### Subjects

Twenty National Collegiate Athletic Association (NCAA) Division 1 varsity men's and women's water polo players and synchronized swimmers (15 female, 5 male), ages 18–23 years (mean  $20.7 \pm 1.4$ ), were recruited from 2 January 2019 to 21 March 2019. The participants included five male water polo players, eight female water polo players and seven female synchronized swimmers. Prior to participating, all subjects provided informed consent according to the University Institutional Review Board. Inclusion criteria required the individuals to be a Division 1 varsity athlete in either water polo or synchronized swimming and actively participating in their respective sport. Exclusion criteria were any previous hip surgery. In addition, all subjects completed a questionnaire unique to this study detailing how many average hours per week they tread water, how many years they have been in a sport that requires them to tread water, whether they have been diagnosed or treated for a hip injury, whether they have had surgery on either hip, and whether they have experienced hip pain at any point in their life. Lastly, participants

completed the 33-item International Hip Outcome Tool (iHOT-33) which is a patient-reported measure designed to evaluate hip-related quality of life [30]. The iHOT-33 is commonly used in studies looking at FAI [31]. Participants were recruited based on sport, resulting in both symptomatic and asymptomatic athletes being included in the study.

### MRI scans

Each participant underwent a non-contrast unilateral hip MRI scan on each of their two hips (2 scans total) using a whole-body 3 Tesla MRI scanner (GE Healthcare, Waukesha, WI, USA) with a 16-channel flexible phased-array-receive-only coil (NeoCoil, Pewaukee, WI, USA). The scanning protocol was 20 min per hip and consisted of five MRI sequences (Table 1). To allow for consistency and to include the proximal femur in the image, the greater trochanter was palpated as a landmark and the coil was placed two inches below the iliac crest [32].

### Image assessment for cam or pincer morphology

The RadiAnt DICOM viewer (Medixant, Inc., Poznan, Poland) was used to analyze the images for each participant.

#### Definition of cam morphology

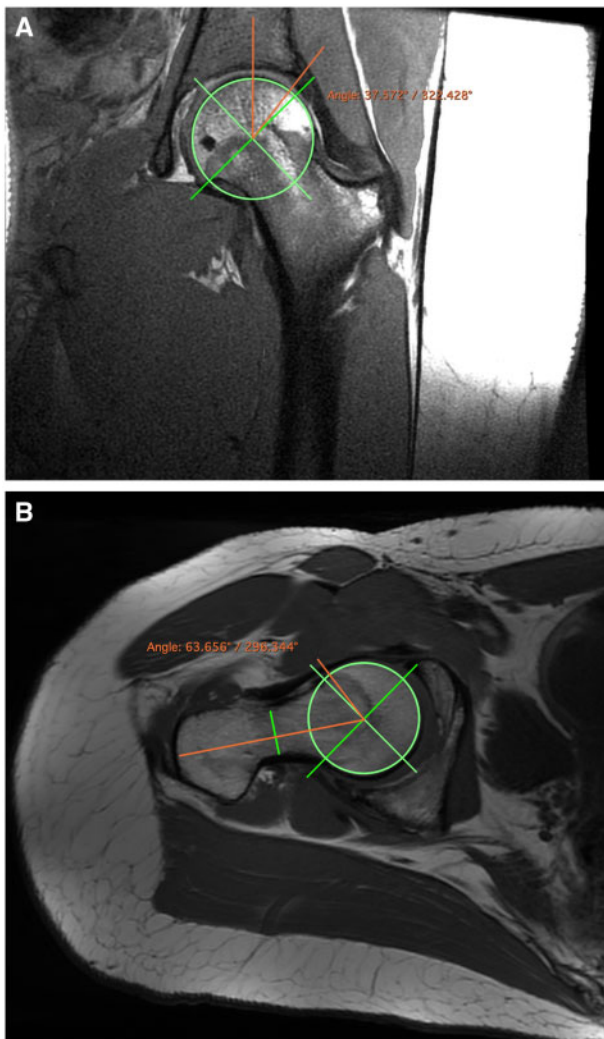
Cam morphology is identified using the measurement of the alpha angle as described by Nötzli *et al.* [36]. On an oblique slice parallel to and through the center of femoral neck and head using the T1 FSE sequence, this angle was determined by drawing a circle around the midslice of the femoral head then placing a line bisecting the circle along the longitudinal axis of the femoral neck, and a line from the mid circle to where the femoral head protrudes out of the circle along the anterior margin of the femur (Fig. 1) [8]. An alpha angle above 55 degrees was considered abnormal [8, 37].

#### Definition of pincer morphology

Pincer morphology is identified using the measurement of the lateral center-edge angle (LCEA). A fused fat and water-only coronal PD IDEAL FSE image was used to visualize the boundaries of the acetabulum. The LCEA was determined by drawing a circle around the midslice of the femoral head, then placing a vertical line through the center of the femoral head. Another line is drawn through the center of the femoral head and ends at the edge of the lateral acetabular rim (Fig. 1) [38]. Abnormal LCEA for acetabular dysplasia, representing instability in the hip, are those  $<25$  degrees. Abnormal LCEA for acetabular over coverage seen in pincer morphology is  $>39$  degrees [38].

**Table I. Protocol information with parameters**

Scan	Scan plane	TR/TE	Field of view (cm)	Imaging matrix	Acceleration factor	Slice thickness (mm)	Scan time (min:s)
PD IDEAL FSE [15, 33, 34]	Coronal	1910/26.4 ms	20	408 × 320	2 × 1	3.0	04:03
T2 DESS [34, 35]	Sagittal	14.6/4.9/24.3 ms	18	384 × 320	None	1.5	05:55
T1 FSE [6, 32]	Oblique	822/9.4 ms	24	416 × 320	2 × 1	3.5	02:19
3D ZTE	Coronal	290/16 $\mu$ s	18	224 × 224	None	1.3	02:05
PD IDEAL FSE	Axial (around the knee)	1800/12.5 ms	18	256 × 192	None	3.0	00:47



**Fig. 1.** (A) Axial oblique T1-weighted image of the central slice from the right hip used to determine the alpha angle. (B) Coronal image of a fusion of fat and water-only IDEAL-FSE scans from the left hip used to determine the LCEA.

For this study, we focused on high LCEA (>39 degrees) that relates to acetabular over coverage, implicated in pincer impingement. This contributes to an underestimation of pincer morphology. It is important to note that pincer identification is usually measured using plain radiographs of the pelvis. Other radiographic signs of pincer impingement, such as cranial retroversion, or crossover sign, were not assessed with this MRI methodology. However, to avoid unnecessary radiation risk to these young volunteers, MRI was selected as the modality for assessment of FAI anatomy, despite its limitations for measurement of lateral CEA. The imaging protocol was chosen to allow for the alpha angle and LCEA to be measured from tomographic images with consideration of scan time limitations.

The alpha angle and LCEA were measured by two board-certified musculoskeletal radiologist and a student trained by those radiologists. The midslice for both alpha angle and LCEA were chosen based on the measured locations of the superior and inferior most visualized parts of the femoral head and neck.

#### Labral tears

Labral tears were identified by two board-certified musculoskeletal radiologist. These were scored using the Scoring Hip Osteoarthritis Using MRI (SHOMRI) semi-quantitative grading scale [39].

#### Repeated measures

A repeated measures analysis was used. Three researchers scored the alpha angles for each participant, and two researchers scored the LCEA and labral tears. The angle scores were then averaged, and the average values were used in the analyses.

### Statistical analysis

Pearson correlations were calculated between the alpha angle/LCEA and the estimated number of lifetime hours participants treaded water. Subjects with an abnormally low LCEA (<25 degrees) were dropped in analyses on LCEA to remove the impact of hip dysplasia. Right and left hips were treated as separate for analyses. Lifetime hours treading water was calculated by multiplying the individually reported average number of hours per week spent treading water by 52 weeks in a year and multiplying this by the number of years the individual has spent in a sport which requires them to tread water. A Pearson correlation was also calculated with years treading water to account for the likelihood that the reported average number of hours treading water per week was not representative of the number of hours spent treading water per week for a participant's entire athletic career.

A Wilcoxon Rank Sum Test was used in MATLAB (Mathworks, Inc.) to assess non-parametric data. A Wilcoxon Signed-Rank Test was used to compare right and left hips of participants for alpha angle and LCEA. Significant differences in alpha angle, LCEA, iHOT-33 scores and labral tears between different sports, sexes, asymptomatic/symptomatic individuals or hips (Right/Left) were determined by a  $P$ -values < 0.05. A Bonferroni's correction was not done to account for multiple comparisons based on the exploratory nature of the study [40]. Data on alpha angles, LCEA and labral tears were compared with the results from past research using a table with study specifications. The interobserver variability for alpha angle and LCEA measurements, as well as labral tear assessments was calculated using a Coefficient of Variation (CV).

### RESULTS

All subjects completed the imaging protocol with the exception of subject 17 who only completed the scans for the left hip due to discomfort with being in the MRI scanner. Seventy per cent (14/20) of subjects reported having pain in their hips at some point in their life, yet only 15% (3/20) sought evaluation or treatment for hip pain. Cam morphology was identified in 67.5% (27/40) of hips and 22.5% (9/40) demonstrated pincer morphology. Furthermore, Researcher 1 reported 52.5% (21/40) of hips had evidence of a labral tear, and Researcher 2 reported 55.0% (22/40) (Table II). Fifteen per cent (6/40) of hips had a LCEA <25 degrees and were dropped in analyses on LCEA to remove the impact of hip dysplasia. The interobserver variability for alpha angles had a CV of 22.2%. For LCEA it was 1.5%, and for labral tears it was 3.3%.

In comparing differences between sports (water polo versus synchronized swimming) or sexes (male versus female) on the basis of alpha angle, LCEA, iHOT-33 scores or labral tears, there were seven significant differences. There was a statistically significant difference in males versus females for alpha angle ( $P=0.030$ ) with males having an average of  $61.8^\circ (\pm 6.5)$  and females average  $56.6^\circ (\pm 6.4)$ . Also for alpha angle, there was a statistically significant difference in right versus left hips for synchronized swimming (synchro) ( $P=0.031$ ), with the right hip having an average of  $55.3^\circ (\pm 7.9)$  and the left hip having an average of  $60.4^\circ (\pm 6.5)$ . There was also a statistically significant difference between the alpha angle for right versus left hips in all participants ( $P=0.038$ ), with the right hip having an average of  $56.5^\circ (\pm 6.0)$  and the left hip having an average of  $59.3^\circ (\pm 7.3)$ . There was a statistically significant difference between the LCEA for right versus left hips in females ( $P=0.031$ ), with the right hip having an average of  $33.0^\circ (\pm 6.2)$  and the left hip having an average of  $34.2^\circ (\pm 6.5)$ . There was also a statistically significant difference between the LCEA for right versus left hips in all participants ( $P=0.021$ ), with the right hip having an average of  $31.6^\circ (\pm 6.3)$  and the left hip having an average of  $34.4^\circ (\pm 6.6)$ .

For iHOT-33 scores there is a statistically significant difference for male versus female ( $P=0.045$ ), with males having a mean value of  $81.0 (\pm 10.0)$  and females having a mean value of  $90.3 (\pm 16.4)$ . There was also a statistically significant difference for iHOT-33 scores for symptomatic versus asymptomatic individuals ( $P=0.002$ ), with symptomatic having a mean value of  $83.3 (\pm 16.3)$  and asymptomatic having a mean value of  $99.0 (\pm 1.0)$ . For all other comparisons, no statistically significant differences between sports, sexes, asymptomatic/symptomatic individuals or hips was found on the basis of alpha angle, LCEA, iHOT-33 scores or labral tears. Lifetime hours treading water were not significantly correlated with alpha angle/LCEA (alpha angle  $P=0.102$ , LCEA  $P=0.707$ ). Years treading water were also not significantly correlated with alpha angle/LCEA (alpha angle  $P=0.556$ , LCEA  $P=0.165$ ).

### DISCUSSION

This study used MRI to evaluate the prevalence of FAI anatomy in athletes who tread water. We found that there is a higher prevalence of cam morphology in the water polo and synchronized swimming cohorts (67.5%) compared with published reports of the general population and asymptomatic groups (Table III). Published results on other cohorts had similar findings for cam morphology prevalence such as soccer players (64.2%) and general athletes (54.8%) [15, 16]. However, there are still some sports with reports of even higher prevalences like basketball



**Table II. Results for alpha angle, LCEA and labral tears**

Target	WWP	MWP	Synchro	Female	All
% Abnormal alpha angle	56.3% (9/16)	90% (9/10)	64.3% (9/14)	60.0% (18/30)	67.5% (27/40)
% Abnormal LCEA	31.3% (5/16)	30.0% (3/10)	7.1% (1/14)	20.0% (6/30)	22.5% (9/40)
% Labral Tears: Reader 1	43.8% (7/16)	80.0% (8/10)	42.9% (6/14)	43.3% (13/30)	52.5% (21/40)
% Labral Tears: Reader 2	50.0% (8/16)	80.0% (8/10)	42.9% (6/14)	46.7% (14/30)	55.0% (22/40)
Alpha R	55.3 <sup>a</sup> (±3.1)	60.1 <sup>a</sup> (±6.2)	55.3 <sup>a</sup> (±7.9)	55.3 <sup>a</sup> (±5.6)	56.5 <sup>a</sup> (±6.0)
Alpha L	55.5 <sup>a</sup> (±7.1)	63.5 <sup>a</sup> (±7.1)	60.4 <sup>a</sup> (±6.5)	57.8 <sup>a</sup> (±7.1)	59.3 <sup>a</sup> (±7.3)
LCEA R	34.2 (±5.3)	31.5 (±7.5)	28.7 (±6.1)	33.0 (±6.2)	31.6 (±6.3)
LCEA L	36.8 (±4.9)	35.3 (±7.7)	31.1 (±7.0)	34.2 (±6.5)	34.4 (±6.6)
iHOT-33	90.1 (±18.2)	81.0 (±10.0)	90.6 (±15.5)	90.3 (±16.4)	88.0 (±15.4)
Lifetime hours TR	8983 (±3264)	8892 (±2163)	11 254 (±2455)	10 043 (±3047)	9755 (±2844)

Per cent of participants with FAI anatomy and labral tears, and average alpha angles, LCEA's, iHOT-33 scores and lifetime hours treading water (TR) found (with standard deviations) for different groups.

<sup>a</sup>The average angle is abnormal and signifies FAI anatomy.

MWP, men's water polo; Synchro, synchronized swimming; WWP, women's water polo.

(89%) and ice hockey (75%) [18, 22]. This study is unique because it focuses on aquatic athletes and the impact of treading water. Past literature has documented prevalence of FAI anatomy largely in land-based sports [16, 18, 22]. Since most data suggest the cam deformity occurs at the proximal femoral physis, many hypothesize that the forces affecting this physis in adolescent athletes are the result of ground contact forces. However, the high prevalence of cam morphology in this study, where water polo players and synchronized swimmers have limited ground contact, suggests that treading water may contribute to the development of cam morphology.

Pincer morphology was reported in a similar prevalence to soccer, but less than some other sports and symptomatic populations. Note that this study likely underestimates the prevalence of pincer morphology which may contribute to the observed lack of trend for LCEA (see Limitations). Labral tears were also found to be at a lower or comparable prevalence to other athletes and asymptomatic populations. This is likely influenced by this study's relatively young cohort. The high number of male water polo players with labral tears may be due to the small sample size.

As would be expected, athletes who reported hip symptoms had a statistically significantly lower iHOT-33 score than the asymptomatic group. This validates the use of the iHOT-33 as being able to distinguish between symptomatic and asymptomatic hips. The significantly lower

iHOT-33 score for males compared with females requires further analysis. The statistically significant higher LCEA for the left hip versus the right hip in females and all participants is consistent with past research [41]. The statistically significant higher alpha angle for the left hip versus the right hip in synchro and all participants, as well as the significantly higher alpha angle in males versus females requires further analysis. Synchronized swimming does not have any notable sport-specific demands of one hip. However, in water polo many athletes have a dominant side for performing the shooting motion which may contribute to asymmetry, but requires further analysis. In addition, there was no statistically significant Pearson correlation between alpha angle/LCEA and lifetime hours treading water, which may be due to the lack of an accurate measurement for lifetime hours treading water or recall bias.

### Limitations

This study has several limitations. The largest limitation is the high interobserver variability bias for the alpha angle, which has been seen before in prior studies. In addition, the lateral CEA is usually measured using plain radiographs of the pelvis, yet this study only used MRI. The lateral aspect of the acetabulum on the MRI may not correlate with the shadow of the lateral aspect of the acetabulum, especially from an AP Pelvis radiograph, where the beams are divergent and the edge of the acetabulum is based on a

Table III. Study results compared with past literature

Paper	Population studied	Modality	Per cent female	Age range	% Hips with alpha angle > 55°	% Bilateral alpha angle > 55°	Mean alpha angle (°)	% Hips with LCEA > 39°	% Bilateral LCEA > 39°	Mean LCEA (°)	% Hips with labral tears	% Bilateral labral tear
This study	Athletes (water polo/synchro)	MRI	75	18–23	Female: 60.0% (18/30) Male: 90.0% (9/10) All: 67.5% (27/40)	Female: 40.0% (6/15) Male: 80.0% (4/5) All: 50.0% (10/20)	Female: 56.6 ± 6.4 Male: 61.8 ± 6.5 All: 57.9 ± 6.8	Female: 20.0% (6/30) Male: 30.0% (3/10) All: 22.5% (9/40)	Female: 0.0% (0/15) Male: 20.0% (1/5) All: 5.0% (1/20)	Female: 32.9 ± 6.3 Male: 33.4 ± 7.5 All: 33.0 ± 6.5	Female: R1: 43.3% (13/30) R2: 46.7% (14/30) Male: R1: 80.0% (4/5) R2: 80.0% (8/10) All: R1: 52.5% (21/40) R2: 55.0% (22/40)	Female: R1: 26.7% (4/15) R2: 26.7% (4/15) Male: R1: 80.0% (4/5) R2: 80.0% (8/10) All: R1: 40.0% (8/20) R2: 40.0% (8/20)
Gerhardt <i>et al.</i> [16]	Athletes (soccer)	Radiography	21	n/a	Female: 50% (10/20) Male: 68% (51/75) All: 64.2% (61/95)	Female: 90% (9/10) Male: 76.5% (39/51) All: 78.7% (48/61)	Female: 52.9 Male: 65.6 All: n/a	Female: 10% (2/20) Male: 26.7% (20/75) All: 23.2% (22/95)	n/a	n/a	n/a	n/a
Siebenrock <i>et al.</i> [22]	Athletes (basketball)	MRI	0	9–25	89% (41/46)	n/a	All: 57.8 ± 10.6	n/a	n/a	n/a	n/a	n/a
Philippon <i>et al.</i> [18]	Athletes (ice hockey)	MRI	n/a	10–18	75% (61 participants)	n/a	n/a	n/a	n/a	n/a	n/a	n/a
Bisciotti <i>et al.</i> [14]	Athletes (symptomatic)	Radiography	9.1	25.86 ± 3.21	88.6% (39/44)	70.4% (31/44)	Right: 64.87 ± 11.53 Left: 65.97 ± 11.12	13.6% (6/44)	n/a	38.52 ± 2.38	n/a	n/a
Frank <i>et al.</i> [15]	Mixed asymptomatic (review)	MRI/radiography	43	n/a	Athletes: 54.8% General population: 23.1% All: 37%	n/a	All: 54.1 ± 5.1	Athletes: 49.5% All: 67%	n/a	31.2 ± 4.9	Athletes: 65.4% All: 68.1%	n/a

(continued)

Table III. (continued)

Paper	Population studied	Modality	Per cent female	Age range	% Hips with alpha angle > 55°	% Bilateral alpha angle > 55°	Mean alpha angle (°)	% Hips with LCEA > 39°	% Bilateral LCEA > 39°	Mean LCEA (°)	% Hips with labral tears	% Bilateral labral tear
Allen <i>et al.</i> [12]	Symptomatic	Radiography	27	16–55	88.9% (201/226)	77.8% (88/113)	Female: 62.1 ± 9.6 Male: 69.1 ± 10.4 All: 67.1 ± 10.6	48.8% (98/201)	n/a	34.8	n/a	n/a
Ranawat <i>et al.</i> [19]	Symptomatic	Radiography	56	13–61	72%	n/a	Female: 68.1 Male: 88	81%	n/a	n/a	n/a	n/a
Hack <i>et al.</i> [6]	Asymptomatic	MRI	55.5	21–50	Female: 5.4% Male: 24.7% All: 14.0% (400 Hips studied)	3.5%	n/a	n/a	n/a	n/a	n/a	n/a
Heery <i>et al.</i> [17]	Mixed athletes (review)	MRI/X-ray	n/a	n/a	n/a	n/a	n/a	n/a	n/a	n/a	Asymptomatic athletes: 33–54% Symptomatic athletes: 20%	n/a
Ayeni <i>et al.</i> [13]	Athletes (ice hockey)	MRI	82	16–30	n/a	n/a	n/a	n/a	n/a	n/a	60% (12/20)	n/a
Schmitz <i>et al.</i> [21]	Asymptomatic	MRI	23.8	27–43	n/a	n/a	n/a	n/a	n/a	n/a	R1: 85.7% (36/42) R2: 80.9% (34/42)	n/a
Register <i>et al.</i> [20]	Asymptomatic	MRI	40	15–66	n/a	n/a	n/a	n/a	n/a	n/a	69% (31/45)	n/a

Observed prevalence of FAI anatomy based on cam and pincer morphology, and labral tears, compared with estimates from past research on athletes, asymptomatic, symptomatic and mixed groups. Note: For Siebenrock *et al.* the 12 o'clock estimate was used for alpha angle distribution. The Frank *et al.* study is a review with many of the studies included for comparison in this table, and the reported average CEA is for the lateral CEA, not anterior. For the Ranawat *et al.* paper the combined FAI type was added to the alpha and CEA angle group since it applies to both. R1 indicates reader 1 and R2 indicates reader 2.

shadow projection of the bone. Thus, the precision of the LCEA may not correlate with that of a plain radiograph. Individuals can have pincer morphology yet still have a normal LCEA, as seen on radiographs as cranial retroversion, or crossover sign. Therefore, this study likely underestimates the prevalence of pincer morphology and it cannot be definitively said that the prevalence of pincer morphology is not also greater in water polo players and synchronized swimmers than in the general population. There are many ways to assess cam and pincer morphology, and the imaging protocol used for this study has inherent limitations due to limited scan time and an effort to avoid unnecessary radiation risk. In the future, it would be important to assess which participants were single-sport versus multi-sport athletes growing up, because having a history of axial-loading sports could impact cam morphology prevalence and could confound the results.

Water polo players and synchronized swimmers also participate in cross training on land, and thus are subjected to ground/axial forces. In addition, muscular contraction across the hip joint does produce some joint reaction axial compressive force, yet the same is true for other athletes and sports that are not associated with a higher prevalence of cam morphology. Thus, while the vast majority of the forces on their hips are rotational without axial forces, they are not without some ground and joint reaction axial forces as well.

Further limitations include a small sample size with primarily females and the lack of a control group. The numbers for the prevalence of abnormal alpha angles, LCEA angles and labral tears in both the athletic and general populations in the literature are not consistent, and therefore these historical controls are not as ideal a group as age matched athletic controls undergoing our strict imaging protocol. For the purpose of analysis, because subject 17 only had data for the left hip, the data for their right hip has been assumed to be the same as the left hip, potentially biasing the data for males. Lastly, no physical exam of the hip was conducted, impeding the ability to precisely determine hip functionality and real time pain assessment.

### CONCLUSION

In this preliminary study, water polo players and synchronized swimmers were found to have a higher prevalence of cam morphology than the general population and asymptomatic individuals, and have a similar prevalence as some land sports. Cam morphology is often thought to be the result of abnormal forces on the femoral head physis during development, and this study suggests that treading water may contribute to the development of cam morphology as there is limited ground contact in these sports, though there certainly are some axial joint reaction forces. From a

clinical perspective, acknowledgment of the high prevalence of cam morphology in water polo players and synchronized swimmers should be considered when athletes who tread water present with hip pain.

### SUPPLEMENTARY DATA

Supplementary data are available at *Journal of Hip Preservation Surgery* online.

### ACKNOWLEDGEMENTS

The authors would like to thank the Stanford Athletics varsity water polo and synchronized swimming teams and coaches for allowing us to use them as subjects.

### FUNDING

This work was supported by a Major Grant from the Stanford University Vice Provost for Undergraduate Education as part of the Human Biology Honors Program. Support also came from GE Healthcare, and the National Institutes of Health (EB002524, AR06206).

### CONFLICT OF INTEREST STATEMENT

One or more of the authors has declared a potential conflict of interest. J.M. received honoraria from GE Healthcare. M.R.S. is a consultant for Medacta, Anika Therapeutics (both current), Fellowship Support for Smith & Nephew, Conmed Linvatec, Ossur, Biomet (only Smith & Nephew current) and receives research support (not related to this study) from Ferring, Conmed Linvatec, Smith & Nephew (none current), and royalties from Smith & Nephew, Stryker, DJO, and was a speaker for Medacta, Smith & Nephew, Conmed Linvatec (Conmed not current). M.S.B. is a shareholder and co-founder of Arbutus Medical, Inc. G.E.G. receives research support from GE Healthcare and is a consultant for Canon Med.

### REFERENCES

1. Byrd JW. Femoroacetabular impingement in athletes, part 1: cause and assessment. *Sports Health* 2010; **2**: 321–33.
2. Smolders JMH, Speirs AD, Frei H *et al*. Higher patient activity level and subchondral stiffening in asymptomatic cam femoroacetabular impingement subjects. *J Hip Preserv Surg* 2018; **5**: 259–66.
3. Griffin DR, Dickenson EJ, O'Donnell J *et al*. The Warwick Agreement on femoroacetabular impingement syndrome (FAI syndrome): an international consensus statement. *Br J Sports Med* 2016; **50**: 1169–76.
4. Dooley PJ. Femoroacetabular impingement syndrome: nonarthritic hip pain in young adults. *Can Fam Physician* 2008; **54**: 42–7.
5. Elmslie RC. Remarks on AETIOLOGICAL FACTORS IN OSTEO-ARTHRITIS OF THE HIP-JOINT. *Br Med J* 1933; **1**: 1–46.1.



6. Hack K, Di Primio G, Rakhra K *et al.* Prevalence of cam-type femoroacetabular impingement morphology in asymptomatic volunteers. *J Bone Joint Surg Am* 2010; **92**: 2436–44.
7. Murray RO. The aetiology of primary osteoarthritis of the hip. *Br J Radiol* 1965; **38**: 810–24.
8. Riley GM, McWalter EJ, Stevens KJ *et al.* MRI of the hip for the evaluation of femoroacetabular impingement; past, present, and future. *J Magn Reson Imaging* 2015; **41**: 558–72.
9. Agricola R, Waarsing JH, Arden NK *et al.* Cam impingement of the hip: a risk factor for hip osteoarthritis. *Nat Rev Rheumatol* 2013; **9**: 630–4.
10. Agricola R, Heijboer MP, Ginai AZ *et al.* A cam deformity is gradually acquired during skeletal maturation in adolescent and young male soccer players: a prospective study with minimum 2-year follow-up. *Am J Sports Med* 2014; **42**: 798–806.
11. Siebenrock KA, Fiechter R, Tannast M *et al.* Experimentally induced cam impingement in the sheep hip. *J Orthop Res* 2013; **31**: 580–7.
12. Allen D, Beaulé PE, Ramadan O *et al.* Prevalence of associated deformities and hip pain in patients with cam-type femoroacetabular impingement. *J Bone Joint Surg Br* 2009; **91**: 589–94.
13. Ayeni OR, Banga K, Bhandari M *et al.* Femoroacetabular impingement in elite ice hockey players. *Knee Surg Sports Traumatol Arthrosc* 2014; **22**: 920–5.
14. Bisciotti GN, Di Marzo F, Auci A *et al.* Cam morphology and inguinal pathologies: is there a possible connection? *J Orthop Traumatol* 2017; **18**: 439–50.
15. Frank JM, Harris JD, Erickson BJ *et al.* Prevalence of femoroacetabular impingement imaging findings in asymptomatic volunteers: a systematic review. *Arthroscopy* 2015; **31**: 1199–204.
16. Gerhardt MB, Romero AA, Silvers HJ *et al.* The prevalence of radiographic hip abnormalities in elite soccer players. *Am J Sports Med* 2012; **40**: 584–8.
17. Heerey JJ, Kemp JL, Mosler AB *et al.* What is the prevalence of hip intra-articular pathologies and osteoarthritis in active athletes with hip and groin pain compared with those without? A systematic review and meta-analysis. *Sports Med* 2019; **49**: 951–72.
18. Philippon MJ, Ho CP, Briggs KK *et al.* Prevalence of increased alpha angles as a measure of cam-type femoroacetabular impingement in youth ice hockey players. *Am J Sports Med* 2013; **41**: 1357–62.
19. Ranawat AS, Schulz B, Baumbach SF *et al.* Radiographic predictors of hip pain in femoroacetabular impingement. *HSS J* 2011; **7**: 115–9.
20. Register B, Pennock AT, Ho CP *et al.* Prevalence of abnormal hip findings in asymptomatic participants: a prospective, blinded study. *Am J Sports Med* 2012; **40**: 2720–4.
21. Schmitz MR, Campbell SE, Fajardo RS *et al.* Identification of acetabular labral pathological changes in asymptomatic volunteers using optimized, noncontrast 1.5-T magnetic resonance imaging. *Am J Sports Med* 2012; **40**: 1337–41.
22. Siebenrock KA, Ferner F, Noble PC *et al.* The cam-type deformity of the proximal femur arises in childhood in response to vigorous sporting activity. *Clin Orthop Relat Res* 2011; **469**: 3229–40.
23. Jónasson P, Thoreson O, Sansone M *et al.* The morphologic characteristics and range of motion in the hips of athletes and non-athletes. *J Hip Preserv Surg* 2016; **3**: 325–32.
24. Ishoi L, Thorborg K, Kraemer O *et al.* The association between specific sports activities and sport performance following hip arthroscopy for femoroacetabular impingement syndrome: a secondary analysis of a cross-sectional cohort study including 184 athletes. *J Hip Preserv Surg* 2019; **6**: 124–33.
25. Oliveira N, Sanders RH. Kinematic and kinetic evidence for functional lateralization in a symmetrical motor task: the water polo eggbeater kick. *Exp Brain Res* 2015; **233**: 947–57.
26. Oliveira N, Chiu CY, Sanders RH. Kinematic patterns associated with the vertical force produced during the eggbeater kick. *J Sports Sci* 2015; **33**: 1675–81.
27. Oliveira N, Saunders DH, Sanders RH. The effect of fatigue-induced changes in eggbeater-kick kinematics on performance and risk of injury. *Int J Sports Physiol Perform* 2016; **11**: 141–5.
28. Kawai E, Tsunokawa T, Takagi H. Estimating the hydrodynamic forces during eggbeater kicking by pressure distribution analysis. *Heliyon* 2018; **4**: e01095.
29. Oliveira N, Sanders RH. Effects of knee action phase and fatigue on Rectus Femoris and Biceps Femoris co-activation during the eggbeater kick. *Hum Mov Sci* 2017; **51**: 82–90.
30. Mohtadi NG, Griffin DR, Pedersen ME *et al.* The development and validation of a self-administered quality-of-life outcome measure for young, active patients with symptomatic hip disease: the International Hip Outcome Tool (iHOT-33). *Arthroscopy* 2012; **28**: 595–605; quiz 06-10.e1.
31. Ramisetty N, Kwon Y, Mohtadi N. Patient-reported outcome measures for hip preservation surgery—a systematic review of the literature. *J Hip Preserv Surg* 2015; **2**: 15–27.
32. George R, Dela Cruz J, Singh R *et al.* MRIMaster.com. London: *Indications for MRI Hips*.
33. Bagwell JJ, Powers CM. The influence of squat kinematics and cam morphology on acetabular stress. *Arthroscopy* 2017; **33**: 1797–803.
34. Yépez AK, Abreu M, Germani B *et al.* Prevalence of femoroacetabular impingement morphology in asymptomatic youth soccer players: magnetic resonance imaging study with clinical correlation. *Rev Bras Ortop* 2017; **52**: 14–20.
35. Sutter R, Dietrich TJ, Zingg PO *et al.* Femoral antetorsion: comparing asymptomatic volunteers and patients with femoroacetabular impingement. *Radiology* 2012; **263**: 475–83.
36. Nötzli HP, Wyss TF, Stoecklin CH *et al.* The contour of the femoral head–neck junction as a predictor for the risk of anterior impingement. *J Bone Joint Surg Br* 2002; **84-B**: 556–60.
37. Fiorentino G, Fontanarosa A, Cepparulo R *et al.* Treatment of cam-type femoroacetabular impingement. *Joints* 2015; **3**: 67–71.
38. Wiberg G. Studies on dysplastic acetabula and congenital subluxation of the hip joint: with special reference to the complication of osteoarthritis. *Acta Orthop Scand* 1939; **83**: 1–135.
39. Lee S, Nardo L, Kumar D *et al.* Scoring hip osteoarthritis with MRI (SHOMRI): a whole joint osteoarthritis evaluation system. *J Magn Reson Imaging* 2015; **41**: 1549–57.
40. Turkiewicz A, Luta G, Hughes HV *et al.* Statistical mistakes and how to avoid them—lessons learned from the reproducibility crisis. *Osteoarthritis Cartilage* 2018; **26**: 1409–11.
41. Fischer CS, Kühn JP, Ittermann T *et al.* What are the reference values and associated factors for center-edge angle and alpha angle? A population-based study. *Clin Orthop Relat Res* 2018; **476**: 2249–59.