

## Abstract

### Objective

To report a case of a man who developed bilateral Charcot neuroarthropathic feet 11 years after a simultaneous pancreas kidney (SPK) transplantation for type 1 diabetes following which he had remained normoglycaemic

### Methods

Retrospective review of case notes and serial imaging

### Results

We describe the case of a man who had developed dense peripheral diabetic neuropathy due to poor glycaemic control. His biochemical markers of diabetes all normalised following SPK transplantation, and he was discharged by his primary and secondary care diabetes services. 11 years later he developed Charcot neuropathy in one foot and within a month, the other foot as well.

### Conclusion

Individuals with diabetes who had pre-operative end organ diabetes related damage who biochemically into remission after SPK transplantation should never be discharged from specialist diabetes services and need continued education about foot care

**Keywords:** Diabetes; Charcot neuroarthropathy; simultaneous kidney pancreas transplant

1  
2  
3 Abbreviations

4  
5 CN – Charcot neuroarthopathy

6  
7 HbA1c - glycated haemoglobin

8  
9 MR – Magnetic resonance

10  
11 SPK - Simultaneous pancreas kidney  
12  
13  
14  
15  
16  
17  
18  
19  
20  
21  
22  
23  
24  
25  
26  
27  
28  
29  
30  
31  
32  
33  
34  
35  
36  
37  
38  
39  
40  
41  
42  
43  
44  
45  
46  
47  
48  
49  
50  
51  
52  
53  
54  
55  
56  
57  
58  
59  
60

## Introduction

Charcot neuroarthropathy (CN) is an uncommon but devastating complication that occurs in approximately 1 in 200 people with diabetes, but can result from any cause of peripheral neuropathy (1,2). Despite its disabling impact on patients, it is often overlooked, leading to a delay in diagnosis and subsequent mismanagement. A timely diagnosis is key to the management of CN (3). Once a diagnosis is established, initial treatment focuses on off-loading the affected limb to protect the skeleton until remission is achieved.

Simultaneous pancreas and kidney (SPK) transplantation is currently one of the management options for people with type 1 diabetes with end stage renal failure. Results have shown patients have a better quality of life and longer life expectancy. In individuals who may have had long standing poorly controlled diabetes, end organ complications may have occurred prior to SPK transplantation. However, after transplantation eye, gut, nerve and vascular disease have been shown to stabilise or improve as glycaemic control returns to the non-diabetic range (4).

One diabetes related complication that does not usually improve, however, is peripheral neuropathy. Charcot neuroarthropathy has been recognized to occur following SPK transplantation, but usually within the first post-operative year (5-8). There are reports of CN occurring several years after SPK transplantation (9). We present a case of bilateral simultaneous CN developing 11 years following SPK transplantation in a patient with diabetes with pre-existing peripheral neuropathy. To

1  
2  
3 our knowledge, this is the first documentation of a bilateral Charcot late occurrence,  
4  
5 after SPK transplantation.  
6  
7  
8

### 9 10 Case Report

11 A 55 year old self-employed builder had been diagnosed with type 1 diabetes  
12  
13 mellitus aged 15, and was managed with insulin until the age of 44. He had several  
14  
15 years of poor glycaemic control, and had developed proliferative diabetic retinopathy,  
16  
17 and end-stage renal failure. He had developed a dense bilateral peripheral  
18  
19 neuropathy for which all other potential causes had been excluded. In particular, he  
20  
21 has no history of leprosy, spinal cord defects, syphilis, alcohol misuse, trauma,  
22  
23 amyloidosis, or other autoimmune conditions. His vitamin B<sub>12</sub> concentrations were  
24  
25 within the reference range. As a result, he underwent SPK transplantation.  
26  
27  
28  
29  
30  
31

32 Following transplantation, he was commenced on a regimen of corticosteroids and  
33  
34 calcineurin inhibitors for immunosuppression. The operation resolved the need for  
35  
36 continued insulin therapy and reduced his blood glucose and glycated haemoglobin  
37  
38 (HbA1c) concentrations to the 'non-diabetic' ranges. Because he biochemically no  
39  
40 longer had diabetes, he was discharged from his local specialist diabetes services.  
41  
42  
43  
44  
45

46 Approximately 11 years later, the patient presented to his general practitioner with a  
47  
48 two-month history of increased temperature and swelling in his left foot. He was  
49  
50 initially diagnosed with gout and commenced on treatment, which failed to resolve  
51  
52 his symptoms. Subsequently a radiograph was requested, which identified features  
53  
54 of a CN with midfoot fractures, consolidation and a loss of the medial longitudinal  
55  
56 arch (Figures 1a and 1b).  
57  
58  
59  
60

1  
2  
3  
4  
5 The overall duration of treatment was 4 months during which he was successfully  
6  
7 treated in a total contact cast until he was in remission followed by a below knee  
8  
9 removable walking boot.  
10

11  
12  
13  
14  
15 Unfortunately 1 month later, whilst under review he presented with features  
16  
17 consistent with a contralateral right CN. The diagnosis was confirmed by radiographs  
18  
19 (Figures 2a and 2b), and an MR scan (Figures 3a and 3b) of his right foot.  
20

21  
22  
23  
24 Once a CN of the right foot was diagnosed, a similar management strategy ensued,  
25  
26 which was off-loading his affected foot. He is currently stable under regular review.  
27

## 28 29 30 Discussion

31  
32  
33  
34  
35 We have described the unusual case of a man who presented with bilateral Charcot  
36  
37 neuroarthropathic feet 11 years after SPK transplantation. Prior to transplantation he  
38  
39 had poor control of his diabetes, and had evidence of end organ damage, including  
40  
41 dense bilateral peripheral neuropathy. The CN occurred despite him having glucose  
42  
43 concentrations in the non-diabetic range following his SPK transplant. All other  
44  
45 causes of peripheral neuropathy had been excluded prior to his transplant and  
46  
47 subsequently, after he had developed his CN.  
48  
49

50  
51  
52  
53  
54 Previous work has looked at CN following a SPK transplant (5-9). In two reviews, it  
55  
56 was reported that the development of a CN commonly occurred within the first year,  
57  
58 with the latest occurrence at 5 years post transplantation (5,6). Whilst one previous  
59  
60

1  
2  
3 case report has reported a case of CN 11 years after SPK transplantation (9), to our  
4  
5 knowledge this is the first report detailing the development of bilateral CN a similar  
6  
7 time after an SPK transplant.  
8  
9

10  
11 We have previously described a similar case series of people developing CN after  
12  
13 attaining normoglycaemia after bariatric surgery (10). This patient was lost to follow  
14  
15 up when his SPK transplantation put his diabetes into remission and there was no  
16  
17 longer a need for dialysis. He did not receive regular foot care after that. His pre-  
18  
19 existing peripheral neuropathy and subsequent use of calcineurin inhibitors used as  
20  
21 part of the immunosuppressive regimen may have also contributed because of the  
22  
23 direct effects on bone metabolism, or a directly neurotoxic effect (5,11).  
24  
25  
26  
27  
28  
29

30  
31 Barrado's retrospective review of 100 patients identified 9 patients who developed a  
32  
33 CN (5). Almost half developed this within the first year, while the remaining 5  
34  
35 developed the condition within the next 5 years. In their analysis, the authors state  
36  
37 that patients who developed a CN had a higher mortality and graft failure rate. They  
38  
39 identified that patients with high pre-transplant HbA1c values and use of high  
40  
41 corticosteroid doses as risk factors for developing an acute CN.  
42  
43  
44  
45

46  
47 Matricali et al's, retrospective analysis of 66 patients, demonstrated a higher  
48  
49 incidence of development of CN at 12% (6). Their conclusions were similar to  
50  
51 Barrado et al, with a high pre-transplant HbA1c as a significant risk factor for  
52  
53 developing a CN post SPK transplant and a higher rate of mortality and graft  
54  
55 rejection in the CN group. They also suggested their results were due to the small  
56  
57 cohort of patients.  
58  
59  
60

1  
2  
3  
4  
5 In the review by Rangel et al, 130 patients without any history of CN were analysed  
6 retrospectively (7). Six patients developed de novo CN during the first year. They  
7  
8 also suggested that high doses of glucocorticoids were the main risk factor leading to  
9  
10 bone resorption and myofibril proteolysis. As a result of these reports and their own 2  
11  
12 cases, del Vecchio et al emphasized the importance of regular systematic follow up  
13  
14 of patients with diabetes undergoing SPK transplantation with a pre-existing  
15  
16 peripheral neuropathy (8).  
17  
18  
19  
20  
21  
22  
23

24 In summary, this is the second reported presentation of a CN occurring 11 years  
25 following an SPK transplantation. However, our case is different to the one reported  
26 because it is bilateral. As this case demonstrates, there is no clear defined time  
27  
28 period beyond which we can assume a patient is not at risk of developing a de novo  
29  
30 CN following SPK transplantation. Therefore, despite normal glycaemic control  
31  
32 following transplantation, these patients should remain under lifelong regular  
33  
34 specialist diabetes review. Patients and health care clinicians should maintain a high  
35  
36 degree of clinical suspicion when presented with a hot swollen foot with a concurrent  
37  
38 peripheral neuropathy.  
39  
40  
41  
42  
43  
44  
45  
46  
47  
48  
49

50 Written patient consent was obtained for this case report  
51  
52

### 53 Conflict of Interest Statement

54  
55 None  
56  
57  
58  
59  
60

## References

- 1 Jeffcoate WJ, Game FL, Cavanagh PR. The role of proinflammatory cytokines in the cause of neuropathic osteoarthropathy (acute Charcot foot) in diabetes. *Lancet* 2005;366:2058-2061.
- 2 Dhatariya K, Gooday C, Murchison R, Bullen B, Hutchinson R. Pedal neuroarthropathy in a nondiabetic patient as a result of long-term amiodarone use. *J Foot Ankle Surg* 2009;48:362-364.
- 3 Jeffcoate WJ. Charcot foot syndrome. *Diabetic Med* 2015; 32(6):760-770.
- 4 Redfield RR, Scalea JR, Odorico JS. Simultaneous pancreas and kidney transplantation: current trends and future directions. *Curr Opin Organ Tran* 2018;20:94-102.
- 5 Garcia Barrado F, Kuypers DR, Matricali GA. Charcot neuroarthropathy after simultaneous pancreas-kidney transplantation: risk factors, prevalence, and outcome. *Clin Transplant* 2015;29:712-719.
- 6 Matricali GA, Bammens B, Kuypers D, Flour M, Mathieu C. High rate of Charcot foot attacks early after simultaneous pancreas-Kidney Transplantation. *Transplantation* 2007;83:245-246.
- 7 Rangel EB, Sa JR, Gomes SA et al. Charcot neuroarthropathy after simultaneous pancreas-kidney transplant. *Transplantation* 2012;94:642-645.
- 8 del Vecchio JJ, Raimondi N, Rivarola H, Autorino C. Charcot neuroarthropathy in simultaneous kidney-pancreas transplantation: report of two cases. *Diabetic Foot & Ankle* 2013;4:21819.



- 1  
2  
3 9 Caldara R, Grispigni C, la Rocca E et al. Acute Charcot's arthropathy despite  
4  
5 11 years of normoglycemia after successful kidney and pancreas  
6  
7 transplantation. *Diabetes Care* 2001;24:1690.  
8  
9  
10  
11 10 Murchison R, Gooday C, Dhatariya K. The development of a Charcot foot  
12  
13 after significant weight loss in people with diabetes. *J Am Podiatr Med Assoc*  
14  
15 2014;104:522-525.  
16  
17  
18  
19 11 Bechstein WO. Neurotoxicity of calcineurin inhibitors: impact and clinical  
20  
21 management. *Transpl Int* 2000;13:313-326.  
22  
23  
24  
25  
26  
27  
28  
29  
30  
31  
32  
33  
34  
35  
36  
37  
38  
39  
40  
41  
42  
43  
44  
45  
46  
47  
48  
49  
50  
51  
52  
53  
54  
55  
56  
57  
58  
59  
60

## Legends to Figures

**Figure 1a and 1b** – Left foot AP and lateral radiograph demonstrating midfoot collapse, widening of the 1<sup>st</sup> and 2<sup>nd</sup> MT interspace.

**Figure 2a and 2b** – Right foot AP and lateral radiograph demonstrating erosive arthropathic changes of the tarsometatarsal joints – in particular the first– with reduction in joint space and sclerosis (solid arrow). In addition, there are ununited fractures at the base of the third and fourth metatarsals (striped arrows).

**Figure 3a and 3b** – Left foot MRI T1 sagittal and axial views demonstrating a destructive arthropathy of the common tarsometatarsal joint resulting in pes planus (solid arrow). There is marrow edema and severe erosive changes in the midfoot consistent with a Charcot neuroarthropathic joint. There is also collapse of the second metatarsal head.

1  
2  
3  
4  
5  
6  
7  
8  
9  
10  
11  
12  
13  
14  
15  
16  
17  
18  
19  
20  
21  
22  
23  
24  
25  
26  
27  
28  
29  
30  
31  
32  
33  
34  
35  
36  
37  
38  
39  
40  
41  
42  
43  
44  
45  
46  
47  
48  
49  
50  
51  
52  
53  
54  
55  
56  
57  
58  
59  
60

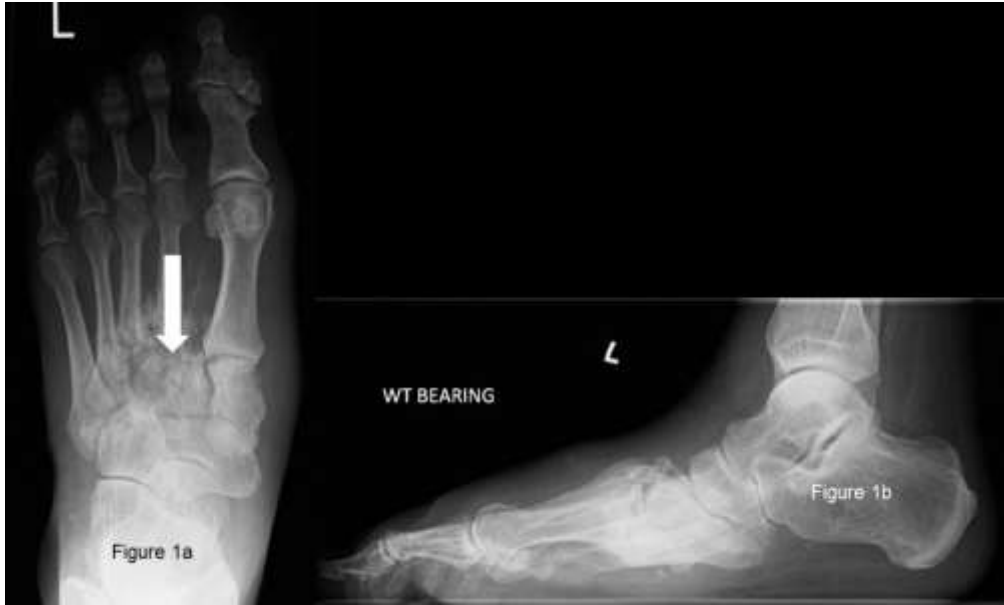

Figure 1a and 1b – Left foot AP and lateral radiograph demonstrating midfoot collapse, widening of the 1st and 2nd MT interspace.

201x121mm (150 x 150 DPI)

1  
2  
3  
4  
5  
6  
7  
8  
9  
10  
11  
12  
13  
14  
15  
16  
17  
18  
19  
20  
21  
22  
23  
24  
25  
26  
27  
28  
29  
30  
31  
32  
33  
34  
35  
36  
37  
38  
39  
40  
41  
42  
43  
44  
45  
46  
47  
48  
49  
50  
51  
52  
53  
54  
55  
56  
57  
58  
59  
60

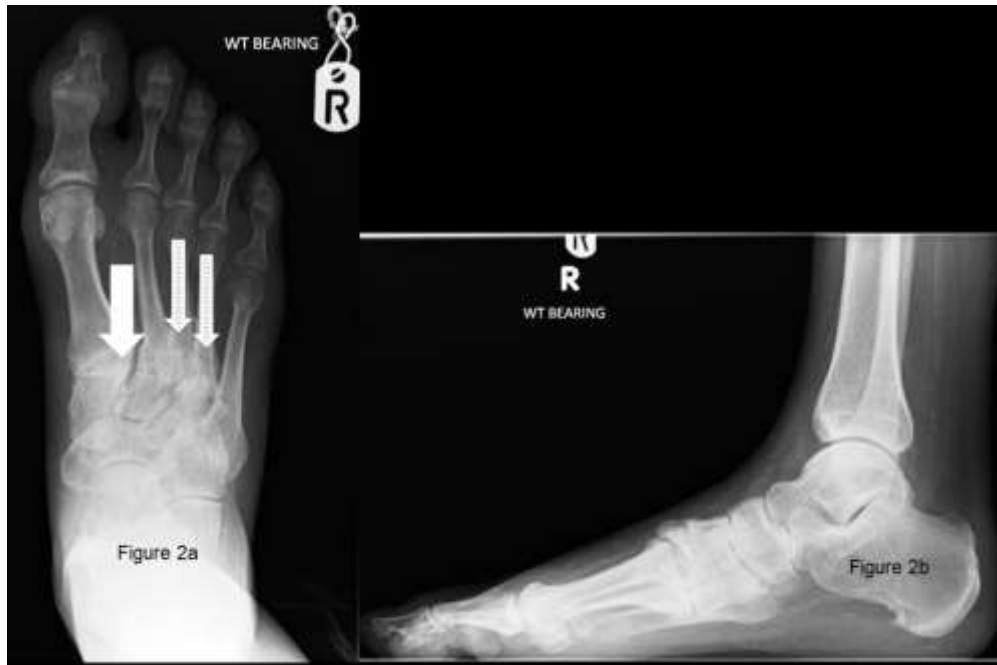

Figure 2a and 2b – Right foot AP and lateral radiograph demonstrating erosive arthropathic changes of the tarsometatarsal joints – in particular the first– with reduction in joint space and sclerosis(solid arrow). In addition, there are ununited fractures at the base of the third and fourth metatarsals (striped arrows).”

202x133mm (150 x 150 DPI)

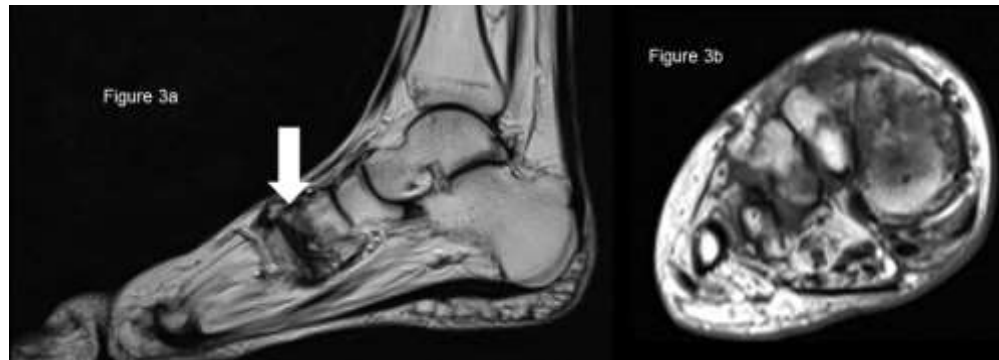


Figure 3a and 3b – Left foot MRI T1 sagittal and axial views demonstrating a destructive arthropathy of the common tarsometatarsal joint resulting in pes planus (solid arrow). There is marrow edema and severe erosive changes in the midfoot consistent with a Charcot neuroarthropathic joint. There is also collapse of the second metatarsal head.”

218x78mm (150 x 150 DPI)