

Performance of the Xpert MTB/RIF Assay in the Diagnosis of Tuberculosis in Formalin-fixed, Paraffin-embedded Tissues

Pascal Polepole¹, Mwila Kabwe², Mpanga Kasonde³, John Tembo^{2,4}, Aaron Shibemba³, Justin O'Grady⁵, Nathan Kapata⁶, Alimuddin Zumla^{2,7,8}, Matthew Bates^{2,7,8}

¹Department of Biomedical Sciences, University of Zambia School of Medicine, ²University of Zambia and University College London Medical School (UNZA-UCLMS) Research and Training Programme, University Teaching Hospital, ³Department of Pathology and Microbiology, University Teaching Hospital, ⁴National TB and Leprosy Control Programme, Ministry of Community Development, Mother and Child Health, Lusaka, Zambia, ⁵Institute for Infectious Diseases, Tongji Medical College, Huazhong University of Science and Technology, Wuhan, China, ⁶Norwich Medical School, University of East Anglia, Norwich, ⁷Department of Infection, Division of Infection and Immunity, University College London, ⁸National Institute for Health Research Biomedical Research Centre at UCL Hospitals, London, United Kingdom

Abstract

Objective/Background: Extrapulmonary tuberculosis (EPTB), which accounts for 10%–40% of the global burden of TB, with the highest incidence in Sub-Saharan Africa, is strongly associated with human immunodeficiency virus infection. Diagnosing EPTB is challenging, and recently, there has been a concerted effort to evaluate the latest molecular diagnostics for diagnosing TB in a range of specimen types. The Xpert MTB/RIF assay (Cepheid, Sunnyvale, CA, USA) is one such technology, which simultaneously detects *Mycobacterium tuberculosis* and rifampicin resistance. Our objective was to evaluate the accuracy of the Xpert MTB/RIF assay for the diagnosis of EPTB and detection of rifampicin resistance in routinely processed formalin-fixed, paraffin-embedded (FFPE) tissues, compared with histological detection of TB as the gold standard. **Methods:** A convenience set of 100 biobanked FFPE tissues, including lymph nodes ($n = 64$), male genital tract tissue ($n = 10$), abdominal tissue ($n = 8$), female genital tissue ($n = 5$), breast tissue ($n = 5$), synovial tissue ($n = 4$), skin ($n = 2$), tongue tissue ($n = 1$), and thyroid ($n = 1$), from routine cases of clinically suspected EPTB admitted to the University Teaching Hospital, Lusaka, Zambia, were analyzed using the Xpert MTB/RIF assay and in-house polymerase chain reaction (PCR) assay targeting IS6110, in parallel with Ziehl–Neelsen (ZN) staining, against histology as the gold standard. **Results:** Some 66% of specimens had histological evidence of TB infection. ZN staining was positive for TB in 8% of cases, and Xpert MTB/RIF was positive for TB in 25% of cases. Taking histology as the gold standard, the sensitivity and specificity were as follows: In lymph tissue the accuracy of the Xpert MTB/RIF assay was 41% (95%CI 27–57), not significantly better than ZN or the in-house PCR assay. In non-lymph tissue the sensitivity of the in-house PCR assay was 82% (95%CI: 56%–95%), significantly higher than the Xpert MTB/RIF assay ($P = 0.004$). The Xpert MTB/RIF assay indicated rifampicin resistance in just three cases. **Conclusion:** The Xpert MTB/RIF assay is potentially a useful tool for the diagnosis of TB in routine FFPE tissues.

Keywords: Formalin-fixed paraffin-embedded, histopathology, tuberculosis, Xpert MTB/RIF, Zambia, Ziehl–Neelsen

INTRODUCTION

Tuberculosis (TB) is an infectious disease caused by the bacillus *Mycobacterium tuberculosis*. It primarily affects the lungs (pulmonary TB [PTB]), but more advanced forms of the disease can affect other organs and tissues (extra-PTB [EPTB]). TB is one of the most important infectious diseases globally, with the World Health Organization (WHO) estimates suggesting that in 2014 (combining data for adults and children), there were approximately 9.6 million cases of TB and 1.5 million deaths, of which 400,000 were in patients coinfecting with human immunodeficiency virus (HIV).^[1] The disease is transmitted when uninfected people inhale bacilli-containing droplet nuclei

Address for correspondence: Mr. Pascal Polepole,

University of Zambia School of Medicine,
Department of Biomedical Sciences, P O BOX 30784, Lusaka 10101, Zambia.

E-mail: poleman1981@gmail.com,

Dr. Matthew Bates,

University of Zambia and University College London Medical School (UNZA-UCLMS) Research and Training Programme, University Teaching Hospital, Lusaka, Zambia, Department of Infection, Division of Infection and Immunity, University College London, NIHR Biomedical Research Centre at UCL Hospitals, Chadwick Building, Kings Cross, London WC1E 6BT, United Kingdom.

E-mail: matthew.bates@ucl.ac.uk

This is an open access article distributed under the terms of the Creative Commons Attribution-NonCommercial-ShareAlike 3.0 License, which allows others to remix, tweak, and build upon the work non-commercially, as long as the author is credited and the new creations are licensed under the identical terms.

For reprints contact: reprints@medknow.com

How to cite this article: Polepole P, Kabwe M, Kasonde M, Tembo J, Shibemba A, O'Grady J, *et al.* Performance of the Xpert MTB/RIF assay in the diagnosis of tuberculosis in formalin-fixed, paraffin-embedded tissues. *Int J Mycobacteriol* 2017;6:87–93.

Access this article online

Quick Response Code:



Website:
www.ijmyco.org

DOI:
10.4103/2212-5531.201892

produced when PTB patients cough. Primary infection is thought to be largely subclinical, and therefore, active disease ensues on reactivation of latent infection or due to reinfection. Reactivation is strongly associated with immunosuppression, often due to HIV infection, but majority of patients with active TB globally are HIV negative, with malnutrition, stress, depression, and possibly host genetic factors being associated with the development of active disease.

One of the greatest challenges to achieving sustained improvements in TB control globally is that the currently available diagnostic tools and strategies are inadequate to easily capture all active TB cases and stem transmission. These challenges are particularly acute in Sub-Saharan Africa which endures the highest burden of active TB, where in both the community^[2] and hospital settings, many cases of active TB and drug-resistant TB remain undiagnosed.^[2,3] At the University Teaching Hospital, Lusaka, Zambia, we have recently unearthed a significant burden of undiagnosed TB and multidrug-resistant (MDR) TB cases, affecting both HIV-infected and uninfected patients, with active culture positive TB being detected in up to 10% of adult patients who can expectorate, but who do not fulfill the classical definition of “TB suspect.”^[2] Following on from this, we have undertaken cross-sectional autopsy studies in both adult and pediatric deaths and found missed TB, EPTB, or MDR-TB infection as a cause of death in up to 10% of both adult and pediatric admissions.^[4,5]

Hospitals in Sub-Saharan Africa are concentrating centers for the more advanced EPTB, in patients whose prior PTB infection has been missed or inadequately treated by community-based TB diagnostic and treatment facilities. EPTB disease occurs in places other than the lungs, including the larynx, lymph nodes, pleura, brain, kidneys, or bones and joints.^[6] Following lymphatic or hematogenous spread of bacilli during primary pulmonary infection, tubercle bacilli settle in different body sites, multiply, and elicit host immune responses, which results in the formation of granulomas with caseous necrosis and Langhans-type giant cells, a set of signs known as classic histopathological features of TB.^[7] This “gold standard” definition of TB infection does not differentiate *M. tuberculosis* from other mycobacteria; central caseous necrosis is not always apparent in small biopsies,^[8] and there are other possible granulomatous conditions.^[8] Accurately diagnosing EPTB microbiologically is also difficult because it requires invasive biopsy sampling of paucibacillary tissues or fluids (e.g., cerebrospinal fluid [CSF]), which might be of limited volume and have a nonuniform distribution of bacilli. A Ziehl–Neelsen (ZN) stain confirms the presence of acid-fast mycobacteria but is not specific for *M. tuberculosis*. Culturing *M. tuberculosis* from tissue may be available in some laboratories, but this requires fresh sterile specimens, is resource intensive requiring Biosafety Level (BSL-3) lab facilities, and is not routinely practiced outside of large research-focused hospitals.

Hence, there has been much interest in recent years on the application of *M. tuberculosis*-specific molecular diagnostics, originally developed to test for *M. tuberculosis* DNA in

respiratory specimens, for the rapid and accurate diagnosis of EPTB (and drug-resistant EPTB) using a variety of biopsy specimen types.^[9–11] One such assay is the Xpert MTB/RIF assay (Cepheid, Sunnyvale, CA, USA), which is a fully integrated cartridge-based polymerase chain reaction (PCR) assay that has been designed to use molecular beacons technology to detect specific molecular signatures of both *M. tuberculosis* complex and rifampicin resistance. The assay was primarily designed for the diagnosis of TB in sputum specimens and received the WHO endorsement in 2010, as the initial diagnostic tool for HIV-associated or MDR-TB, and as a follow-up diagnostic method in smear-negative TB suspects.^[12] The assay has been extensively evaluated using sputum and other respiratory specimens, in both adults^[13] and children,^[14] and is broadly thought to be twice as sensitive as smear microscopy, using culture as the gold standard, diagnosing in excess of 80% of culture-confirmed PTB.^[15] Researchers have also started experimenting with the use of the Xpert MTB/RIF assay for detecting *M. tuberculosis* in nonrespiratory specimens. Several studies have assessed the utility of the Xpert MTB/RIF assay for the diagnosis of EPTB through analysis of biopsy specimens, including various body fluids (urine, CSF, pleural fluid) or fresh and frozen tissues (as reviewed).^[16] In summary, compared with liquid culture as the gold standard, the Xpert MTB/RIF assay has a generally high specificity in a range of specimen types, but studies report very varied sensitivity results, with pooled values as low as 34% (95% confidence interval [CI]: 24%–44%) in pleural fluid, but as high as 96% (95% CI: 72%–99%) in lymph nodes.^[16]

Most studies to date have used fresh or fresh-frozen tissue or biopsy specimens for Xpert analysis,^[12,16] but the routine method for handling biopsy or postmortem tissue in a diagnostic histopathology laboratory is to fix the specimen with formalin and embed it in paraffin wax. Whether fresh from the tissue processor or from archived biobanks, formalin-fixed paraffin-embedded (FFPE) tissues are important diagnostic research materials as they are noninfectious, have a better preserved cellular architecture, and hence are suitable for morphological evaluation and can be kept for a long time, making them useful for retrospective studies. Here, we evaluate the Xpert MTB/RIF assay alongside an in-house PCR assay targeting IS6110, for detection of *M. tuberculosis* in a range of FFPE biopsy specimens compared with ZN staining and routine histopathology as the gold standard.

METHODS

Study design and site

We conducted a retrospective laboratory-based study to compare the accuracy of both the Xpert MTB/RIF assay and an in-house PCR assay, for the diagnosis of EPTB in FFPE biopsy specimens against histology as the gold standard. The study was undertaken at the University Teaching Hospital in Lusaka, Zambia, on routine specimens collected in 2013. All of the samples were subjected to histology, ZN, in-house PCR, and Xpert MTB/RIF assay tests.

Histology and Ziehl–Neelsen staining

Paraffin blocks were placed cut surface down on an ice-cold plate for 20 min. The manual rotary microtome was used for this study, and it was thoroughly cleaned before each sectioning session using xylene to remove residue paraffin wax. To minimize the potential for cross DNA contamination, gloves were worn and the microtome and surrounding station were cleaned with bleach between specimens, and a new microtome blade and pair of gloves were used for each block. The block was first trimmed at 15–30 μm , followed by one to four ribbons of 5 μm for histological diagnosis stained with hematoxylin and eosin, one to four ribbons obtained for ZN staining, and a series of 10 μm thick sections for the in-house PCR ($n = 3 - 9$) and for the Xpert assay ($n = 5 - 20$). Microscopic examination of hematoxylin and eosin stained slides was done by a consultant pathologist, Dr. Aaron Shibemba.

DNA extraction

Sample DNA was extracted by the xylene-phenol-chloroform method adapted from Pikor *et al.*^[17] All of the procedures were performed in a fume hood. Samples were deparaffinized using three changes of xylene, 800 μL each change, and then dehydrated through a series of 800 μL alcohols (100%, 70%, and then 50%) using molecular grade ethanol. At this stage, the samples were air dried for 5 min, followed by addition of 500 μL of lysis buffer and 20 μL of proteinase K (20 mg/mL stock solution; Qiagen, Hilden, Germany). After thorough mixing, the samples were incubated at 56°C for 48 h. The samples were then washed using an equal volume of neutral buffered phenol, followed by addition of a solution made up of a mixture of phenol, chloroform, and isoamyl alcohol (25:24:1; v/v) to complete the process of DNA clean up. This was followed by the DNA precipitation step using 3M sodium acetate at pH 5.2 in quantities of 1/10 the volume of the sample, followed by addition of equal volumes of 100% isopropanol. The solution was then frozen at –20°C for 30 min, followed by a 10 min spin at 21,000 \times g. After discarding the supernatant, the pellet was washed with ice-cold 70% ethanol and finally resuspended in 50 μL of molecular grade water. DNA was quantified using a Nanodrop ND-1000 spectrophotometer (Thermo Fisher Scientific, Wilmington, DE, USA).

IS6110 real-time polymerase chain reaction

We designed an SYBR-Green real-time PCR assay targeting a 245 bp fragment of IS6110 of *M. tuberculosis* complex. The 20 μL reaction contained 1 μL of each primer (INS1: 5'-CGTGAGGGCATCGAGGTGGC-3' and INS2: 5'-GCGTAGGCGTCGGTGACAAA-3'),^[18] 10 μL of SYBR Green Master Mix (Qiagen, Manchester, UK), 3 μL of molecular grade water, and 5 μL of the template. Reactions were performed on a Rotor-Gene 6000 (Corbett, Mortlake, Australia) with the following cycling conditions: 95°C for 5 min, followed by 40 cycles of 94°C for 2 min, 60°C for 2 min, and 72°C for 2 min, and a melt curve at 99°C. Every PCR run included positive and negative controls.

The Xpert MTB/RIF assay

After deparaffinization and dehydration as described above, the tissue homogenate was then poured into a tube containing silica gel beads, and 1000 μL of distilled water was added. The tissue was then crushed by means of vortexing for 15 min, after which 1000 μL of the tissue homogenate was mixed with 2000 μL of the Gene Xpert reagent (Axon Lab Baden, Switzerland) and allowed to settle for 15 min. Some 2000 μL of this mixture was then analyzed by the Xpert MTB/RIF assay (Cepheid) in accordance with the manufacturer's instructions.

Ethical approval

The study was approved by the ERES Converge Institutional Review Board (approval number: 2014-NOV-004). Permission to use the archival FFPE tissues and other utilities was sought from the Senior Medical Superintendent of the University Teaching Hospital. The study was laboratory-based, with no direct contact with patients.

RESULTS

Burden of tuberculosis diagnosed by different methods

We screened 100 routine biopsy specimens by histopathology, ZN stain, in-house PCR, and the Xpert MTB/RIF assay. Some 64% were lymph node biopsies, 10% were male genital tract, 8% were abdominal tissue, 5% were female genital tract, and 5% were breast tissue, with the remaining non-lymph specimens being listed in Table 1. All lymph nodes and 25 non-lymph node specimens were taken from patients with suspected TB infection. The remaining 11 cases included seven patients with suspected cancer/growths and four with swollen joints. Histological evidence of TB infection was observed in 71.9% (46/64) of lymph specimens, 60% (6/10) of male genital tissue, and 50% (4/8) of abdominal tissue and was commonly observed in all other tissues, except thyroid [Table 1]. In lymph tissue, the in-house PCR assay had the greatest yield (34.4% [22/64]), followed by the Xpert MTB/RIF assay (28.1% [18/64]), and ZN staining had the lowest yield (9.4% [6/64]) [Table 1]. The yield given by these other diagnostic tests used was also universally lower in male genital tract and abdominal tissue [Table 1]. ZN was consistently negative in all other tissues, and the Xpert MTB/RIF assay was positive in both skin biopsies, but no other tissues [Table 1]. Conversely, the in-house PCR assay was positive in 50% (18/36) of non-lymph tissue, with representative positives in all specimen types [Table 1]. Both molecular tests combined were only able to detect 52% (24/46) of histopathologically confirmed TB cases within lymph tissue, whereas within non-lymph tissue, they detected 88% (15/17) of histology-confirmed TB cases [Figure 1]. Where there was no histological indication of TB infection, the molecular TB tests were positive in 33% (6/18) of lymph and 36% (5/14) of non-lymph tissues. There was a high level of discordance between TB diagnostic tests in both lymph and non-lymph tissue [Table 2].

Accuracy of molecular diagnostic methods

Within the lymph node tissue, the sensitivity of ZN, in-house PCR, and the Xpert MTB/RIF assay was 13% (95% CI: 5%–27%), 41% (95% CI: 27%–57%), and 30% (95% CI: 18%–46%), respectively. The specificity of ZN staining was very high (100% [95% CI: 78%–100%]), but the specificity of both the in-house PCR (83% [95% CI: 58%–96%]) and Xpert MTB/RIF (78% [95%CI: 52%–

93%]) assays was low [Table 3]. In non-lymph tissue, the performance of ZN and the Xpert MTB/RIF assay was very similar with no significant differences in either sensitivity or specificity. Conversely, the in-house PCR assay was significantly more sensitive than the Xpert MTB/RIF assay: 82% (95% CI: 56%–95%) vs 35% [95% CI:15%–61%]; $P = 0.004$ [Table 3]. The Xpert MTB/RIF assay detected rifampicin resistance in just three cases (2 TB lymphadenitis

Table 1: Yield of tuberculosis detection in different specimen types using different diagnostics

	H and E (%)	ZN (%)	PCR (%)	Xpert (%)	Xpert RIF (%)	Any test positive (%)
Lymph nodes (n=64)	46 (71.9)	6 (9.4)	22 (34.4)	18 (28.1)	2 (3.1)	52 (81.3)
Male genital tract (n=10)	6 (60)	1 (10)	5 (50)	3 (30)	1 (10)	7 (70)
Abdominal tissue (n=8)	4 (50)	1 (13)	3 (38)	2 (25)	0 (0)	4 (50)
Breast (n=5)	2	0	3	0	0	3
Female genital tract (n=5)	2	0	3	0	0	3
Skin (n=2)	1	0	1	2	0	2
Synovial tissue (n=4)	1	0	1	0	0	1
Tongue (n=1)	1	0	1	0	0	1
Thyroid (n=1)	0	0	1	0	0	1

Percentages not given for $n \leq 5$. H and E: Hematoxylin and eosin, PCR: Polymerase chain reaction, RIF: Rifampicin, ZN: Ziehl-Neelsen

Table 2: Tuberculosis diagnostic matrix highlighting high level of discordance for both lymph (bold) and non-lymph tissue (nonbold)

	Histology		ZN		Xpert		PCR		Xpert or PCR	
	Negative	Positive	Negative	Positive	Negative	Positive	Negative	Positive	Negative	Positive
Histology										
Negative			18	0	14	4	15	3	12	6
Positive			40	6	32	14	27	19	22	24
ZN										
Negative	19	15			46	12	42	16	34	24
Positive	0	2			0	6	0	6	0	6
Xpert										
Negative	18	11	29	0			34	12		
Positive	1	6	5	2			8	10		
PCR										
Negative	15	3	18	0	16	2				
Positive	4	14	16	2	13	5				
Xpert or PCR										
Negative	14	2	16	0						
Positive	5	15	18	2						

PCR: Polymerase chain reaction, ZN: Ziehl-Neelsen

Table 3: Accuracy of Ziehl-Neelsen, polymerase chain reaction, and Xpert against histopath as gold standard

	Sensitivity % (95% CI)	Specificity % (95% CI)	PPV % (95% CI)	NPV % (95% CI)
Lymph node specimens				
ZN	13 (5-27)	100 (78-100)	100 (52-100)	31 (20-47)
PCR	41 (27-57)	83 (58-96)	56 (38-72)	10 (3-28)
Xpert	30 (18-46)	78 (52-93)	78 (52-93)	30 (18-46)
Non-lymph specimens				
ZN	12 (2-38)	100 (79-100)	100 (20-100)	56 (38-72)
PCR	82 (56-95)	79 (54-93)	78 (52-93)	83 (58-96)
Xpert	35 (15-61)	94 (72-100)	86 (42-99)	62 (42-79)

NPV: Negative predictive value, PPV: Positive predictive value, CI: Confidence interval, PCR: Polymerase chain reaction, ZN: Ziehl-Neelsen

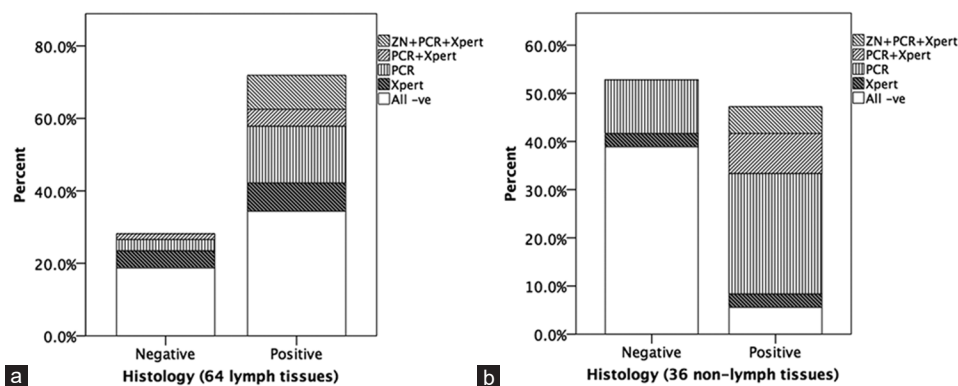


Figure 1: Distribution of histopathology, Ziehl–Neelsen and molecular tuberculosis diagnostic results within (a) 64 lymph tissue specimens analyzed and (b) 36 non-lymph tissue specimens analyzed.

and 1 TB orchitis), but for 14 cases, the rifampicin resistance results were reported as “indeterminate”.

DISCUSSION

The study had four key findings:

- Histologically confirmed TB was highly prevalent among FFPE biopsy specimens submitted for routine TB diagnosis, seen in 71.9% (46/64) of lymph node biopsies, and in up to 60% of other specimen types.
- Both the Xpert MTB/RIF assay and in-house PCR assay had poor sensitivity (<50%) for detecting histology-confirmed TB in FFPE lymph biopsies.
- Within FFPE non-lymph tissue specimens, the in-house PCR assay had a reasonable sensitivity of 82% (56%–95%), significantly higher than that of the Xpert MTB/RIF assay (35% [15%–61%]; $P = 0.004$).
- The high frequency of discordance between histology and both molecular assays, which are by their nature highly specific for detecting *M. tuberculosis* DNA, is strongly suggestive that for a significant minority of cases, there may have been non-TB causes of granulomatous inflammation and, conversely, that there may have been active TB disease in the absence of granulomatous inflammation.

The findings in this study should be interpreted in light of several limitations. This was a laboratory-based study, and hence, the specimens analyzed do not represent a clinically defined patient group, and the amount of clinical data available was limited. We do not know the HIV status of the cases for example. The retrospective nature of the study meant that we could not include TB culture as an alternative gold standard against which to evaluate the Xpert MTB/RIF assay, which would be more comparable with previous evaluations on fresh/frozen tissue specimens.

The high burden of TB among the lymph and other tissue specimens analyzed is consistent with our previous studies at the University Teaching Hospital, where we have shown a considerable burden of TB among adult inpatients. Our surveillance study, of all adult admissions who could

expectorate, identified culture-confirmed TB in 10% of hospital admissions in whom TB was not suspected clinically.^[2] Following this, our cross-sectional autopsy study identified active TB infection in 62% of adult mortalities, with up to 26% of cases being undiagnosed premortem.^[4]

The finding that ZN staining rarely detects acid-fast bacilli in histology-confirmed TB cases is consistent with studies done elsewhere^[9,19–22] and highlights its limited clinical value as a diagnostic tool. While specificity was very high, ZN staining is not specific to *M. tuberculosis* and positive slides might also indicate the presence of non-TB mycobacteria (NTM), which can be highly prevalent in high TB burden settings: Recent national surveillance studies in Zambia found the prevalence of NTM to be 1,477/100,000 population,^[23] over 3-fold higher than the prevalence of TB (455/100,000 population).^[24] The clinical implications of this are unclear,^[25,26] but perceived wisdom is that NTM are not important contributors to lung disease globally, irrespective of HIV status.^[26–28] Our recent pediatric autopsy study found NTM to be commonly detectable in lung tissue by molecular methods, including in cases with histological evidence of TB infection.^[5]

For this reason, molecular methods that specifically target *M. tuberculosis* complex are highly attractive as possible confirmatory tests for tissue specimens with histological evidence of TB. In FFPE lymph specimens, the sensitivities of both the Xpert MTB/RIF assay (30%) and the in-house PCR assay (41%) were significantly lower than what has been observed in fresh biopsy specimens (median sensitivity among 14 studies was 94%).^[12,16] These biopsy or fine-needle aspirate studies used culture as the gold standard but the application of molecular diagnostics to histological specimens can potentially result in a diagnosis in just a few days, compared with several weeks for culture.^[8] There is just one previous study in the literature that used the Xpert MTB/RIF assay to detect *M. tuberculosis* in FFPE tissues (mainly lung tissue), comparing its performance with that of the Artus *M. tuberculosis* RG-PCR (Qiagen, QIAGEN UK) among histopathologically confirmed TB cases.^[10] Consistent with our findings, the Xpert MTB/RIF and Artus *M. tuberculosis* RG-PCR assays

detected *M. tuberculosis* in 50% (20/40) and 42.5% (17/40) of cases, respectively.^[10] This study did not include any non-TB cases and so could not estimate specificity. Among 32 cases without TB histopathology, we detected *M. tuberculosis* DNA in six lymph specimens and five non-lymph specimens, resulting in relatively low specificity; however, clinically, even in the absence of TB pathology, a positive PCR test for *M. tuberculosis* complex on a tissue biopsy would likely inform on initiation of TB therapy.^[29] Culture analysis of fresh specimens may have confirmed some of these cases. WHO recommendations state that:

Xpert MTB/RIF may be used as a replacement test for usual practice (including conventional microscopy, culture, and/or histopathology) for testing of specific nonrespiratory specimens (lymph nodes and other tissues) from patients presumed to have EPTB (conditional recommendation, very low quality of evidence).^[12]

This advice is based on studies of fresh biopsy specimens and fine-needle aspirates against culture as the gold standard and they state that the quality of evidence is quite low, most likely because of variation in methodologies used and the limited sample size of most studies. The median sample size of the 14 studies referenced was $n = 43$,^[12,16] with the largest study being $n = 344$.^[30]

Our data suggest that the use of molecular methods such as the Xpert MTB/RIF assay on FFPE tissue may be superfluous on specimens undergoing routine histopathology although the rapid detection of rifampicin resistance could be clinically informative, and use of the Xpert MTB/RIF assay might be justified in certain tissue specimens or from certain patient groups, in which the prevalence of rifampicin resistant EPTB is high. We detected rifampicin resistance in 27% (3/11) of Xpert MTB-positive specimens, for which we had valid rifampicin resistant results, but this outcome was confounded by a large number of “indeterminate” results, presumably representing some aspect of specimen preparation which may have impaired this aspect of the Xpert MTB/RIF assay. In our previous study of PTB at the same hospital, we found that 18% of isolates were rifampicin resistant,^[31] and it would be logical to assume that as EPTB is typically an extension of untreated or inadequately treated pulmonary disease, the prevalence of drug resistance among EPTB cases is likely to be higher than among PTB cases.^[32]

CONCLUSION

The Xpert MTB/RIF assay may be a useful diagnostic tool for rapidly detecting rifampicin resistance in FFPE tissue specimens, but its overall sensitivity is too low to warrant replacement of histopathology.

Financial support and sponsorship

Nil.

Conflicts of interest

There are no conflicts of interest.

REFERENCES

- World Health Organization (WHO). Global Tuberculosis Report 2014. Geneva: WHO; 2014.
- Bates M, O'Grady J, Mwaba P, Chilukutu L, Mzyece J, Cheelo B, *et al.* Evaluation of the burden of unsuspected pulmonary tuberculosis and co-morbidity with non-communicable diseases in sputum producing adult inpatients. *PLoS One* 2012;7:e40774.
- Lawn SD, Kerkhoff AD, Burton R, Schutz C, van Wyk G, Vogt M, *et al.* Rapid microbiological screening for tuberculosis in HIV-positive patients on the first day of acute hospital admission by systematic testing of urine samples using Xpert MTB/RIF: A prospective cohort in South Africa. *BMC Med* 2015;13:192.
- Bates M, Mudenda V, Shibemba A, Kaluwaji J, Tembo J, Kabwe M, *et al.* Burden of tuberculosis at post mortem in inpatients at a tertiary referral centre in Sub-Saharan Africa: A prospective descriptive autopsy study. *Lancet Infect Dis* 2015;15:544-51.
- Bates M, Shibemba A, Mudenda V, Chimoga C, Tembo J, Kabwe M, *et al.* Burden of respiratory tract infections at post mortem in Zambian children. *BMC Med* 2016;14:99.
- Denkinger CM, Schumacher SG, Boehme CC, Dendukuri N, Pai M, Steingart KR. Xpert MTB/RIF assay for the diagnosis of extrapulmonary tuberculosis: A systematic review and meta-analysis. *Eur Respir J* 2014;44:435-46.
- Park DY, Kim JY, Choi KU, Lee JS, Lee CH, Sol MY, *et al.* Comparison of polymerase chain reaction with histopathologic features for diagnosis of tuberculosis in formalin-fixed, paraffin-embedded histologic specimens. *Arch Pathol Lab Med* 2003;127:326-30.
- Surat G, Wallace WA, Laursen IF, Seagar AL. Rapid real-time PCR for detection of *Mycobacterium tuberculosis* complex DNA in formalin-fixed paraffin embedded tissues: 16% of histological 'sarcooid' may contain such DNA. *J Clin Pathol* 2014;67:1084-7.
- Hillemann D, Galle J, Vollmer E, Richter E. Real-time PCR assay for improved detection of *Mycobacterium tuberculosis* complex in paraffin-embedded tissues. *Int J Tuberc Lung Dis* 2006;10:340-2.
- Yagmur G, Albayrak N, Das T, Yildirim M, Ozgün A, Büyük Y. Comparison of two different real-time PCR systems in postmortem diagnosis of tuberculosis in paraffin-embedded tissues. *Mikrobiyol Bul* 2014;48:577-84.
- Scott LE, Beylis N, Nicol M, Nkuna G, Molapo S, Berrie L, *et al.* Diagnostic accuracy of Xpert MTB/RIF for extrapulmonary tuberculosis specimens: Establishing a laboratory testing algorithm for South Africa. *J Clin Microbiol* 2014;52:1818-23.
- World Health Organization (WHO). Automated real-time nucleic acid amplification technology for rapid and simultaneous detection of tuberculosis and rifampicin resistance: Xpert MTB/RIF assay for the diagnosis of pulmonary and extrapulmonary TB in adults and children: Policy update. In: Automated Real-time Nucleic Acid Amplification Technology for Rapid and Simultaneous Detection of Tuberculosis and Rifampicin Resistance: Xpert MTB/RIF Assay for the Diagnosis of Pulmonary and Extrapulmonary TB in Adults and Children: Policy Update. 16th ed. Geneva: WHO; 2013.
- Steingart KR, Schiller I, Horne DJ, Pai M, Boehme CC, Dendukuri N. Xpert[®] MTB/RIF assay for pulmonary tuberculosis and rifampicin resistance in adults. *Cochrane Database Syst Rev* 2014;1:CD009593.
- Detjen AK, DiNardo AR, Leyden J, Steingart KR, Menzies D, Schiller I, *et al.* Xpert MTB/RIF assay for the diagnosis of pulmonary tuberculosis in children: A systematic review and meta-analysis. *Lancet Respir Med* 2015;3:451-61.
- Bates M, Zumla A. The development, evaluation and performance of molecular diagnostics for detection of *Mycobacterium tuberculosis*. *Expert Rev Mol Diagn* 2016;16:307-22.
- Maynard-Smith L, Larke N, Peters JA, Lawn SD. Diagnostic accuracy of the Xpert MTB/RIF assay for extrapulmonary and pulmonary tuberculosis when testing non-respiratory samples: A systematic review. *BMC Infect Dis* 2014;14:709.
- Pikor LA, Enfield KS, Cameron H, Lam WL. DNA extraction from paraffin embedded material for genetic and epigenetic analyses. *J Vis Exp* 2011. pii: 2763.
- Leao SC, Martin A, Mejia GI, Palomino JC, Robledo J, da Silva Telles

- MA. Practical Handbook for the Phenotypic and Genotypic Identification of Mycobacteria. Belgium: Ghent University; 2004. p. 113-8.
19. Azov AG, Koch J, Hamilton-Dutoit SJ. Improved diagnosis of mycobacterial infections in formalin-fixed and paraffin-embedded sections with nested polymerase chain reaction. *APMIS* 2005;113:586-93.
 20. Lee HS, Park KU, Park JO, Chang HE, Song J, Choe G. Rapid, sensitive, and specific detection of *Mycobacterium tuberculosis* complex by real-time PCR on paraffin-embedded human tissues. *J Mol Diagn* 2011;13:390-4.
 21. Maurya AK, Kant S, Nag VL, Kushwaha RA, Kumar M, Dhole TN. Comparative evaluation of IS6110 PCR via conventional methods in rapid diagnosis of new and previously treated cases of extrapulmonary tuberculosis. *Tuberk Toraks* 2011;59:213-20.
 22. Cortez MV, Oliveira CM, Monte RL, Araújo JR, Braga BB, Reis DZ, *et al.* HIV-associated tuberculous lymphadenitis: The importance of polymerase chain reaction (PCR) as a complementary tool for the diagnosis of tuberculosis – A study of 104 patients. *An Bras Dermatol* 2011;86:925-31.
 23. Chanda-Kapata P, Kapata N, Klinkenberg E, Mulenga L, Tembo M, Katemangwe P, *et al.* Non-tuberculous mycobacteria (NTM) in Zambia: Prevalence, clinical, radiological and microbiological characteristics. *BMC Infect Dis* 2015;15:500.
 24. Kapata N, Chanda-Kapata P, Ngosa W, Metitiri M, Klinkenberg E, Kalisvaart N, *et al.* The prevalence of tuberculosis in Zambia: Results from the first national TB prevalence survey, 2013-2014. *PLoS One* 2016;11:e0146392.
 25. Buijtelts PC, van-der-Sande MA, de-Graaff CS, Parkinson S, Verbrugh HA, Petit PL, *et al.* Nontuberculous mycobacteria, Zambia. *Emerg Infect Dis* 2009;15:242-9.
 26. Johnson MM, Odell JA. Nontuberculous mycobacterial pulmonary infections. *J Thorac Dis* 2014;6:210-20.
 27. O'Brien DP, Currie BJ, Krause VL. Nontuberculous mycobacterial disease in Northern Australia: A case series and review of the literature. *Clin Infect Dis* 2000;31:958-67.
 28. Parrish SC, Myers J, Lazarus A. Nontuberculous mycobacterial pulmonary infections in non-HIV patients. *Postgrad Med* 2008;120:78-86.
 29. Mehta PK, Raj A, Singh N, Khuller GK. Diagnosis of extrapulmonary tuberculosis by PCR. *FEMS Immunol Med Microbiol* 2012;66:20-36.
 30. Van Rie A, Page-Shipp L, Mellet K, Scott L, Mkhwnazi M, Jong E, *et al.* Diagnostic accuracy and effectiveness of the Xpert MTB/RIF assay for the diagnosis of HIV-associated lymph node tuberculosis. *Eur J Clin Microbiol Infect Dis* 2013;32:1409-15.
 31. O'Grady J, Bates M, Chilukutu L, Mzyece J, Cheelo B, Chilufya M, *et al.* Evaluation of the Xpert MTB/RIF assay at a tertiary care referral hospital in a setting where tuberculosis and HIV infection are highly endemic. *Clin Infect Dis* 2012;55:1171-8.
 32. Dusthacker A, Sekar G, Chidambaram S, Kumar V, Mehta P, Swaminathan S. Drug resistance among extrapulmonary TB patients: Six years experience from a supranational reference laboratory. *Indian J Med Res* 2015;142:568-74.

