

TDP-43 in the hypoglossal nucleus identifies amyotrophic lateral sclerosis in behavioral variant frontotemporal dementia

Glenda M Halliday^{a,b}, Matthew C Kiernan^c, Jillian J Kri^d, Remika Mito^d, Masami Masuda-Suzukake^e, Masato Hasegawa^e, Heather McCann^a, Lauren Bartley^a, Carol Dobson-Stone^{a,b}, John BJ Kwok^{a,b}, Michael Hornberger^g, John R Hodges^{a,b,f}, Rachel H Tan^{a,b}

^aNeuroscience Research Australia, Sydney, Australia

^bSchool of Medical Sciences, University of New South Wales, Sydney, Australia

^cBrain and Mind Centre, Sydney Medical School, The University of Sydney, Australia

^dDiscipline of Pathology, Sydney Medical School, The University of Sydney, Australia

^eDepartment of Neuropathology and Cell Biology, Tokyo Metropolitan Institute of Medical Science, Japan

^fARC Centre of Excellence in Cognition and its Disorders, Sydney, Australia

^gNorwich Medical School, University of East Anglia, Norwich, UK

Correspondence: Dr Rachel Tan, Neuroscience Research Australia, Barker Street, Randwick NSW 2031, Australia; email: r.tan@neura.edu.au

Running title: TDP-43 in the hypoglossal nucleus in bvFTD

ABSTRACT

The hypoglossal nucleus was recently identified as a key brain region in which the presence of TDP-43 pathology could accurately discriminate TDP-43 proteinopathy cases with clinical amyotrophic lateral sclerosis (ALS). The objective of the present study was to assess the hypoglossal nucleus in behavioral variant frontotemporal dementia (bvFTD), and determine whether TDP-43 in this region is associated with clinical ALS. Twenty-nine cases with neuropathological FTLN-TDP and clinical bvFTD that had not been previously assessed for hypoglossal TDP-43 pathology were included in this study. Of these 29 cases, 41% (n=12) had a dual diagnosis of bvFTD-ALS at presentation, all 100% (n=12) of which demonstrated hypoglossal TDP-43 pathology. Of the 59% (n=17) cohort that presented with pure bvFTD, 35% (n=6) were identified with hypoglossal TDP-43 pathology. Review of the case files of all pure bvFTD cases revealed evidence of possible or probable ALS in 5 of the 6 hypoglossal-positive cases (83%) towards the end of disease, and this was absent from all cases without such pathology. In conclusion, the present study validates grading the presence of TDP-43 in the hypoglossal nucleus for the pathological identification of bvFTD cases with clinical ALS, and extends this to include the identification of cases with possible ALS at end-stage.

Keywords: Amyotrophic lateral sclerosis, behavioural variant frontotemporal dementia, TDP-43, hypoglossal nucleus

1. INTRODUCTION

The TAR DNA-binding protein 43 (TDP-43) in behavioral variant frontotemporal dementia (bvFTD) was recently proposed to have a regional distribution, initiated in the orbitofrontal cortex and amygdala before progressing to the frontal and temporal cortices, eventually involving the motor system, visual cortex and cerebellum [5]. Although the majority of bvFTD cases were found to have TDP-43 pathology in motor system regions, less than half of these demonstrated clinical features suggestive or diagnostic of amyotrophic lateral sclerosis (ALS) [5].

In our recent analysis, the hypoglossal nucleus emerged as a key brain region in which the presence of TDP-43 pathology could accurately discriminate '*TDP-43opathy*' cases with coexistent clinical features of ALS [20]. However, TDP-43 pathology was seen in the hypoglossal nucleus of 13% of the bvFTD cohort assessed [20]. Based on the premise that pathological deposition precedes clinical symptomology [4], the present study set out to determine if bvFTD cases with TDP-43 pathology in the hypoglossal nucleus had developed or were developing ALS by end-stage.

2. MATERIAL AND METHODS

2.1 Case selection. Cases with bvFTD were selected from a neuropathological series of cases collected by the Sydney Brain Bank through regional brain donor programs. The brain donor programs hold approval from the Human Research Ethics Committees of The University of New South Wales, and comply with the statement on human experimentation issued by the National Health and Medical Research Council of Australia. All cases had previously undergone standardized detailed neuropathological characterization [8, 14]. Patients with bvFTD were diagnosed during life by experienced clinicians using standard clinical diagnostic criteria [13, 16] following a medical interview, cognitive testing and an informant history. Standardized tests were used to longitudinally follow patients and controls, with their last assessments performed within 14 months of death. Clinical data were ascertained from an integrated clinical and neuropathological database and by retrospective review of patient clinical files. This research project was approved by the Human Research Ethics Committee of the University of New South Wales. Cases with

neuropathological FTLD-TDP and clinical bvFTD not previously analysed in [20] were included in this study (n=27) as well as two bvFTD cases previously assessed that met clinical criteria for possible ALS by endstage (n=2/22 from [20] Figure 2c). Of these 29 bvFTD cases, 59% (n=17) did not have a clinical diagnosis of possible or probable ALS at onset and are referred to here as 'pure bvFTD' while the others had both bvFTD and possible or probable ALS at onset (n=12, 41%).

2.2 Analysis of TDP-43 pathology in the hypoglossal nucleus. Formalin-fixed, paraffin-embedded tissue blocks of the hypoglossal nucleus were sectioned at 10 µm and immunostained with the anti-phospho TDP-43 monoclonal antibody (1:80 000, TIP-PTD-M01, Cosmo Bio). All slides were counterstained with haematoxylin to visualize neurons and other cells. In cases identified to have TDP-43 cytoplasmic inclusions in the hypoglossal nucleus (Figure 1), TDP-43 immunostaining was also performed on sections from the motor cortex and where available, the spinal cord. The severity of TDP-43 pathology in each section was graded on a four-point severity scale: 0 = no detectable pathology, 1 = mild pathology, 2 = moderate and 3 = frequent pathology. Assessments of TDP-43 pathology were performed by two raters blind to case details with an inter- and intra-rater variance of <5%.

2.3 Severity of upper and lower motor neuron loss. The severity of Betz cell loss in the motor cortex and motor neuron loss in the anterior horn of the spinal cord was graded semi-quantitatively using haematoxylin and eosin stained sections, an Olympus microscope at 100-200x magnification and a 5-point severity scale: 0 = no loss, 1 = mild loss, 2 = moderate loss, 3 = severe loss, 4 = complete loss. Assessments of cell loss were performed by two raters blind to case details with an inter- and intra-rater variance of <5%.

XX Insert Figure 1 here XX

2.4 Genetic analyses.

2.4.1. Frozen tissue. Frozen tissue was available in 75% (n=9) of bvFTD-ALS and 76% (n=12) of pure bvFTD cases, and was screened for genetic mutations (*C9ORF72* and *GRN*) using previously published methods [12, 17].

XX Insert Table 1 here XX

2.4.2. P62 and dipeptide repeat proteins in cerebellum. Formalin-fixed, paraffin-embedded tissue blocks of the cerebellum cortex were available for 67% (n=8) of bvFTD-ALS and 76% (n=13) pure bvFTD cases, and were sectioned at 10 µm, and immunostained with antibodies to p62 (cat #610833, BD Biosciences, 1:500), phosphorylated TDP-43 (TIP-PTD-M01, Cosmo Bio, 1:80 000) and poly-GA (specificity detailed previously [15], courtesy of Prof M Hasegawa, 1:1500). All slides were counterstained with haematoxylin to visualize neurons, and assessments for P62 and dipeptide repeat protein inclusions characteristic of *C9ORF72* expansions [2, 15] were performed at 200-400x magnification.

2.5 Statistical analyses. Statistical analyses were performed using SPSS (IBM SPSS statistics version 21; SPSS Inc.), with p-values < 0.05 taken as significant. Demographic data were plotted and checked for normality of distribution by Kolmogorov-Smirnov tests. Parametric data (age at onset and death, disease duration, postmortem interval, brainstem weight, brain weight) were assessed across participant groups via one-way ANOVA followed by Bonferroni post hoc tests. Variables showing non-parametric distribution were analysed using chi-square analyses (gender, mutation).

3. RESULTS

3.1 TDP-43 pathology in bvFTD cases. TDP-43 cytoplasmic inclusions were identified in the hypoglossal nucleus of 100% (n=12) of the bvFTD-ALS cases and 29% (n=5) of the pure bvFTD cases. Punctate TDP-43 granules similar to that previously described [11] were identified in the hypoglossal nucleus and spinal cord in a further 6% (n=1) of the pure bvFTD cases (Figure 1). All bvFTD cases with TDP-43 pathology in the hypoglossal nucleus (n=6) were found to have TDP-43 pathology in the motor cortex (Table 2) and a further 55% (n=6) of bvFTD cases without TDP-43 pathology in the hypoglossal nucleus demonstrated TDP-43 pathology in the motor cortex.

XX Insert Table 2 here XX

3.2 End-stage ALS in bvFTD cohort. The clinical records of all pure bvFTD cases (n=17) were retrospectively reviewed by a clinical neurologist (MK). Based on the Awaji-shima consensus

recommendations for ALS [10], motor impairment consistent with 'possible' and 'probable' ALS was identified in 24% (n=4) and 6% (n=1) cases respectively, in the final clinical reports performed outside of specialist ALS clinics.

3.3 Evidence of genetic abnormalities in the bvFTD cohort.

3.3.1. Gene screening. Frozen tissue was available in 9/12 bvFTD-ALS cases. A *C9ORF72* expansion was identified in 33% (n=3/9) of the bvFTD-ALS cases and 62% (n=8) of the pure bvFTD cases (Table 1). A *GRN* mutation was identified in 24% (n=4) of the pure bvFTD cases only.

3.3.2. P62 and dipeptide repeat proteins in cerebellum. All bvFTD-ALS (n=5) and pure bvFTD cases (n=9) assessed for both *C9ORF72* expansions in frozen tissue and *C9ORF72*-distinct histopathology in cerebellar sections demonstrated consistent results with both methods. Of the bvFTD-ALS cases without available frozen tissue (3/12), *C9ORF72*-specific cerebellar pathology was identified in 33% bvFTD-ALS (1/3). *C9ORF72*-specific cerebellar pathology was not seen in 67% bvFTD-ALS (n=2) and 100% pure bvFTD cases (n=4).

3.4 Family history

3.4.1. Familial bvFTD. Familial disease was present in 33% (n=4) of bvFTD-ALS and 76% (n=13) of pure bvFTD cases. For bvFTD-ALS, a *C9ORF72* expansion was identified in 75% (n=3/4). Within the familial bvFTD cohort, 62% (n=8/13) demonstrated a *C9ORF72* expansion, 31% (n=4/13) demonstrated a *GRN* mutation, and no mutation was identified in 8% (n=1/13).

3.4.2. Family history of ALS. A family history for ALS was identified in 8% (n=1/12) of bvFTD-ALS cases and 24% (n=4/17) of pure bvFTD cases. All cases with a positive family history for ALS harbored a *C9ORF72* expansion (n=5), and 80% (n=4) demonstrated maternal inheritance.

3.5 Clinicopathological findings. Of the pure bvFTD cases identified to have TDP-43 pathology in the hypoglossal nucleus (n=6), 83% (n=5) corresponded with a retrospective diagnosis of end-

stage possible or probable ALS. The remaining case (n=1) demonstrated no end-stage signs of motor dysfunction although the patient's very slim stature in the final years of disease was of note, particularly since she had been significantly overweight for the majority of the disease course. There was no indication of clinical ALS in 100% (n=11) of the pure bvFTD cases without TDP-43 pathology in the hypoglossal nucleus.

3.6 Demographic features. As can be seen in Table 1, age at disease onset and death, gender and postmortem interval did not differ significantly across bvFTD groups (all p-values > 0.1). Disease duration was significantly shorter in bvFTD-ALS cases compared to pure bvFTD cases as a whole (p < 0.005), but this difference was driven by pure bvFTD cases without TDP-43 pathology in the hypoglossal nucleus (p < 0.005). The frequency of *C9ORF72* expansions was not significant between bvFTD-ALS and pure bvFTD cases as a whole. However, the separation of pure bvFTD cases by TDP-43 pathology in the hypoglossal nucleus revealed a higher frequency of *C9ORF72* expansions in pure bvFTD cases with TDP-43 pathology in the hypoglossal nucleus compared to without (p < 0.05), and this significance held even in comparison to bvFTD-ALS cases (p < 0.05). *GRN* expansions were only identified in pure bvFTD cases without TDP-43 pathology in the hypoglossal nucleus (p < 0.05 compared to other groups). Family history for ALS was more prevalent in pure bvFTD cases with TDP-43 in the hypoglossal nucleus, but this did not reach significance compared to other bvFTD cohorts (p = 0.06).

3.7 Brain and brainstem weights. A comparison of formalin-fixed brain and brainstem weights revealed that pure bvFTD cases without TDP-43 pathology in the hypoglossal nucleus (bvFTD^{hyp-ve}) had a significantly lower weight compared to bvFTD-ALS cases (mean ± standard deviation brain weight: 871.0 ± 146.0 in bvFTD^{hyp-ve}; 1160.8 ± 146.4 in bvFTD-ALS, p < 0.005 between groups; mean ± standard deviation brainstem weight: 23.7 ± 2.9 in bvFTD^{hyp-ve}; 28.0 ± 3.8 in bvFTD-ALS, p < 0.05 between groups), with bvFTD cases with TDP-43 pathology in the hypoglossal nucleus (bvFTD^{hyp+ve}) and end-stage ALS demonstrating an intermediate brain and brainstem weight that was not significantly different from either bvFTD-ALS or bvFTD^{hyp-ve} cases (mean ± standard deviation: 1074.1 ± 181.5 brain weight, 26.0 ± 2.8 brainstem weight, p>0.05 compared to bvFTD-

ALS and bvFTD^{hyp-ve} cases) (Figure 2). There was no interaction between age or mutation carrier with brain and brainstem weights across groups.

XX Insert Figure 2 here XX

4. DISCUSSION

The present study has assessed the hypoglossal nucleus of bvFTD cases for the presence of TDP-43 pathology as an indicator of clinical ALS, and expands on our recent probabilistic statement [20] by establishing that hypoglossal TDP-43 immunoreactivity identifies bvFTD cases with possible ALS. Specifically, TDP-43 cytoplasmic inclusions were identified in the hypoglossal nucleus of 100% bvFTD-ALS cases, and 35% of pure bvFTD cases. A review of the final clinical assessments performed outside of ALS specialist clinics revealed possible or probable ALS [10] in 5 of the 6 (83%) pure bvFTD cases with TDP-43 pathology in the hypoglossal nucleus, but not in any case without TDP-43 pathology in the hypoglossal nucleus. These findings validate grading the presence of TDP-43 cytoplasmic inclusions in the hypoglossal nucleus for the pathological identification of bvFTD cases with clinical ALS, and extend this to include the identification of cases with possible ALS.

End-stage clinical and postmortem histopathological assessments are commonly assigned lesser importance because they represent cross-sectional assessments at the end of a disease course. However, given that pathological changes often precede clinical symptomology [4], the identification of early ALS in FTD cohorts provides a unique platform in which to investigate cases at the interval between the accumulation of underlying histopathological changes and the full manifestation of clinical features. The identification of features characteristic of patients representative of this intermission has important implications for research into preclinical markers of disease. In the present series, 94% of bvFTD cases identified to have TDP-43 pathology in the hypoglossal nucleus demonstrated clinical ALS at some point over the course of their disease. However, 5% showed no signs of motor dysfunction by end-stage despite the deposition of TDP-43 pathology across the spinal cord, hypoglossal nucleus and motor cortex. Importantly, all of the bvFTD cases identified to have TDP-43 pathology in the hypoglossal nucleus and clinical ALS

demonstrated well-formed TDP-43 inclusions whereas the one patient without signs of motor dysfunction by end stage showed only punctate TDP-43 granules. We postulate that this patient developed either rapid end-stage ALS that had not been detected, or came to autopsy prior to this clinical manifestation. However, this could not be ascertained due to the lack of clinical assessments in the final 5 months of this patient's life. Notably however, the patient became very slim in the final years of life and this was distinct given that the patient had been obese for the majority of the disease duration. Although an isolated case, a significant loss in body mass index (BMI) in patients with bvFTD may precede ALS, highlighting the importance of including BMI in longitudinal assessments of patients with bvFTD to end-stage [1].

The recent topographical staging of TDP-43 pathology in bvFTD and ALS [6, 7] demonstrated that TDP-43 initiated in the motor system network in ALS is also seen in the majority of bvFTD cases, despite the absence of ALS in over 50% of these [6, 21]. In a recent analysis [21], we identified the hypoglossal nucleus as a key brain region in discriminating between cases with and without ALS and the present study corroborates this finding in bvFTD cases. Further support for the segregation of bvFTD cases by TDP-43 inclusions in the hypoglossal nucleus was evidenced here by differences in disease duration and postmortem brain weights, with 'intermediate' levels of atrophy in bvFTD cases with end-stage ALS (Figure 2). Motor system degeneration is characteristic of ALS [8] but neuroimaging studies have reported mild and often times variable atrophy in these regions rather than substantial atrophy [3, 9]. In contrast, the brainstem is one of the earliest regions affected in bvFTD due to its considerable non-motor cortical connectivity with cortical regions affected early in the disease [19], Although sampled at the end of disease, the greater brain and brainstem weights seen in bvFTD cases with TDP-43 pathology in the hypoglossal nucleus suggest that structural analyses of brainstem integrity earlier in the disease course may be able to delineate these cases. Unfortunately, neuroimaging scans were not available in this present cohort and the feasibility of this could not be assessed here.

No *GRN* mutations were identified in bvFTD cases with TDP-43 pathology in the hypoglossal nucleus, and this converges with the very low prevalence of *GRN* mutations in ALS [18] to suggest

that *GRN* mutations may identify bvFTD patients that have a lower risk of TDP-43 pathology in the hypoglossal nucleus and clinical ALS. Importantly, 50% of bvFTD cases with TDP-43 pathology in the hypoglossal nucleus harbored a *C9ORF72* expansion and this was particularly prevalent in cases that had not been diagnosed with ALS at presentation (83%), emphasizing the need to follow *C9ORF72*-bvFTD cases longitudinally for early clinical signs of ALS.

In terms of limitations it is accepted that there remains a period of time between the final clinical assessment and patient death, during which further clinical features may have developed.

Although such a time lapse is difficult to circumvent, the replication of our current results in larger cohorts of patients represents an important avenue for future research to ascertain whether TDP-43 pathology in the hypoglossal nucleus precedes clinical ALS symptomology.

In summary, the present study validates the application of our recently proposed probabilistic statement for the pathological identification of TDP-43 proteinopathy cases with a clinical ALS diagnosis, extending this to include cases with possible ALS by end stage. At present, hypoglossal nerve function is not routinely assessed in patients with bvFTD and we suggest the inclusion of simple measures of hypoglossal function and BMI in longitudinal studies of patients with bvFTD, particularly that harbor a *C9ORF72* mutation, in order to identify potential markers of early ALS in these cohorts. Specifically, screening patients with techniques that assess disease involvement, including electromyographic examination of bulbar muscles, may increase the recognition of patients with bvFTD who will develop concurrent ALS. Future clinicopathological assessments in large cohorts of patients with bvFTD that have been well followed longitudinally to end-stage are needed to determine if TDP-43 pathology in the hypoglossal nucleus precedes clinical ALS symptomology and associated markers of early ALS.

ACKNOWLEDGEMENTS

This work was supported by funding to ForeFront, a collaborative research group dedicated to the study of frontotemporal dementia and motor neurone disease, from the National Health and Medical Research Council of Australia (NHMRC) program grant (#1037746) and the Australian Research Council Centre of Excellence in Cognition and its Disorders Memory Node (#CE110001021); RT gratefully acknowledges funding support from the Motor Neurone Disease Research Institute of Australia (#GIA1555); GH is a NHMRC Senior Principal Research Fellow (#1079679). Tissues were received from the Sydney Brain Bank at Neuroscience Research Australia, which is supported by the National Health and Medical Research Council of Australia (NHMRC), University of New South Wales and Neuroscience Research Australia. We thank Heidi Cartwright for assistance with preparation of figures and Carla Scicluna for her technical assistance with the tissue sectioning and immunohistochemistry.

DECLARATION OF INTEREST: The authors report no conflicts of interest.

REFERENCES.

- 1.Ahmed, R.M., et al., *Body mass index delineates ALS from FTD: implications for metabolic health*. J Neurol, 2014. **261**(9): p. 1774.
- 2.Al-Sarraj, S., et al., *p62 positive, TDP-43 negative, neuronal cytoplasmic and intranuclear inclusions in the cerebellum and hippocampus define the pathology of C9orf72-linked FTLN and MND/ALS*. Acta Neuropathol, 2011. **122**(6): p. 691.
- 3.Bae, J.S., et al., *Dissociation of Structural and Functional Integrities of the Motor System in Amyotrophic Lateral Sclerosis and Behavioral-Variant Frontotemporal Dementia*. J Clin Neurol, 2016.
- 4.Bateman, R.J., et al., *Clinical and biomarker changes in dominantly inherited Alzheimer's disease*. N Engl J Med, 2012. **367**(9): p. 795.
- 5.Brettschneider, J., et al., *Sequential distribution of pTDP-43 pathology in behavioral variant frontotemporal dementia (bvFTD)*. Acta Neuropathol, 2014. **127**(3): p. 423.
- 6.Brettschneider, J., et al., *Sequential distribution of pTDP-43 pathology in behavioral variant frontotemporal dementia (bvFTD)*. Acta Neuropathologica, 2014. **127**(3): p. 423.
- 7.Brettschneider, J., et al., *Stages of pTDP-43 Pathology in Amyotrophic Lateral Sclerosis*. Annals of Neurology, 2013. **74**(1): p. 20.
- 8.Brooks, B.R., et al., *El Escorial revisited: revised criteria for the diagnosis of amyotrophic lateral sclerosis*. Amyotroph Lateral Scler Other Motor Neuron Disord, 2000. **1**(5): p. 293.
- 9.Chen, Z., et al., *Grey matter volume changes over the whole brain in amyotrophic lateral sclerosis: A voxel-wise meta-analysis of voxel based morphometry studies*. Amyotroph Lateral Scler, 2010. **11**(6): p. 549.
- 10.de Carvalho, M., et al., *Electrodiagnostic criteria for diagnosis of ALS*. Clin Neurophysiol, 2008. **119**(3): p. 497.
- 11.Dickson, D.W., et al., *TDP-43 in differential diagnosis of motor neuron disorders*. Acta Neuropathol, 2007. **114**(1): p. 71.
- 12.Dobson-Stone, C., et al., *C9ORF72 repeat expansion in Australian and Spanish frontotemporal dementia patients*. PLoS One, 2013. **8**(2): p. e56899.
- 13.Kiernan, M.C., et al., *Amyotrophic lateral sclerosis*. Lancet, 2011. **377**(9769): p. 942.
- 14.Mackenzie, I.R., et al., *A harmonized classification system for FTLN-TDP pathology*. Acta Neuropathol, 2011. **122**(1): p. 111.
- 15.Mann, D.M., et al., *Dipeptide repeat proteins are present in the p62 positive inclusions in patients with frontotemporal lobar degeneration and motor neurone disease associated with expansions in C9ORF72*. Acta Neuropathol Commun, 2013. **1**: p. 68.
- 16.Rascovsky, K., et al., *Sensitivity of revised diagnostic criteria for the behavioural variant of frontotemporal dementia*. Brain, 2011. **134**(Pt 9): p. 2456.
- 17.Schofield, E.C., et al., *Low serum progranulin predicts the presence of mutations: a prospective study*. J Alzheimers Dis, 2010. **22**(3): p. 981.
- 18.Schymick, J.C., et al., *Progranulin mutations and amyotrophic lateral sclerosis or amyotrophic lateral sclerosis-frontotemporal dementia phenotypes*. J Neurol Neurosurg Psychiatry, 2007. **78**(7): p. 754.
- 19.Seeley, W.W., et al., *Frontal paralimbic network atrophy in very mild behavioral variant frontotemporal dementia*. Archives of Neurology, 2008. **65**(2): p. 249.
- 20.Tan, R.H., et al., *TDP-43 proteinopathies: pathological identification of brain regions differentiating clinical phenotypes*. Brain, 2015.
- 21.Tan, R.H., et al., *TDP-43 proteinopathies: pathological identification of brain regions differentiating clinical phenotypes*. Brain, 2015. **138**(Pt 10): p. 3110.

	bvFTD-ALS	bvFTD	bvFTD ^{hyp-ve}	bvFTD ^{hyp+ve}
N (% male)	12 (58%)	17 (59%)	11 (64%)	6 (50%)
Age at onset	64 ± 8	61 ± 7	62 ± 8	59 ± 6
Age at death	66 ± 8	67 ± 7	69 ± 8	65 ± 6
Disease duration	2 ± 1 ^a	6 ± 4 ^d	7 ± 4	5 ± 4
Postmortem interval	29.5 ± 15.7	21.4 ± 17.0	16.8 ± 13.8	29.7 ± 20.5
C9ORF72 carrier	33% ^b	47%	27% ^b	83%
GRN carrier (% screened)	0% ^c	24%	36%	0% ^c
Familial bvFTD (% cohort)	33%	76% ^e	73% ^f	83% ^f
Family history of ALS	8%	24%	9%	50%
TDP subtype (A/B/C/D)	6/6/0/0	10/5/2/0	6/3/2/0	4/2/0/0

Table 1. Demographic features across bvFTD-ALS, bvFTD cases as a whole, and separated into cases with TDP-43 in the hypoglossal nucleus (bvFTD^{hyp+ve}) and without bvFTD^{hyp-ve}. ^a p<0.005 compared to bvFTD^{hyp-ve}, ^b p<0.05 compared to bvFTD^{hyp+ve}, ^c p<0.05 compared to bvFTD^{hyp-ve}, ^d p<0.005 compared to bvFTD-ALS, ^e p<0.05 compared to bvFTD-ALS, ^f p=0.06 compared to bvFTD-ALS

#	M /F	AD (y)	AO (y)	DD (y)	TDP in HYP	Hyp cell loss	MC hem	TDP in MC	Betz cell TDP	Betz cell loss	TDP in SC	SC cell loss	TDP type	C9 (frozen tissue)	C9 CB path	ALS hist	Final clinical records within 12 months of death unless otherwise specified	Retro dx
1	F	65	62	3	+++	+++	R	++	+	++	n/a	n/a	A	Yes	Yes	Yes, mat	Pseudobulbar palsy	Possible ALS
2*	M	65	63	2	+	++	L	+++	+	++	n/a	n/a	A	Yes	Yes	No	Weakness and wasting of arms	Possible ALS
3	M	66	60	5	+	++	L	++	++	+	n/a	n/a	B	Yes	Yes	No	Dysphagia	Possible ALS
4	F	55	53	2	++	+++	L	++	+++	0	n/a	n/a	B	n/a	No	No	Within 6 months of death: dysarthria, dysphagia, limb fasciculation and weakness, rapid disease progression, lost 12 kg over 5 months	Probable ALS
5*	M	63	50	7	++	+	L	+	0	0	n/a	n/a	A	Yes	Yes	Yes, mat	Weakness in left foot and left hip	Possible ALS
6	F	75	63	12	+	+	R	+	+	0	GCl: +++ NCl: +	+	A	Yes	Yes	Yes, mat	No signs of motor dysfunction recorded, patient's slim stature notable since she had been significantly overweight for the majority of the disease	No clinical ALS

Table 2. Demographic, pathological, genetic and clinical features of bvFTD cases identified to have TDP-43 in the hypoglossal nucleus. AD:

Age death, AO: Age onset, DD: disease duration, *C9: C9ORF72*, CB path: Cerebellar pathology, HYP: hypoglossal nucleus, MC: motor cortex, SC: spinal cord, hem: hemisphere, CB: cerebellum, Ubi/DPR +ve: ubiquitin/dipeptide repeat protein positive, TDP-ve: TDP-43 negative, GCI: granular cytoplasmic inclusions, NCI: neuronal cytoplasmic inclusion, ALS hist: family history of ALS, mat: maternal, retro dx: retrospective diagnosis, n/a: not available. Histopathological changes were rated on a 4-point scale: 0 absent, + mild, ++ moderate, +++ severe. *Cases previously assessed [20].

Figure 1. TDP-43 in the hypoglossal nucleus and spinal cord of bvFTD cases. TDP-43 cytoplasmic inclusions (A top inset, case #1, B, case#4), punctate TDP-43 granules (A bottom inset, C) and TDP-43 glial inclusions (A) were identified in the hypoglossal nucleus of bvFTD cases. In one case (C, case #6), only punctate TDP-43 granules were present in the hypoglossal nucleus, and numerous TDP-43 granules with one cytoplasmic inclusion were observed in the spinal cord (D, case #6).

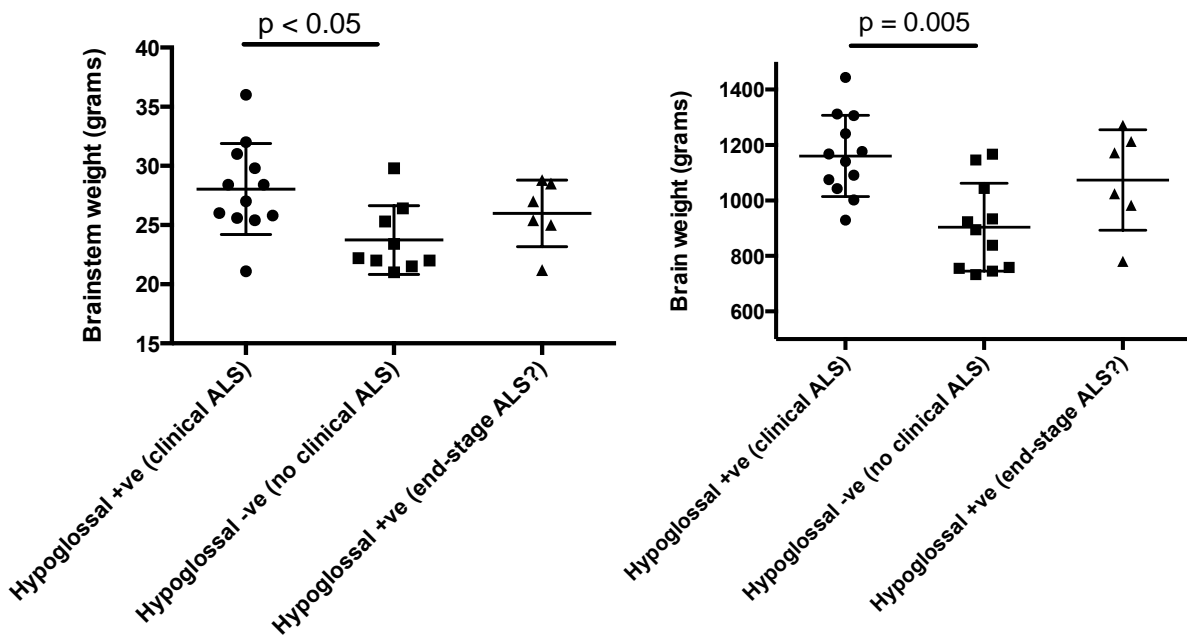


Figure 2. Brain and brainstem weights across bvFTD cases with TDP-43 in the hypoglossal nucleus and clinical ALS at presentation, bvFTD cases without TDP-43 in the hypoglossal nucleus and no evidence of ALS, and bvFTD cases with TDP-43 in the hypoglossal nucleus and clinical ALS at end-stage. Group comparisons revealed a significant difference between bvFTD cases with TDP-43 in the hypoglossal nucleus and clinical ALS compared to bvFTD cases without TDP-43 in the hypoglossal nucleus nor clinical ALS. BvFTD cases with TDP-43 in the hypoglossal nucleus found to have ALS at end-stage demonstrated intermediate brain and brainstem weights not significantly different from the other two cohorts.