

Original Investigation

A Thalamocortical Mechanism for the Absence of Overt Motor Behavior in Covertly Aware Patients

Davinia Fernández-Espejo, PhD; Stephanie Rossit, PhD; Adrian M. Owen, PhD

IMPORTANCE It is well accepted that a significant number of patients in a vegetative state are covertly aware and capable of following commands by modulating their neural responses in motor imagery tasks despite remaining nonresponsive behaviorally. To date, there have been few attempts to explain this dissociation between preserved covert motor behavior and absent overt motor behavior.

OBJECTIVES To investigate the differential neural substrates of overt and covert motor behavior and assess the structural integrity of the underlying networks in behaviorally nonresponsive patients.

DESIGN, SETTING, AND PARTICIPANTS A case-control study was conducted at an academic center between February 7, 2012, and November 6, 2014. Data analysis was performed between March 2014 and June 2015. Participants included a convenience sample of 2 patients with severe brain injury: a paradigmatic patient who fulfilled all clinical criteria for the vegetative state but produced repeated evidence of covert awareness (patient 1) and, as a control case, a patient with similar clinical variables but capable of behavioral command following (patient 2). Fifteen volunteers participated in the study as a healthy control group.

MAIN OUTCOMES AND MEASURES We used dynamic causal modeling of functional magnetic resonance imaging to compare voluntary motor imagery and motor execution. We then used fiber tractography to assess the structural integrity of the fibers that our functional magnetic resonance imaging study revealed as essential for successful motor execution.

RESULTS The functional magnetic resonance imaging study revealed that, in contrast to mental imagery, motor execution was associated with an excitatory coupling between the thalamus and primary motor cortex (Bayesian model selection; winning model Bayes factors >17). Moreover, we detected a selective structural disruption in the fibers connecting these 2 regions in patient 1 (fractional anisotropy, 0.294; $P = .047$) but not in patient 2 (fractional anisotropy, 0.413; $P = .35$).

CONCLUSIONS AND RELEVANCE These results suggest a possible biomarker for the absence of intentional movement in covertly aware patients (ie, specific damage to motor thalamocortical fibers), highlight the importance of the thalamus for the execution of intentional movements, and may provide a target for restorative therapies in behaviorally nonresponsive patients.

JAMA Neurol. doi:10.1001/jamaneurol.2015.2614
Published online October 19, 2015.

← Editorial

+ Supplemental content at
jamaneurology.com

Author Affiliations: Brain and Mind Institute, University of Western Ontario, London, Ontario, Canada (Fernández-Espejo, Owen); School of Psychology, University of Birmingham, Birmingham, England (Fernández-Espejo); School of Psychology, University of East Anglia Norwich, Norwich, England (Rossit).

Corresponding Author: Davinia Fernández-Espejo, PhD, School of Psychology, 3.43 Hills Bldg, University of Birmingham, Edgbaston, Birmingham B15 2TT, England (d.fernandez-espejo@bham.ac.uk).

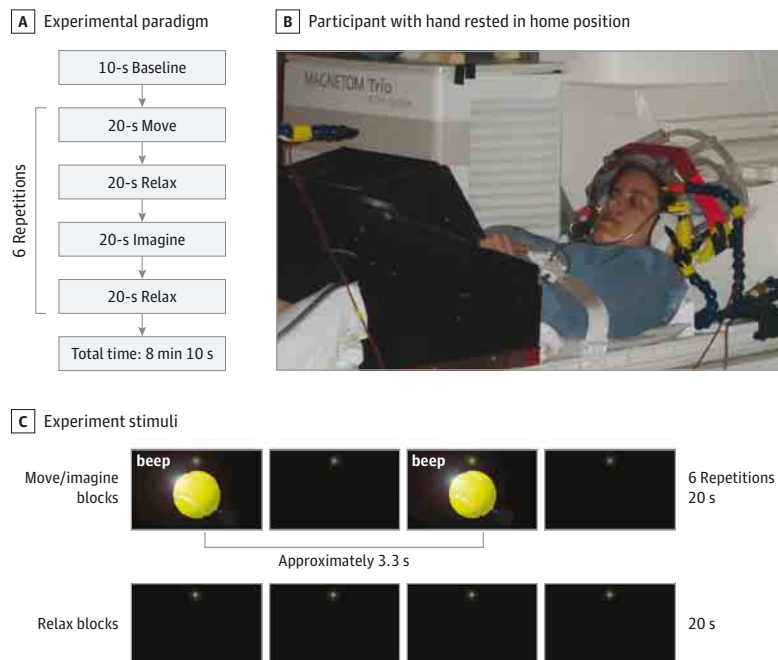
Patients in a vegetative state are considered by current clinical standards to be unconscious because they show no spontaneous purposeful behaviors and produce no responses to verbal commands.^{1,2} Nevertheless, it is now well accepted that a subset of covertly aware patients exists who will escape detection, even after repeated and rigorous behavioral assessments by experienced teams. In these patients, clear signs of awareness can be demonstrated using neuroimaging techniques that do not rely on an ability to produce an external response.³ A commonly used approach is to instruct patients to imagine a motor command (eg, swinging their arm back and forth to hit a tennis ball) while their neural responses are recorded with functional magnetic resonance imaging (fMRI) or electroencephalography (EEG).³ The neural responses to command provide a proxy for a motor action; hence, the responses can be interpreted as evidence of covert command following and, therefore, awareness.

The clinical and scientific communities have yet to agree on the appropriate diagnostic label for such covertly aware patients⁴ (henceforth referred to as *covertly aware*), and, to our knowledge, there have been no attempts to explain their paradoxical abilities. Imagining a motor action (eg, hitting a tennis ball) and performing the same motor action (henceforth referred to as *motor imagery* and *motor execution*, respectively)

are assumed to be partially overlapping processes that engage similar brain networks.⁵ A reasonable prediction then would be that a patient who is capable of imagining acting should also be able to act. Covertly aware patients, however, challenge this prediction.

There is growing evidence from both postmortem and in vivo structural MRI studies⁶⁻¹¹ suggesting that the thalamus, including its projections to the cortex, is an important neuropathologic component of the vegetative state and related disorders of consciousness. On the basis of this evidence and the well-studied connections between the thalamus and motor cortical areas,¹² along with the recently proposed role of the thalamus in motor control,¹³ we hypothesized that a dysfunction in motor thalamocortical circuits would explain the absence of external responsiveness in covertly aware patients. To test this hypothesis, we first conducted an fMRI study and generated a dynamic causal model¹⁴ to explain differences in the activation of the thalamus and motor cortical regions between motor imagery and execution. Fifteen healthy volunteers were asked to either move their hand to hit a tennis ball in front of them or imagine they were performing the same movement (Figure 1). Consistent with our hypothesis, Bayesian model selection¹⁵ indicated that excitatory outputs from the thalamus to the primary motor cortex (M1) were crucial for execut-

Figure 1. Experimental Design and Setup



A, Participants alternated blocks of motor imagery, motor execution, and rest for a total of 8 minutes 10 seconds while lying in the functional magnetic resonance imaging scanner. The beginning of each block was cued by the auditory words move, imagine, and relax. B, The participants lay supine with their head tilted to enable direct viewing of the hand workspace without mirrors. A combination of phased array coils collected whole-brain volumes. A real tennis ball was presented on a wooden platform. The upper arm was restrained such that movements could be made with the elbow. Between actions, the hand rested in a comfortable home position (as shown). Flexible stalks were used to position a fixation point, illuminator, and a magnetic

resonance-compatible camera to record hand movements. Auditory cues regarding the tasks were presented through headphones. C, Throughout the experiment, the room was maintained in complete darkness and the participants were instructed to keep their eyes on the fixation point. During the motor imagery and motor execution blocks, the participants were instructed to move their right hand to hit the tennis ball in front of them or imagine that movement along with the sound of beeps, for a total of 6 times in each block. At the beginning of each trial, the tennis ball was briefly illuminated (250 milliseconds) to facilitate the task while ensuring no visual feedback for the actual hand movement.

ing these movements. Based on these results, in a second study we used diffusion tensor imaging (DTI) tractography to identify a severe and selective impairment in the structural integrity of the fibers connecting the thalamus and M1 in a patient who was repeatedly able to perform motor imagery tasks on command but was unable to produce purposeful movements.^{3,16-18}

Methods

Participants

Fifteen right-handed, healthy volunteers (mean [SD] age, 23.6 [3] years; 9 men) took part in the fMRI and DTI studies. None of the volunteers declared any history of neurologic or psychiatric disease.

Two patients with traumatic brain injury were included in the DTI study. Patient 1 was selected from a convenience sample of 19 patients with disorders of consciousness based on his clinical diagnosis (ie, vegetative state), consistent lack of behavioral command following in repeated assessments, and reliable evidence of covert awareness and communication ability across multiple independent fMRI and EEG assessments.^{3,16-18} Patient 2 was selected from the same convenience sample to match patient 1's etiology (ie, traumatic brain injury) and time after injury but to have reliable behavioral evidence of command following. Specifically, she was capable of using her right upper limb to reach for different objects in response to the examiner's instructions, to functionally use common objects, such as a cup or a comb, and to gesture accurate answers to situational orientation questions. In addition, during her visit to our center, patient 2 was assessed with 2 mental imagery tasks as previously described.^{18,19} Although we failed to detect statistically significant evidence of motor imagery, we identified robust markers of mental navigation. There is no way to independently confirm whether the lack of activity in the motor imagery task was the result of the imaging approach (ie, false-negative) or truly represented a failure to carry out motor imagery (ie, true-negative).²⁰ Functional MRI evidence aside, the external capabilities of patient 2 closely mirrored the covert capabilities of patient 1, who could imagine right arm movements in response to command and use them to communicate in the scanner, and made patient 2 an excellent control case for the study of the neural substrates that prevent individuals from voluntarily controlling their motor behavior.

The initial 19-patient cohort included all patients who underwent fMRI scanning between February 7, 2012, and November 6, 2014, as part of a research study conducted at the University of Western Ontario. Independent functional and structural datasets from subsets of this cohort have been previously reported.^{3,16-18,21} Inclusion criteria for the study required adults with a diagnosis of chronic disorder of consciousness or emerging from the minimally conscious state at the time of the study. The only exclusion criterion was unsuitability to enter the MRI environment. Clinical and behavioral data on both patients can be found in eTable 1 in the [Supplement](#).

The University of Western Ontario's Health Sciences Research Ethics Board provided ethical approval for the study.

All healthy volunteers gave written informed consent and were paid for their participation. The brain-injured patients' surrogate decision makers gave written informed assent; patients were not financially compensated.

fMRI Paradigm and Experimental Setup

While in the fMRI scanner, participants were instructed to either move their right hand to hit a tennis ball, which was placed on a wooden platform in front of them, or to imagine the same movement. Imagery and execution blocks were 20 seconds long and alternated with 20-second periods of rest for a total of 8 minutes 10 seconds (including an initial 10 seconds at baseline) (Figure 1). The beginning of each block was cued with the words "move," "imagine," or "relax." Within each action block the participant was instructed to perform or imagine the action 6 times at the sound of beeps. All participants completed 2 runs of this task. The eMethods in the [Supplement](#) gives a full description of the experimental setup.

MRI Acquisition

Data were acquired in a 3-T scanner (Magnetom Trio Tim; Siemens) at the Centre for Functional and Metabolic Mapping at Robarts Research Institute. For the fMRI study, we used a combination of parallel imaging coils to achieve a good signal to noise ratio and enable direct viewing without mirrors or occlusion. We tilted (approximately 20°) the posterior half of a 32-channel head coil (16 channels) and suspended a 4-channel receive-only flex coil over the anterior-superior part of the head.

The fMRI protocol included 2 sessions of 245 volumes using echo-planar images (repetition time [TR], 2000 milliseconds; echo time [TE], 30 milliseconds; matrix size, 70 × 70; section thickness, 3 mm; in-plane resolution, 3 × 3 mm; and flip angle, 78°). Each volume comprised 36 sections angled at an approximate 30° caudal tilt with respect to the anterior to posterior commissure line, providing near whole-brain coverage. A high-resolution, T1-weighted, 3-dimensional magnetization prepared rapid acquisition gradient echo image was also acquired (TR, 2300 milliseconds; TE, 2.98 milliseconds; inversion time, 900 milliseconds; matrix size, 256 × 240; voxel size, 1 × 1 × 1 mm; and flip angle, 9°). The task instructions and cues were presented using an MRI-compatible high-quality digital sound system incorporating noise-attenuated headphones (Silent Scan; Avotec Inc).

Diffusion-weighted images were acquired in the same scanner but with use of the standard configuration of the 32-channel head coil. Images included diffusion-sensitizing gradients applied along 64 noncollinear directions with a b value of 700 s/mm² (TR, 8700 milliseconds, TE, 77 milliseconds, matrix size, 96 × 96; 77 sections; section thickness, 2 mm; and no gap).

fMRI Preprocessing and General Linear Model Analysis

Data analysis was performed between March 2014 and June 2015. We first performed an independent component analyses-based artifact removal²² to eliminate potential undesirable effects of task-related motion in the activation maps (eMethods in the [Supplement](#)). After removal of noise, the data were then preprocessed and analyzed using SPM8 (<http://www.fil.ion.ucl.ac.uk/spm>). Spatial preprocessing included realignment

Table. Random Effects Group Analysis^a

Region	P Value for Cluster (FWE Corrected)	T Value	MNI x, y, z Coordinates	Contrast
SMA	<.001	9.301	-6, -4, 67	MI
M1	<.001	12.225	-27, -13, 64	ME
Thalamus	.012	5.706	-12, -22, 4	ME

Abbreviations: FWE, familywise error; M1, motor cortex; ME, motor execution vs rest; MI, motor imagery vs rest; MNI, Montreal Neurological Institute; SMA, supplementary motor area.

^a The MNI coordinates and T values of the local maximum of each group general linear model activation for the regions included in the dynamic causal modeling analyses are presented.

to correct the participants' motion, coregistration between the structural and functional data sets, spatial normalization, and smoothing with an 8-mm full width at half maximum gaussian kernel. Single-participant fixed-effect analyses were performed in each person using a general linear model, which included motor imagery and motor execution as regressors of interest, plus realignment factors as effects of noninterest to account for residual motion-related variance. Contrast images were created for each participant and entered separately into voxelwise 1-sample, 1-tailed *t* tests. The statistical threshold was set at a familywise error (FWE)-corrected $P < .05$ on the following regions of interest: left supplementary motor area (SMA), precentral gyrus, and thalamus, using WFU PickAtlas. Regions of interest were obtained from the Automated Anatomical Labeling atlas.²³

Dynamic Causal Modeling

We used dynamic causal modeling (DCM) to explore the neural dynamics underlying the differences reported above. Dynamic causal modeling is a generic Bayesian framework for inferring hidden (unobserved) neuronal states from measured brain activity.^{14,24} The main objective of the present study was to assess potential differences in effective connectivity between the thalamus and cortical motor areas in motor imagery vs execution. Based on our general linear model results, we constructed a basic 3-area model including the left M1, SMA, and thalamus. The stimuli (task) entered the model by directly affecting the SMA, M1, and thalamus (following a similar approach used in a previous study²⁵). Then, based on known cytoarchitecture from human and animal work²⁶⁻³² (eMethods in the Supplement), the induced activity was allowed to spread along reciprocal connections between the SMA and thalamus, between the thalamus and M1, and a forward-only connection from the SMA to M1 (eFigure 1A in the Supplement). Furthermore, we generated a second family of models that included a direct backward connection from the M1 to SMA to test our models' assumptions about underlying structure (eMethods in the Supplement). Motor execution or imagery was allowed to modulate the strength of all possible combinations of connections and the activity of all possible combinations of areas. This procedure resulted in 496 models in the first family (eFigure 1B and C in the Supplement) and 1008 in the second family.

Although others have recommended the study of constrained model spaces,³³ the reasons have been primarily practical²⁴ and not statistical. (See Kruschke³⁴ for a detailed discussion of Bayesian statistics.) A comprehensive model space such as ours is advantageous during model comparison because it allows multiple explanations of the data to be tested explicitly.³⁵

Families were first compared using Bayesian family inference.³⁶ The models in the winning family were then evaluated using Bayesian model selection.¹⁵ The DCM-derived coupling factors for the winning model were tested for statistical significance using a 1-sample *t* test ($P < .05$).

DTI Data Analysis

Images were preprocessed using the FMRIB Software Library (<http://www.fmrib.ox.ac.uk/fsl/>) as described elsewhere.¹⁰ Fractional anisotropy (FA) maps were obtained, and diffusion modeling and probabilistic tractography were carried out using FMRIB's Diffusion Toolbox.³⁷ Fiber tracking was estimated for each participant between the thalamus and M1 as well as the thalamus and SMA (eMethods in the Supplement).

Mean FA values for the obtained paths connecting the thalamus with the M1 and SMA were calculated and used to quantify and compare the integrity of the identified paths. We used Crawford's Bayesian standardized difference test³⁸ to look for dissociations in the damage of the target pathways (ie, thalamus to M1 and thalamus to SMA) in each patient. This test allows for robust statistical comparisons between individual measures and norms derived from a control sample.³⁸ Given our a priori directional hypothesis, all tests were 1-tailed, with significance at $P < .05$. Graphs were produced using Matlab, version 2013a (The MathWorks Inc).

Results

Differential Neural Activity During Motor Imagery and Motor Execution

Group-level, random-effects, 1-sample *t* tests performed on the fMRI data revealed significant clusters of neural activity in the left precentral gyrus and left juxtastriatal lobule, representing the M1 and SMA, respectively, as well as the left thalamus, for the blocks in which the participants were moving their right hand to hit the tennis ball (ie, motor execution). Motor imagery (ie, imagining moving their hand to hit the tennis ball) also elicited activity in the SMA and M1 but not in the thalamus ($P < .05$ FWE corrected) (Table). When motor execution and motor imagery were directly compared, both the left M1 and thalamus showed increased activity for motor execution ($P < .05$ FWE corrected) (Figure 2 and eTable 2 in the Supplement).

Construction of Dynamic Causal Models and Bayesian Model Selection

The optimal family was found to be the one without a backward connection from the M1 to SMA (eFigure 2 in the Supple-

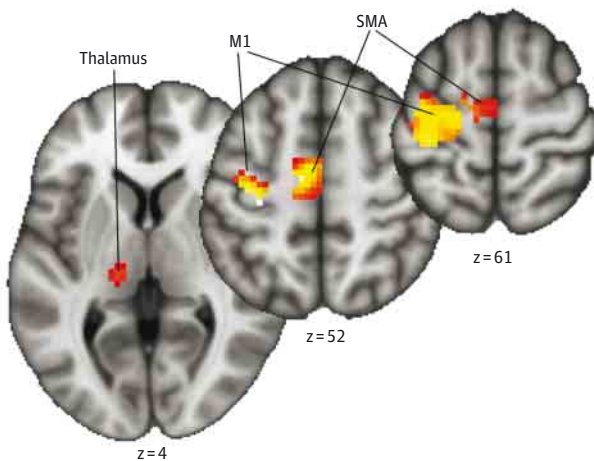
ment) in accordance with known cytoarchitecture. The 496 models in the winning family were evaluated using Bayesian model selection.¹⁵ The optimal model was found to be the one in which motor execution exerted a direct influence on the thalamus and a modulatory influence on the connection from the thalamus to M1 (Bayes factors >17) (Figure 3). Bayesian factors for all evaluated models are displayed in eFigure 3 in the Supplement.

The analysis of this optimal model showed that, when the participants moved their right hand (in contrast to imagining moving it), neural activity in the left M1 was driven by a sig-

nificant enhancement of the excitatory influence exerted by the left thalamus ($P < .05$) (eTable 3 in the Supplement includes variables and P values).

The 496 models were evenly divided into those modulated by motor imagery and those modulated by motor execution. Bayesian factors showed a clear trend toward the group of models modulated by motor execution (eFigure 3 in the Supplement), indicating that the change in activity in the thalamus and M1 is more likely to be caused by an excitatory influence during execution than an inhibitory influence during imagery.

Figure 2. Group General Linear Model Differences Between Motor Imagery and Execution



Compared with motor imagery, motor execution generated higher activation in all 3 regions of interest studied: the supplementary motor area (SMA), primary motor cortex (M1), and thalamus. For display purposes, activation maps are shown at an uncorrected value of $P < .01$ and rendered on a single-participant T1-weighted image (eTable 2 in the Supplement presents participant-specific coordinates corresponding to the regions listed above). z indicates the Montreal Neurological Institute z correlate; color scale, t statistic values.

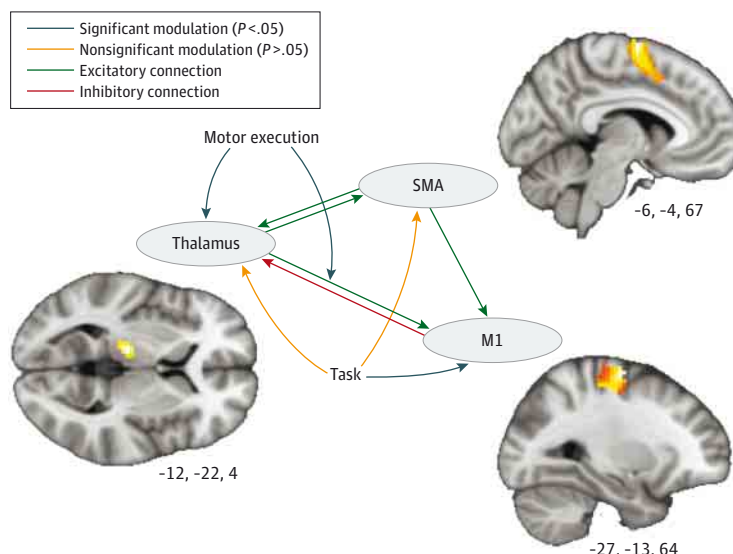
Structural Integrity of the Fibers Connecting the Thalamus to M1 in the Covertly Aware Patient

We were able to reconstruct both tracts in all participants (Figure 4A). Mean FA was used as a measure of the structural integrity of the tracts. We used the Bayesian standardized difference test³⁸ to look for a dissociation between the damage in the 2 studied pathways in each patient relative to the healthy volunteers. Patient 1 showed a significant dissociation, with more marked damage in the fibers connecting the thalamus and M1 compared with the thalamus and SMA (patient 1 FA, 0.294 vs 0.357; healthy volunteers mean [SD] FA, 0.455 [0.021] vs 0.443 [0.024]; $P = .047$). In contrast, the damage in these 2 fiber paths was not significantly dissociable in patient 2 (FA, 0.413 vs 0.428; $P = .35$) (Figure 4B). Additional analyses showed similar results for the right hemisphere.

Discussion

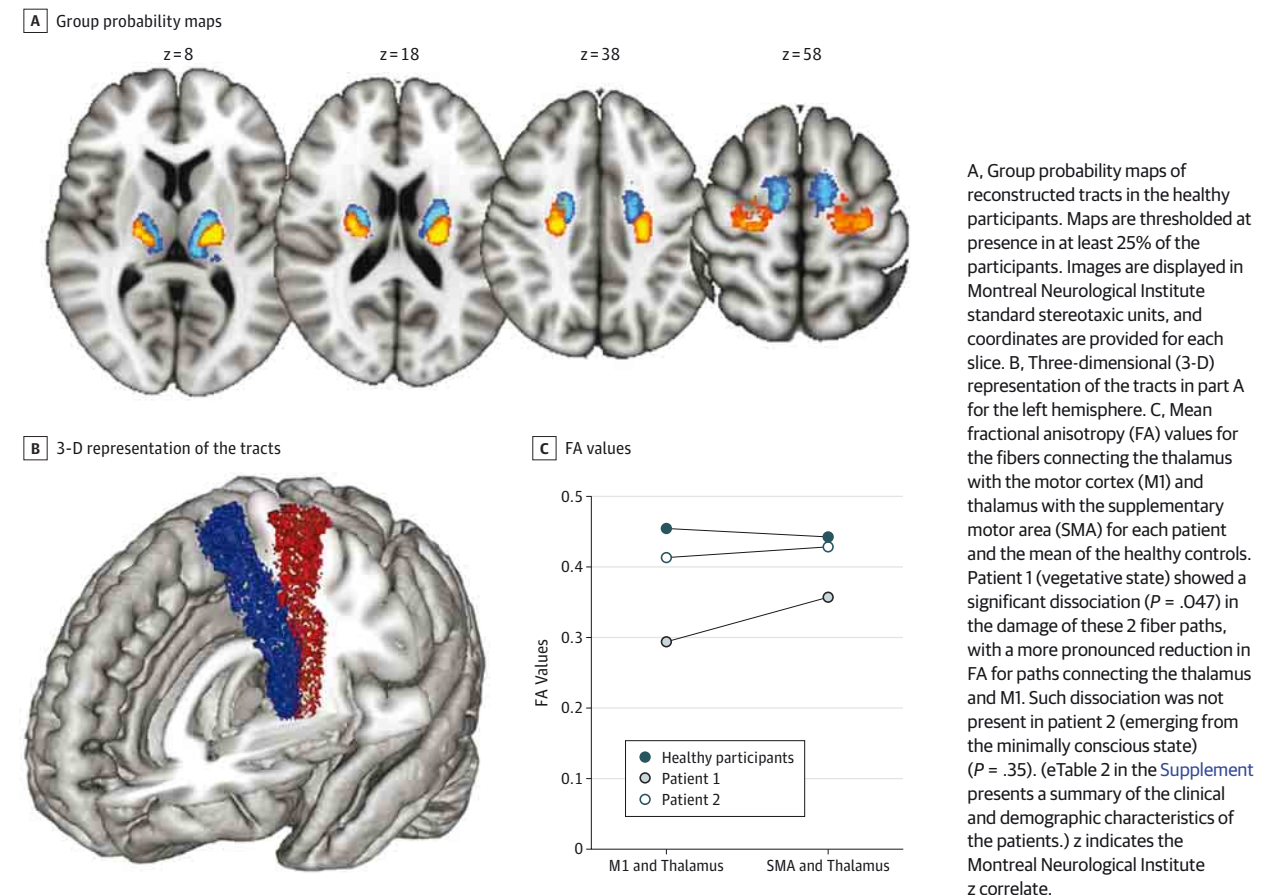
Our findings provide, for what we believe to be the first time, a neural explanation for the lack of purposeful motor behavior in covertly aware patients. Dynamic causal modeling of fMRI data demonstrated that the thalamus to M1 connection is essential for the execution of purposeful movements in healthy

Figure 3. Summary of the Group Results for Optimal Dynamic Causal Model



This model indicates that the motor execution task modulates the excitatory outputs from the thalamus to the motor cortex (M1) as well as the thalamus itself. The insets display the results from the random-effects general linear model analysis together with the group coordinates of the regions included in the model: the supplementary motor area (SMA), primary motor cortex (M1), and thalamus. Activations are shown at a threshold of familywise error-corrected $P < .05$ (eTable 3 in the Supplement presents participant-specific factors). Groups of 3 numbers indicate Montreal Neurological Institute x , y , and z correlates; color scale, t statistic values.

Figure 4. Summary of the Diffusion Tensor Imaging Tractography Results



individuals. Furthermore, in a paradigmatic case of a paradoxically aware patient with a clinical diagnosis of vegetative state,³ we identified a selective structural damage to the white matter fibers connecting the thalamus and M1 bilaterally. Crucially, such damage was not present in a second patient with a similar clinical history but who was capable of overt command following.

We cannot rule out the presence of additional intermediate relay regions in our DCM model²⁴; however, there is strong evidence that supports a direct anatomical connection between the thalamus and M1.^{26-30,39} It is also known¹² that the thalamus modulates the motor cortex via direct afferent outputs, but corticothalamic modulations have a basal ganglia relay. In this context, it is reasonable to assume that the fibers we reconstructed with our tractography methods in both the healthy volunteers and patients are those that carry ascendant information to the cortex. Structural damage to these fibers would thus be disrupting the flow of information from the thalamus to M1 and abolishing the patient's ability to voluntarily execute a motor command. This finding is in agreement with studies⁴⁰⁻⁴³ in other neurologic groups, such as patients with stroke, that have identified an association between the structural and functional connectivity of the thalamus and M1 and the patients' motor deficits. Furthermore, this finding on the effect of structural damage is consistent with evidence of

some covertly aware patients activating premotor regions but not primary motor cortex when asked to try to move.^{16,44}

For decades, studies of motor imagery and execution in both healthy volunteers and patient populations indicated overlapping activation patterns.⁴⁵ However, the recent development of effective connectivity methods (eg, graph theory or DCM) has allowed for a more detailed study of the regional dynamics within motor networks.⁴⁶ Specifically, the SMA has been proven to exert a task-dependent inverse influence over the M1: excitatory during motor execution and inhibitory during motor imagery.^{25,47-49} However, to our knowledge, the contribution of subcortical structures, in particular, the thalamus, to such differential dynamics had not been studied. Our fMRI results provide further evidence for dissociable network dynamics during motor imagery and execution and highlight the role of the thalamus as a relay in the excitation of the M1 during motor execution.

Some authors^{50,51} have used the historical notion of motor imagery and execution equivalency to argue that the neural responses elicited during fMRI motor imagery paradigms in otherwise nonresponsive patients do not reflect volition on the part of the patient. Our fMRI results, however, contradict such claims: if voluntary motor imagery and execution are dissociable processes, it is conceivable that one may be maintained in the absence of the other. Shea and Bayne⁵² have ar-

gued that damage to the peripheral nervous system as well as muscular contractures could be limiting these patients' mobility and explaining their absence of motor responses. Although such damage is present in most patients in a vegetative state^{53,54} and may contribute to their motor deficits, the damage cannot account for the lack of voluntary motor control since frequent spontaneous movements are characteristic of such patients. Our DTI results, however, provide a direct neural correlate for these patients' inability to execute an intended movement and, in doing so, further support the use of fMRI responses as a proxy for behavioral command following and awareness.

Widespread severe white matter and thalamic damage are the most important neuropathologic findings in patients in a posttraumatic vegetative state.^{8,53,55} Nonetheless, patient 1 showed selective damage to the thalamus to M1 pathway, which went above and beyond a more global injury and did not affect the neighboring fibers connecting the thalamus with the SMA to the same extent. The specific mechanisms underlying the selectivity of this damage remain the subject of further investigation. Previous studies^{26,39} demonstrated a topographic differentiation in the origin of thalamic inputs to the SMA and M1 within the ventrolateral thalamic nuclei, which could lead to differences in vulnerability to injury. However, strong evidence^{6,7,9,56} indicates that the dorsomedial nucleus of the thalamus has the most severe damage in patients in a vegetative state. This nucleus is known to be the origin of fibers projecting to associative regions in the frontal cortex.⁴⁰ One of the most recently proposed models^{57,58} describes the lack of awareness in the vegetative state as a result of a downregulation of frontoparietal networks caused by metabolic suppression of the central thalamus, including the dorsomedial nucleus and internal medullary lamina. Furthermore, the investigators reported a relatively preserved metabolism in motor thalamocortical networks. Our results complement this model in suggesting that 2 separate clinical syndromes may arise as a result of subtle regional differences in the patterns of thalamocortical damage after brain injury: a true vegetative state would occur following damage to the central thalamus and its projections, and the still-unnamed condition of covert awareness with absent physical responses would be caused by damage to the ventrolateral thalamus and its projections. Further investigations in larger groups of patients will confirm whether damage to the thalamocortical network involved in motor control is the primary underlying mechanism of this condition.

Several limitations should be considered when interpreting our findings. First, the DCM results were obtained from a small sample of 9 individuals in whom we could identify suprathreshold activity in the contrast between motor execution and motor imagery in all 3 regions of interest and scanning runs. Individual differences in structural architecture, functional organization, or neuromodulation may explain the lack of statistically reliable activity in this contrast in the re-

maining participants.⁵⁹ Moreover, we began the search for activity in each participant in a predefined area around the coordinates obtained in the group analysis. As a result, our approach may have failed to identify the appropriate (active) brain areas simply because of interindividual variations in their exact location. Second, in addition to a lack of overt command-following capabilities, patient 1 failed to exhibit other signs of consciousness, such as visual fixation or visual pursuit, and was unable to produce intelligible vocalizations. Although these deficits cannot be explained by our findings, an interesting parallel can be drawn between the voluntary control of hand and eye movements. Indeed, like voluntary hand movements, the neural circuits controlling saccades and visual pursuit include the basal ganglia, thalamus, and motor and premotor cortices.⁶⁰ In fact, the frontal eye field (the cortical area that ultimately produces the movement of the eye) lies adjacent to the motor representation of the arm and hand.^{61,62} Moreover, the ventrolateral thalamic nucleus plays a central role in the control of eye movements, exerted via its direct projections to the frontal and supplementary eye fields,⁶³ and injury to the frontal eye fields leads to dramatic eye movement impairment.⁶⁴ Therefore, a plausible hypothesis would be that damage to the ventrolateral thalamus and its projections may lead to disruption in the circuits controlling both limb and eye movements, which may explain the absence of visual fixation and pursuit seen in covertly aware patients. Similarly, the inferior frontal gyrus, precentral gyrus, and thalamus have been reliably reported⁶⁵ as key regions for intelligible word production. The specific study of visual and speech function was outside the scope of the present study, and we lack a reliable model of dysfunction in our patients that could be used to make predictions about the specific location of the structural damage. However, this relationship offers an interesting hypothesis for further studies. Finally, the source of the vegetative state was traumatic brain injury in both patients reported here. Although thalamic injury is a common neuropathologic finding both in patients with and without trauma, the degree of white matter damage differs between these groups.⁶⁶ Therefore, our findings should be confirmed in patients with nontraumatic sources of brain damage before they can be extrapolated to other patients.

Conclusions

To our knowledge, this study provides the first direct neural correlate for the absence of intentional movement in a covertly aware, but clinically vegetative, patient. These results not only may suggest a possible early diagnostic biomarker for this recently discovered group of covertly aware patients but also may pave the road for the development of therapies aimed at restoring their lost motor abilities (eg, deep brain stimulation of the ventrolateral thalamic nuclei).

ARTICLE INFORMATION

Accepted for Publication: August 4, 2015.

Published Online: October 19, 2015.

doi:10.1001/jamaneurol.2015.2614.

Author Contributions: Dr Fernández-Espejo had full access to all the data in the study and takes

responsibility for the integrity of the data and the accuracy of the data analysis.

Study concept and design: All authors.

Acquisition, analysis, or interpretation of data:

Fernández-Espejo, Rossit.

Drafting of the manuscript: Fernández-Espejo. **Critical revision of the manuscript for important intellectual content:** All authors.

Statistical analysis: Fernández-Espejo.

Obtained funding: Fernández-Espejo, Owen. **Administrative, technical, or material support:** Rossit.

Study supervision: Owen.

Conflict of Interest Disclosures: None reported.

Funding/Support: This research was supported by funding for a postdoctoral fellowship (Dr Fernández-Espejo) and operating grant 0000032597 (Dr Owen) from the Canadian Institutes of Health Research, grant 220020156.01 from the James S. McDonnell Foundation (Dr Owen), and chair 0000025914 from the Canada Excellence Research Chairs Program (Drs Owen and Fernández-Espejo).

Role of the Funder/Sponsor: The funding organizations had no role in the design and conduct of the study; collection, management, analysis, and interpretation of the data; preparation, review, or approval of the manuscript; and decision to submit the manuscript for publication.

Additional Contributions: Damian Cruse, PhD, Brain and Mind Institute, University of Western Ontario, provided feedback and comments that greatly improved the manuscript. There was no financial compensation.

REFERENCES

- Jennett B, Plum F. Persistent vegetative state after brain damage. A syndrome in search of a name. *Lancet*. 1972;1(7753):734-737.
- Multi-Society Task Force on PVS. Medical aspects of the persistent vegetative state (I). *N Engl J Med*. 1994;330(21):1499-1508.
- Fernández-Espejo D, Owen AM. Detecting awareness after severe brain injury. *Nat Rev Neurosci*. 2013;14(11):801-809.
- Laureys S, Schiff ND. Coma and consciousness: paradigms (re)framed by neuroimaging. *Neuroimage*. 2012;61(2):478-491.
- Jeannerod M. Mental imagery in the motor context. *Neuropsychologia*. 1995;33(11):1419-1432.
- Maxwell WL, Pennington K, MacKinnon MA, et al. Differential responses in three thalamic nuclei in moderately disabled, severely disabled and vegetative patients after blunt head injury. *Brain*. 2004;127(pt 11):2470-2478.
- Maxwell WL, MacKinnon MA, Smith DH, McIntosh TK, Graham DI. Thalamic nuclei after human blunt head injury. *J Neuropathol Exp Neurol*. 2006;65(5):478-488.
- Fernández-Espejo D, Bekinschtein T, Monti MM, et al. Diffusion weighted imaging distinguishes the vegetative state from the minimally conscious state. *Neuroimage*. 2011;54(1):103-112.
- Fernández-Espejo D, Junque C, Bernabeu M, Roig-Rovira T, Vendrell P, Mercader JM. Reductions of thalamic volume and regional shape changes in the vegetative and the minimally conscious states. *J Neurotrauma*. 2010;27(7):1187-1193.
- Fernández-Espejo D, Soddu A, Cruse D, et al. A role for the default mode network in the bases of disorders of consciousness. *Ann Neurol*. 2012;72(3):335-343.
- Schiff ND. Central thalamic contributions to arousal regulation and neurological disorders of consciousness. *Ann N Y Acad Sci*. 2008;1129(1):105-118.
- Parent A, Hazrati LN. Functional anatomy of the basal ganglia: I: the cortico-basal ganglia-thalamo-cortical loop. *Brain Res Brain Res Rev*. 1995;20(1):91-127.
- Bosch-Bouju C, Hyland BI, Parr-Brownlie LC. Motor thalamus integration of cortical, cerebellar and basal ganglia information: implications for normal and parkinsonian conditions. *Front Comput Neurosci*. 2013;7:163.
- Friston KJ, Harrison L, Penny W. Dynamic causal modelling. *Neuroimage*. 2003;19(4):1273-1302.
- Stephan KE, Penny WD, Daunizeau J, Moran RJ, Friston KJ. Bayesian model selection for group studies. *Neuroimage*. 2009;46(4):1004-1017.
- Cruse D, Chennu S, Fernández-Espejo D, Payne WL, Young GB, Owen AM. Detecting awareness in the vegetative state: electroencephalographic evidence for attempted movements to command. *PLoS One*. 2012;7(11):e49933. doi:10.1371/journal.pone.0049933.
- Naci L, Owen AM. Making every word count for nonresponsive patients. *JAMA Neurol*. 2013;70(10):1235-1241.
- Gibson RM, Fernández-Espejo D, Gonzalez-Lara LE, et al. Multiple tasks and neuroimaging modalities increase the likelihood of detecting covert awareness in patients with disorders of consciousness. *Front Hum Neurosci*. 2014;8:950.
- Fernández-Espejo D, Norton L, Owen AM. The clinical utility of fMRI for identifying covert awareness in the vegetative state: a comparison of sensitivity between 3T and 1.5T. *PLoS One*. 2014;9(4):e95082. doi:10.1371/journal.pone.0095082.
- Peterson A, Naci L, Weijer C, Cruse D. Assessing decision-making capacity in the behaviorally nonresponsive patient with residual covert awareness. *AJOB Neurosci*. 2013;4(4):3-14.
- Naci L, Cusack R, Anello M, Owen AM. A common neural code for similar conscious experiences in different individuals. *Proc Natl Acad Sci U S A*. 2014;111(39):14277-14282.
- McKeown MJ, Makeig S, Brown GG, et al. Analysis of fMRI data by blind separation into independent spatial components. *Hum Brain Mapp*. 1998;6(3):160-188.
- Maldjian JA, Laurienti PJ, Kraft RA, Burdette JH. An automated method for neuroanatomic and cytoarchitectonic atlas-based interrogation of fMRI data sets. *Neuroimage*. 2003;19(3):1233-1239.
- Stephan KE, Penny WD, Moran RJ, den Ouden HE, Daunizeau J, Friston KJ. Ten simple rules for dynamic causal modeling. *Neuroimage*. 2010;49(4):3099-3109.
- Kasess CH, Windischberger C, Cunnington R, Lanzenberger R, Pezawas L, Moser E. The suppressive influence of SMA on M1 in motor imagery revealed by fMRI and dynamic causal modeling. *Neuroimage*. 2008;40(2):828-837.
- Künzle H. An autoradiographic analysis of the efferent connections from premotor and adjacent prefrontal regions (areas 6 and 9) in *Macaca fascicularis*. *Brain Behav Evol*. 1978;15(3):185-234.
- Hunnicutt BJ, Long BR, Kusefoglou D, Gertz KJ, Zhong H, Mao T. A comprehensive thalamocortical projection map at the mesoscopic level. *Nat Neurosci*. 2014;17(9):1276-1285.
- Matelli M, Luppino G, Fogassi L, Rizzolatti G. Thalamic input to inferior area 6 and area 4 in the macaque monkey. *J Comp Neurol*. 1989;280(3):468-488.
- Oguri T, Sawamoto N, Tabu H, et al. Overlapping connections within the motor cortico-basal ganglia circuit: fMRI-tractography analysis. *Neuroimage*. 2013;78:353-362.
- Bracht T, Schnell S, Federspiel A, et al. Altered cortico-basal ganglia motor pathways reflect reduced volitional motor activity in schizophrenia. *Schizophr Res*. 2013;143(2-3):269-276.
- McGuire PK, Bates JF, Goldman-Rakic PS. Interhemispheric integration, I: symmetry and convergence of the corticocortical connections of the left and the right principal sulcus (PS) and the left and the right supplementary motor area (SMA) in the rhesus monkey. *Cereb Cortex*. 1991;1(5):390-407.
- Rouiller EM, Babalian A, Kazennikov O, Moret V, Yu XH, Wiesendanger M. Transcallosal connections of the distal forelimb representations of the primary and supplementary motor cortical areas in macaque monkeys. *Exp Brain Res*. 1994;102(2):227-243.
- Rowe JB, Hughes LE, Barker RA, Owen AM. Dynamic causal modelling of effective connectivity from fMRI: are results reproducible and sensitive to Parkinson's disease and its treatment? *Neuroimage*. 2010;52(3):1015-1026.
- Kruschke J. *Doing Bayesian Data Analysis: A Tutorial With R, JAGS, and Stan*. 2nd ed. San Diego, CA: Academic Press; 2014.
- Parker Jones O, Seghier ML, Kawabata Duncan KJ, Leff AP, Green DW, Price CJ. Auditory-motor interactions for the production of native and non-native speech. *J Neurosci*. 2013;33(6):2376-2387.
- Penny WD, Stephan KE, Daunizeau J, et al. Comparing families of dynamic causal models. *PLoS Comput Biol*. 2010;6(3):e1000709. doi:10.1371/journal.pcbi.1000709.
- Behrens TEJ, Berg HJ, Jbabdi S, Rushworth MFS, Woolrich MW. Probabilistic diffusion tractography with multiple fibre orientations: what can we gain? *Neuroimage*. 2007;34(1):144-155.
- Crawford JR, Garthwaite PH, Howell DC. On comparing a single case with a control sample: an alternative perspective. *Neuropsychologia*. 2009;47(13):2690-2695.
- Rouiller EM, Tanne J, Moret V, Boussaoud D. Origin of thalamic inputs to the primary, premotor, and supplementary motor cortical areas and to area 46 in macaque monkeys: a multiple retrograde tracing study. *J Comp Neurol*. 1999;409(1):131-152.
- Jones EG. The thalamic matrix and thalamocortical synchrony. *Trends Neurosci*. 2001;24(10):595-601.
- Park C-H, Chang WH, Ohn SH, et al. Longitudinal changes of resting-state functional connectivity during motor recovery after stroke. *Stroke*. 2011;42(5):1357-1362.
- Ward NS, Brown MM, Thompson AJ, Frackowiak RSJ. Neural correlates of motor recovery after stroke: a longitudinal fMRI study. *Brain*. 2003;126(pt 11):2476-2496.
- Jang SH, Kwon YH, Lee MY, Lee DY, Hong JH. Difference of neural connectivity for motor function

in chronic hemiparetic stroke patients with intracerebral hemorrhage. *Neurosci Lett*. 2012;531(2):80-85.

44. Bekinschtein TA, Manes FF, Villarreal M, Owen AM, Della-Maggiore V. Functional imaging reveals movement preparatory activity in the vegetative state. *Front Hum Neurosci*. 2011;5:5.
45. Hétu S, Grégoire M, Saimpont A, et al. The neural network of motor imagery: an ALE meta-analysis. *Neurosci Biobehav Rev*. 2013;37(5):930-949.
46. Friston KJ. Functional and effective connectivity: a review. *Brain Connect*. 2011;1(1):13-36.
47. Gregg M, Hall C, Butler A. The MIQ-RS: a suitable option for examining movement imagery ability. *Evid Based Complement Alternat Med*. 2010;7(2):249-257.
48. Gao Q, Tao Z, Zhang M, Chen H. Differential contribution of bilateral supplementary motor area to the effective connectivity networks induced by task conditions using dynamic causal modeling. *Brain Connect*. 2014;4(4):256-264.
49. Raffin E, Mattout J, Reilly KT, Giraux P. Disentangling motor execution from motor imagery with the phantom limb. *Brain*. 2012;135(pt 2):582-595.
50. Naccache L. Psychology: is she conscious? *Science*. 2006;313(5792):1395-1396.
51. Klein C. Consciousness, intention, and command-following in the vegetative state [published online April 14, 2015]. *Br J Philos Sci*. doi: 10.1093/bjps/axv012.
52. Shea N, Bayne T. The vegetative state and the science of consciousness. *Br J Philos Sci*. 2010;61(3):459-484.
53. Adams JH, Jennett B, McLellan DR, Murray LS, Graham DI. The neuropathology of the vegetative state after head injury. *J Clin Pathol*. 1999;52(11):804-806.
54. Kinney HC, Samuels MA. Neuropathology of the persistent vegetative state: a review. *J Neuropathol Exp Neurol*. 1994;53(6):548-558.
55. Jennett B, Adams JH, Murray LS, Graham DI. Neuropathology in vegetative and severely disabled patients after head injury. *Neurology*. 2001;56(4):486-490.
56. Lutkenhoff ES, McArthur DL, Hua X, Thompson PM, Vespa PM, Monti MM. Thalamic atrophy in antero-medial and dorsal nuclei correlates with six-month outcome after severe brain injury. *Neuroimage Clin*. 2013;3:396-404.
57. Fridman EA, Schiff ND. Neuromodulation of the conscious state following severe brain injuries. *Curr Opin Neurobiol*. 2014;29:172-177.
58. Schiff ND. Recovery of consciousness after brain injury: a mesocircuit hypothesis. *Trends Neurosci*. 2010;33(1):1-9.
59. Van Horn JD, Grafton ST, Miller MB. Individual variability in brain activity: a nuisance or an opportunity? *Brain Imaging Behav*. 2008;2(4):327-334.
60. Munoz DP, Everling S. Look away: the anti-saccade task and the voluntary control of eye movement. *Nat Rev Neurosci*. 2004;5(3):218-228.
61. Amiez C, Kostopoulos P, Champod A-S, Petrides M. Local morphology predicts functional organization of the dorsal premotor region in the human brain. *J Neurosci*. 2006;26(10):2724-2731.
62. Blanke O, Spinelli L, Thut G, et al. Location of the human frontal eye field as defined by electrical cortical stimulation: anatomical, functional and electrophysiological characteristics. *Neuroreport*. 2000;11(9):1907-1913.
63. Tanaka M. Involvement of the central thalamus in the control of smooth pursuit eye movements. *J Neurosci*. 2005;25(25):5866-5876.
64. Lynch JC. Frontal eye field lesions in monkeys disrupt visual pursuit. *Exp Brain Res*. 1987;68(2):437-441.
65. Indefrey P. The spatial and temporal signatures of word production components: a critical update. *Front Psychol*. 2011;2:255.
66. Adams JH, Graham DI, Jennett B. The neuropathology of the vegetative state after an acute brain insult. *Brain*. 2000;123(pt 7):1327-1338.