

Rheumatology 2001;40:229–230

### Histopathological assessment and pathological significance of matrix degeneration in supraspinatus tendons

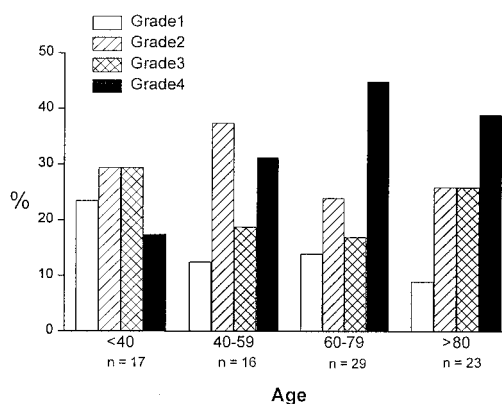
SIR, Although histological abnormalities of the supraspinatus tendon are a frequent finding in cadaver studies, the relationship between age, specific matrix changes and the development of clinical tendinopathy (tendinitis) has not been rigorously investigated. We conducted a histopathological analysis of 85 supraspinatus tendons from cadavers (aged 11–96 yr) and 33 specimens from patients with degenerate rotator cuff tears (aged 38–81 yr). Representative sections of each specimen were examined by two blinded observers independently and graded according to a four-point scale based on the organization of the tendon fibre bundles. Normal tendons were designated grade 1 and comprised bundles of fibres with a wavy outline, with individual fibres easily discernible within the bundles. Tenocyte nuclei were elongated with an unremarkable chromatin pattern and lay with their long axis parallel to the bundles of collagen. Mild degeneration, designated grade 2, showed collagen fibres still relatively well aligned, although the waviness was patchy and individual fibres could not be readily identified in all fields. The cell nuclei were shorter but still oval, with darker-staining chromatin. The relationship to collagen fibres was maintained but often the nuclei were arranged in short chains to give an Indian-file appearance. Moderate degeneration, designated grade 3, showed increasing hyalinization of the collagen to produce areas of smudgy, homogeneous eosinophilic staining in the haematoxylin/eosin preparation. Cell nuclei were often increased in number and were round to oval in outline with a darkly staining chromatin pattern. There was some loss of orientation of the collagen bundles and loss of orientation of the nuclei in relation to the collagen bundles. Severe degeneration, designated grade 4, showed diffuse hyalinization of the collagen throughout the tendon, with a homogeneous appearance. There was complete loss of orientation of collagen bundles within the tendon, as assessed by polarized light microscopy. The number of nuclei was reduced and those present were small, dark and rounded.

Using this grading system, we found that the severity of supraspinatus matrix degeneration increased with age, although the relationship was not a simple one (Fig. 1A). The proportion of tendons affected by severe degeneration (grade 4) was 18% (3/17) in tendons from persons aged under 40 yr, increasing to a peak of 45% (13/29) of specimens from persons aged 60–79 yr.

Moderate or severe degeneration (grades 3 and 4) affected 47% of tendons from persons under the age of 40 yr, increasing to 65% of the sample over the age of 80 yr. Normal tendons (grade 1) comprised only 23% (4/17) of specimens from persons aged under 40 yr. Degeneration was not an inevitable consequence of ageing, however, since 9% of specimens from persons over the age of 80 yr were designated normal. In supraspinatus tendinopathy, the frequency of degenerative change was greater than in age-matched cadaver tendons, the majority of specimens showing either moderate or severe matrix degeneration in all of the age groups (Fig. 1B).

Although there have been a number of histopathological studies of supraspinatus tendons over the years, the majority have been cadaver studies and largely

#### A) Normal (cadaver) supraspinatus tendons



#### B) Supraspinatus tendinitis

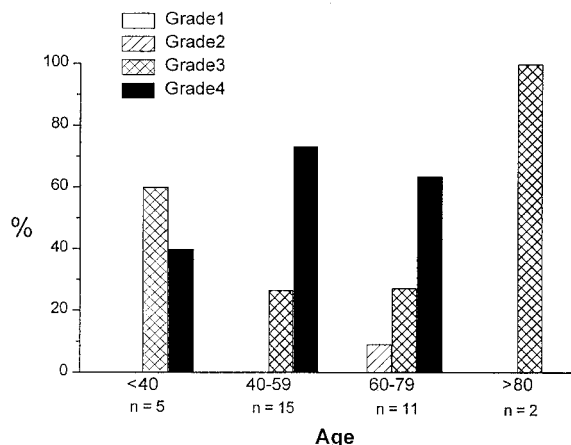


FIG. 1. Histopathological grading of supraspinatus tendons. Specimens were prepared for histology and sections were examined blind by two independent observers and graded according to a four point scale: grade 1, normal tendon; grade 2, mild degeneration; grade 3, moderate degeneration; grade 4, severe degeneration. (A) Data for 85 macroscopically normal cadaver supraspinatus tendons (11–96 yr) (B) Data for 33 specimens from patients with chronic tendinopathy (rotator cuff tear).

descriptive [1–5]. Our study demonstrates that degenerative changes are common in supraspinatus tendons, that their severity increases with age, and that more severe degeneration is associated with the development of tendinopathy. This is in contrast to studies that have reported the absence of significant degenerative features in supraspinatus tendons from persons under 50 yr of age [6]. Although we recognize that studies of this nature cannot distinguish between cause and effect, normal tendon is immensely strong under tension and some form of matrix degeneration is considered to precede rupture under normal loading conditions. Precisely what constitutes pathological degeneration of the tendon matrix, however, and how these changes are mediated remain to be determined. Tendon degeneration is commonly ascribed to repeated minor strains that exceed the elastic capability of the tissue [7]. The repair potential of the resident cell population is thought to be limited and tissue damage accumulates, leading to tendon rupture. We believe that this hypothesis of matrix damage/failure to repair may underestimate the role and activity of the resident tenocytes in the degenerative process. In a recent analysis of tendon matrix composition, we showed changes in collagen composition and collagen cross-links consistent with increased remodelling of the normal supraspinatus tendon compared with a normal flexor tendon (the short head of biceps brachii), and a higher rate of collagen turnover in degenerate (ruptured) supraspinatus tendons [8]. The resident cell population (tenocytes) is responsible for mediating this matrix turnover, and we have detected the expression and activity of a variety of matrix metalloproteinase (MMP) enzymes, including MMP-1, MMP-2, MMP-3, MMP-9 and MMP-13 (G. P. Riley, V. Curry and R. A. Bank, unpublished observations). We propose the hypothesis that high rates of collagen turnover in 'normal' (non-ruptured) supraspinatus may be part of an adaptive response to the high mechanical demands (tension, compression and shear forces) placed on the supraspinatus tendon in the rotator cuff complex [9–11]. In tendinopathy there is an imbalance in the synthesis and degradation of matrix that leads to structural deterioration and degeneration of the tendon. The development of a histopathological grading system will facilitate research in this area, allowing changes in cell synthetic activity and enzyme expression to be correlated with degenerative changes in the tendon matrix.

G. P. RILEY, M. J. GODDARD<sup>1</sup>, B. L. HAZLEMAN

*Rheumatology Research Unit, Addenbrooke's Hospital NHS Trust, Box 194, Hills Road, Cambridge, CB2 2QQ, and <sup>1</sup>Department of Pathology, Papworth Hospital, Cambridgeshire, UK*  
Accepted 4 August 2000

Correspondence to: G. P. Riley.

1. Keyes EL. Anatomical observations on senile changes in the shoulder. *J Bone Joint Surg* 1935;17:953–60.
2. Wilson CL, Duff GL. Pathological study of degeneration and rupture of the supraspinatus tendon. *Archiv Surg* 1943;47:121–35.
3. Cotton RE, Rideout DF. Tears on the humeral rotator cuff. *J Bone Joint Surg* 1964;46B:314–28.
4. Yamanaka K, Fukuda H. Ageing process of the supraspinatus tendon with reference to rotator cuff tears. In: Watson MS, ed. *Surgical disorders of the shoulder*. Edinburgh. Churchill, 1991:247–58.
5. Chard MD, Cawston TE, Riley GP, Gresham A, Hazleman BL. Rotator cuff degeneration and lateral epicondylitis: a comparative histological study. *Ann Rheum Dis* 1994;53:30–4.
6. Clark JM, Harryman DT II. Tendons, ligaments, and capsule of the rotator cuff. Gross and microscopic anatomy. *J Bone Joint Surg* 1992;74A:713–25.
7. Józsa L, Kannus P. Overuse injuries of tendons. In Józsa L, Kannus P, eds. *Human tendons: anatomy, physiology and pathology*. Champaign, IL: Human Kinetics, 1997:164–253.
8. Bank RA, TeKoppele JM, Oostingh G, Hazleman BL, Riley GP. Lysylhydroxylation and non-reducible cross-linking of human supraspinatus tendon collagen: changes with age and in chronic rotator cuff tendinitis. *Ann Rheum Dis* 1999;58:35–41.
9. Riley GP, Harrall RL, Constant CR, Chard MD, Cawston TE, Hazleman BL. Glycosaminoglycans of human rotator cuff tendons: Changes with age and in chronic rotator cuff tendinitis. *Ann Rheum Dis* 1994;53:367–76.
10. Cawston TE, Riley GP, Hazleman BL. Tendon lesions and soft tissue rheumatism—Great outback or great opportunity. *Ann Rheum Dis* 1996;55:1–3.
11. Berenson MC, Blevins FT, Plaas AH, Vogel KG. Proteoglycans of human rotator cuff tendons. *J Orthop Res* 1996;14:518–25.