

Expression of transforming growth factor-beta isoforms and their receptors in chronic tendinosis

S. A. FENWICK¹, V. CURRY¹, R. L. HARRALL¹, B. L. HAZLEMAN¹, R. HACKNEY²
AND G. P. RILEY

¹ Rheumatology Research Unit, Addenbrookes Hospital, Cambridge, and ² Leeds General Infirmary, Leeds, UK

(Accepted 27 February 2001)

ABSTRACT

Chronic tendon lesions are degenerative conditions and may represent a failure to repair or remodel the extracellular matrix after repeated micro-injury. Since TGF- β is strongly associated with tissue repair, we investigated the expression of TGF- β isoforms (β 1, β 2 and β 3) and their 2 signalling receptors (TGF- β RI and TGF- β RII) in normal and pathological Achilles tendons. In all tissues, all 3 TGF- β isoforms and the 2 receptors were present at sites of blood vessels. Cells in the matrix showed no staining for TGF- β 1 or β 3, while TGF- β 2 was associated with cells throughout the normal cadaver tendon. Tissue from tendons with pathological lesions showed an increase in cell numbers and percentage TGF- β 2 expression. TGF- β RII showed a wide distribution in cells throughout the tissue sections. As with TGF- β 2, there was an increase in the number of cells expressing TGF- β RII in pathological tissue. TGF- β RI was restricted to blood vessels and was absent from the fibrillar matrix. We conclude that despite the presence and upregulation of TGF- β 2, TGF- β signalling is not propagated due to the lack of TGF- β RI. This might explain why chronic tendon lesions fail to resolve and suggests that the addition of exogenous TGF- β will have little effect on chronic tendinopathy.

Key words: Transforming growth factor beta isoforms; transforming growth factor-beta receptors; tendinopathy.

INTRODUCTION

Tendon lesions (tendinopathies) are often chronic, tending to occur in middle age, frequently in the absence of trauma or remembered injury. Degeneration is commonly associated with most tendinopathies, since there is little evidence of inflammation (Aström & Rausing, 1995; Jarvinen et al. 1997; Kannus, 1997). They are often associated with 'overuse', and are possibly the consequence of repeated microtrauma and a failure to repair (Kannus, 1997). Repair of matrix injury requires the coordinated control of successive phases of cell activity, including cell recruitment, cell proliferation, matrix synthesis and matrix remodelling. Consequently a failure of any one of these activities may give rise to a tendinopathy.

Transforming growth factor beta (TGF- β) is likely to be an important factor in tendon pathology since it plays a major role in tissue repair (Clark & Coker,

1998). One of its most important roles is the promotion of new matrix synthesis (Ignotz & Massague, 1986; Roberts et al. 1986; Clark et al. 1997; Wang et al. 1999). There are 3 mammalian isoforms of TGF- β (β 1, β 2 and β 3) which are differently expressed in a variety of connective tissues including cartilage (Fukumura et al. 1998; Matsunaga et al. 1999), bone (Horner et al. 1998), and muscle (McLennan & Koishi, 1997). Differential activities of the 3 isoforms in tissue healing have also been shown (Shah et al. 1995; O'Kane & Ferguson, 1997; Cordeiro et al. 1999), although their precise role is not fully understood. First secreted in a 100 kDa latent form, TGF- β is activated by proteolytic cleavage, releasing a 25 kDa active dimer (Clark & Coker, 1998). Activity is mediated by 2 signalling receptors, TGF- β receptor I (TGF- β RI) and TGF- β RII, which dimerise and transduce their signal via their serine/threonine kinase activity (Wrana et al. 1994).

There have been no studies of the expression and

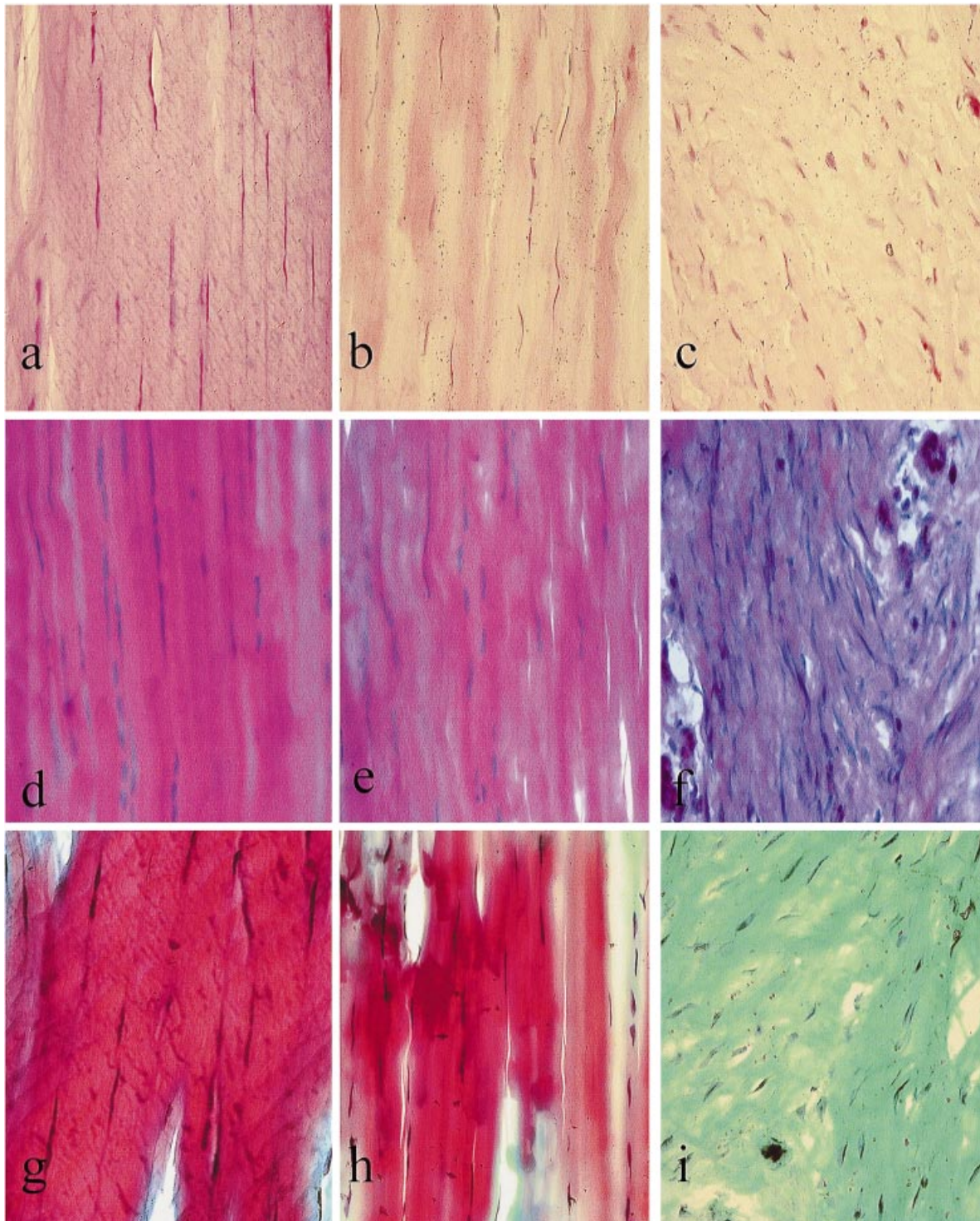


Fig. 1. Haematoxylin and eosin staining (*a, b, c*) showing morphology of cells and tissue structure. Alcian blue staining (*d, e, f*) showing the presence (blue) or absence (pink) of glycosaminoglycans. Masson's trichrome staining (*g, h, i*) showing organised collagen matrix (red) and disorganised collagen matrix (blue/green). Normal matrix organisation, normal cellularity and absence of glycosaminoglycan (GAG) infiltration in a 76-y-old male cadaver (*a, d, g*). The macroscopically normal site of a 38-y-old male patient with Achilles tendinopathy also showed normal organisation, normal cellularity and no GAG infiltration (*b, e, h*). The specimen from the site of the lesion in the same patient with tendinopathy showed increased cellularity, cell rounding, infiltration of GAG and absence of matrix organisation (*c, f, i*). $\times 400$.

role of TGF- β in human tendon pathology. Studies of acute tendon lesions in animals, while informative, have little relevance to the chronic degenerative lesions found in man (Chang et al. 1997). There are alterations

in TGF- β expression in a number of connective tissue pathologies such as Dupuytren's contracture and keloid scar (Park et al. 1995; Badalamente et al. 1996; Ichiki et al. 1997), implicating TGF- β in the path-

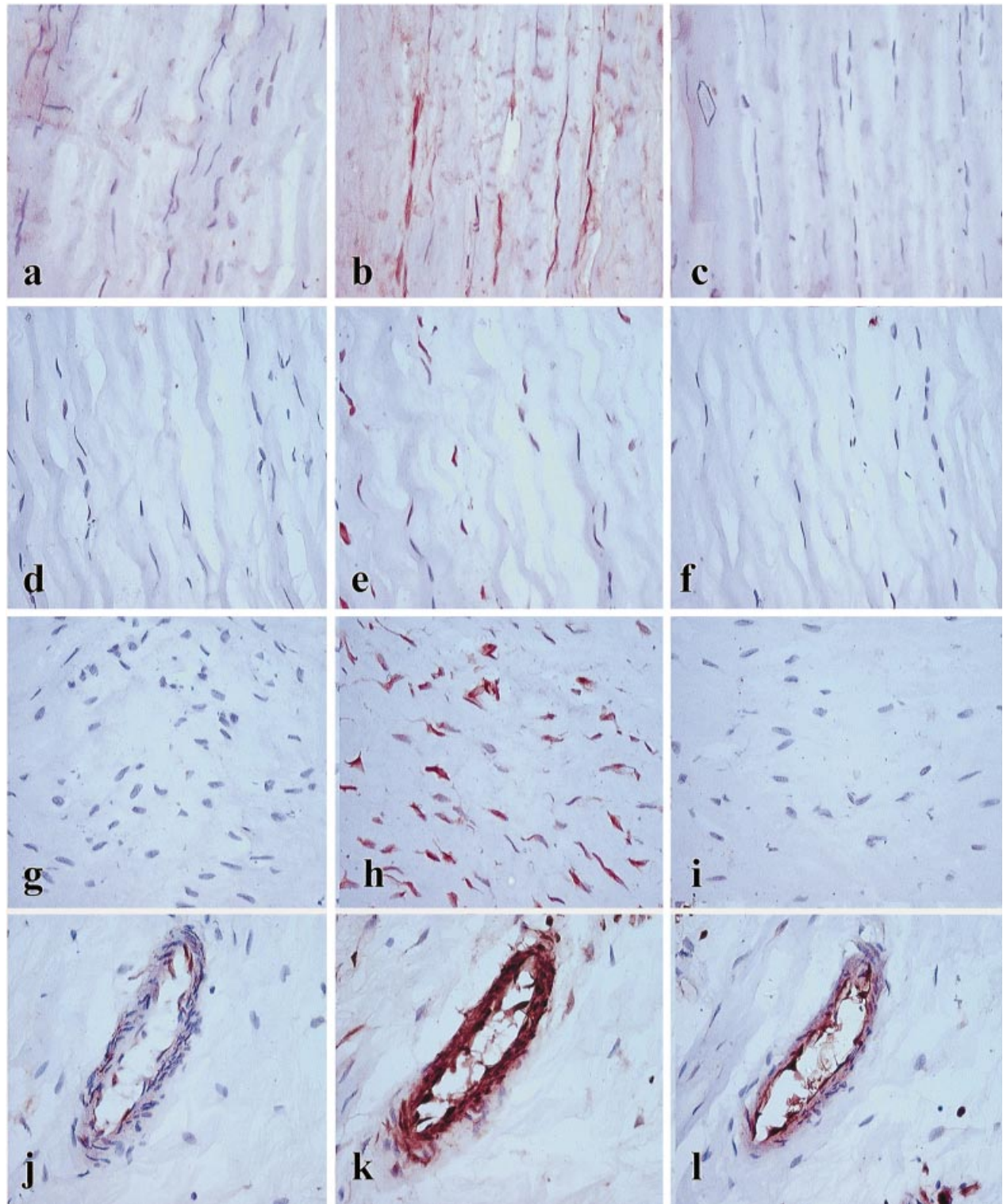


Fig. 2. Immunolocalisation of TGF- β isoforms, showing a lack of tenocyte staining for TGF- β 1 (*a, d, g*) and TGF- β 3 (*c, f, i*). TGF- β 2 was localised to tenocytes throughout the tissues seen as dark brown staining of the cells (*b, e, h*). Blood vessels stained positively for TGF- β 1 (*j*), TGF- β 2 (*k*) and TGF- β 3 (*l*). *a, b* and *c* are from a 76-y-old male cadaver, *d, e* and *f* are from the macroscopically normal site of a 39-y-old male, *g, h* and *i* are from the core lesion site of a 36-y-old male. Haematoxylin counterstain, $\times 400$.

ology. It has also been suggested that alterations in responsiveness to TGF- β are the driving force behind such pathologies (Bettinger et al. 1996; Zhou et al. 1997). TGF- β has been shown to have profound

effects on tissue repair (O'Kane & Ferguson, 1997) and to accelerate and enhance wound healing as an exogenously applied agent (Ksander et al. 1990; Beck et al. 1991; Quaglini et al. 1991; Meyer, 1993;

Robinson, 1993). However, before the use of TGF- β therapy in tendon treatment, it is necessary to determine which, if any, TGF- β isoforms and their signalling receptors are present in chronic tendinosis. This will subsequently allow further research into the possible therapeutic value of TGF- β in tendinopathy. Here we present the results of an immunochemical study of all 3 TGF- β isoforms and their signalling receptors in specimens taken from patients with chronic tendinosis. Comparisons were then made with samples of macroscopically and histologically normal tendon tissue from the same tendon and with unaffected Achilles tendons from cadavers.

MATERIALS AND METHODS

Tissue

Achilles tendon tissue was obtained from patients undergoing surgery for chronic Achilles tendinopathy ($n = 7$, aged 29–49 y, mean 38.4 ± 7.8 y). Macroscopically abnormal tissue was removed from the core of the lesion, which was localised with the aid of magnetic resonance imaging. All lesions were located in the tendon midsubstance approximately 4–8 cm from the tendon insertion. As part of the operative procedure, macroscopically normal tissue was also removed from each tendon from a site distant to the core lesion. Normal Achilles tendon tissue was obtained from cadavers, with no known history of tendinopathy, no more than 48 h after death ($n = 4$, aged 56–93 y, mean 75.5 ± 15.2 y).

Tissue preparation

Tissue was immediately cut into small cubes and either snap frozen in hexane before storage at -70°C , or lightly fixed in 4% paraformaldehyde in phosphate buffered saline on ice for 2–4 h followed by saturation in cold 30% sucrose at 4°C . Tissue was embedded in Optimal Cutting Temperature compound (OCT, Agar Scientific, Essex, UK) and cryosections cut at 8–10 μm . Sections were mounted on 3-aminopropyl-triethoxysilane (TESPA, Sigma) coated slides and allowed to air dry. Unfixed tissue sections were subsequently fixed briefly in acetone for 30 s before staining.

Histology and histochemistry

Sections were stained with haematoxylin and eosin to display general morphology and cellularity and with Alcian blue/periodic acid Schiff to demonstrate matrix proteoglycans and glycosaminoglycans (GAG). Masson's trichrome stain as described by

Flint et al. (1975) was used to determine whether the collagenous matrix was well organised or whether it had lost the organised fibrillar structure associated with normal tendon.

Immunohistochemistry

Immunochemical staining was performed for all 3 human TGF- β isoforms and for the 2 TGF- β receptors. Antibodies to the 3 mammalian TGF- β isoforms and the 2 signalling receptors were obtained from Santa Cruz Biotechnology (California, USA). All antibodies were affinity purified rabbit polyclonals to the human epitopes. The 3 TGF- β antibodies were isoform specific as confirmed by western blot analysis and immunohistochemical staining (Frank et al. 1996), while the receptor antibodies were confirmed to be specific by immunoprecipitation (Brand & Schnieder, 1995). The anti-TGF- β antibodies do not differentiate between active and latent TGF- β . Antibodies were titrated against sections over a range of dilutions, 4 $\mu\text{g}/\text{ml}$, 2 $\mu\text{g}/\text{ml}$, 1 $\mu\text{g}/\text{ml}$ and 0.4 $\mu\text{g}/\text{ml}$. Blood vessels, which had previously been shown to express all 3 TGF- β isoforms and the 2 receptors (Falanga et al. 1992; Gold et al. 1997), were used as a positive internal control. The final antibody titre used for each antibody was 1 $\mu\text{g}/\text{ml}$, which corresponds to work previously carried out using these same antibodies (Gold et al. 1997). Negative controls were performed using a rabbit IgG fraction (Dako, Ely, UK) at the same concentration. Some sections were predigested with 0.1% bovine testicular hyaluronidase (Calbiochem, Nottingham, UK) to unmask possible hidden epitopes. Sections were incubated with primary antibodies overnight at room temperature before visualisation using reagents and protocols supplied with the Vectastain peroxidase kit (Vector Laboratories, Peterborough, UK). Sections were counterstained with Harris's haematoxylin. Positive cells appear dark brown, while negative cells remain purple/blue. To determine the number of positive cells in the tendon matrix (excluding blood vessels), 4 random fields of each section were counted for positive and negative cells on a $\times 40$ objective and the mean calculated. Significance values between cadavers, macroscopically 'normal' sites and core lesion tissues were calculated using Student's *t* test on the raw data values.

RESULTS

Histology and histochemistry

The histological appearance and staining properties for the tendons are summarised in Table 1 and

Table 1. Comparison of tissue histology/histochemistry and total cell number of tissues

Tissue	Age (y)	Duration of symptoms (y)	Histology	Cell no. (average/field)
Lesion site				
A	36	1	All tissues showed a disorganised matrix that was hypercellular, hypervascular and had an increased glycosaminoglycan content	65.3 ± 16.6
B	36	not known		83.8 ± 18.1
C	32	7		67.5 ± 12.8
D	38	not known		48.3 ± 11.9
E	29	6		38.8 ± 5.7
F	49	1.5		61.8 ± 25.2
G	49	not known		50.3 ± 10.7
				Mean 59.4 ± 16.6**
'Normal site'				
A	36	1	All tissue samples showed a generally organised matrix, normal cellularity with occasional hypercellular regions, normal vascularity with focal hypervascularity in one sample, no glycosaminoglycan infiltration	32.8 ± 9.6
B	36	not known		43.8 ± 7.1
C	32	7		21.8 ± 5.1
D	38	not known		15 ± 5.7
E	29	6		21.5 ± 10.1
F	49	1.5		11.7 ± 3.1
G	49	not known		27.3 ± 4.8
				Mean 26.1 ± 11.9
Cadaver				
1	77	–	All tissue samples had an organised matrix, normal cellularity and vascularity, no glycosaminoglycan infiltration	17 ± 2.8
2	93	–		35 ± 10.6
3	56	–		30.8 ± 8.3
4	76	–		34 ± 13.1
				Mean 30.9 ± 11.2

** Significant difference compared with macroscopically normal and cadaver tissue.

illustrated in Figure 1. The cadaver tendons showed the characteristic histology of normal tendon with dense, parallel packed fibres and sparse cellularity. The cell nuclei were spindle shaped and cells were located between collagen fibres in rows (Fig. 1a). Blood vessels were infrequently seen and were restricted to the endotenon at the edges of fibre bundles. There was no infiltration with GAGs, seen by Alcian blue staining, as has been shown previously (Movin et al. 1997) (Fig. 1d). Masson's trichrome staining showed mainly organised collagen fibril structures, with some disorganised collagen staining at the cut ends of the tissue (Fig. 1g). Tissue from the macroscopically normal site generally showed tissue architecture similar to that of the cadaver tissue. There was a paucity of blood vessels (Fig 1b). Alcian blue staining was again negative (Fig. 1e) and Masson's trichrome staining showed mainly organised collagen (red) though small areas of disorganised collagen (blue/green) (Fig. 1h). The specimens from the lesion showed little of the organised matrix structure seen in normal tendon. There was a significant increase in cellularity ($P \leq 0.05$) compared with both the macroscopically normal tissue and the cadaver tissue (Table 1) and an increase in blood vessels as has been previously reported in chronic

tendinosis (Aström & Rausing, 1995; Khan et al. 1999). There was no indication of inflammatory cells although cells were more rounded as opposed to the normal spindle-like morphology (Fig. 1c). Alcian blue staining showed areas of GAG infiltration in the majority of specimens as previously described in Achilles tendinopathy (Movin et al. 1997) (Fig. 1f). Masson's trichrome stain showed no indication of organised collagen fibrils (Fig. 1i).

Immunolocalisation

Antibodies to TGF- β 2 and TGF- β RII stained a proportion of cells throughout the matrix (see Figs. 2, 3). Cell counts showed that in the cadaver sections, 25.8% of the cells on average were positive for TGF- β 2. In the distant site tissue the average was 46.7% and in the core lesion site, 51.1%, both of which were a significant increase in cell proportions over the cadaver tissue sections ($P \leq 0.001$) (Table 2). No significant difference existed between the macroscopically normal site and the core lesion site in the pathological tendons. TGF- β RII stained positively in 26.4% of the cadaver tissue cells, 45.1% of the macroscopically normal tissue cells and 39.2% of lesion tissue cells. There was no significant difference

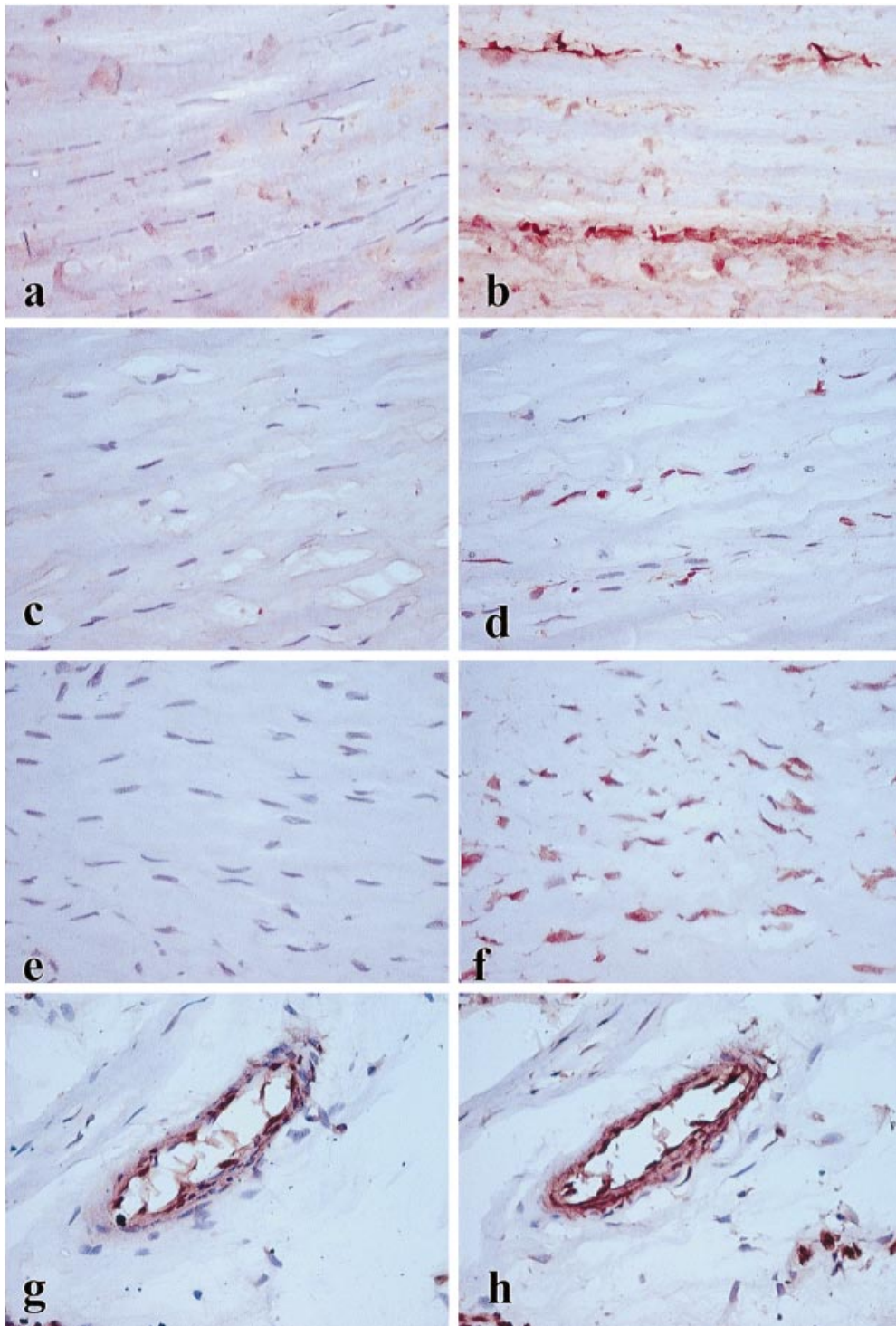


Fig. 3. Immunolocalisation of TGF- β receptors showing a lack of tenocyte staining for TGF- β RI (*a, c, e*). TGF- β RII was localised in cells throughout the tissue sections seen as dark brown staining of cells (*b, d, f*). Blood vessels stained positively for both TGF- β RI (*g*) and TGF- β RII (*h*), *a* and *b* are from a 56-y-old male cadaver, *c* and *d* are from the macroscopically normal site of a 38-y-old male, *e* and *f* are from the core lesion site of the same 38-y-old male. Haematoxylin counterstain $\times 400$.

between these values when the raw data were compared ($P \geq 0.05$).

Since there were differences in cellularity, nearly 3 times as many cells stained positively for TGF- β 2 in the core lesion tissue compared both with the macroscopically normal site and the cadaver tissue

($P \leq 0.05$). The number of cells expressing TGF- β RII was similar to that expressing TGF- β 2 in each of the specimen groups, with a greater number of cells expressing the receptor in the lesion site tissue compared with the other sites ($P \leq 0.05$) (Table 2). There was an absence of staining for TGF- β 1, TGF-

Table 2. Mean cell counts and percentage of cells expressing TGF- β 2 and TGF- β II

	TGF- β 2 Positive cells/field	% TGF- β 2 positive cells/field	TGF- β RII positive cells/field	% TGF- β RII positive cells/field
Lesion site	29.7 \pm 14.4**	46.7 \pm 26.5*	31.6 \pm 23.8**	39.2 \pm 28.1
'Normal Site'	12.1 \pm 8.2	51.1 \pm 23.5*	11.1 \pm 9.2	45.1 \pm 29.2
Cadaver	12.1 \pm 7.1	25.1 \pm 9.3	12 \pm 11.1	28.1 \pm 11.6

*, significant difference compared with cadaver tissue; **, significant difference compared with macroscopically normal and cadaver tissue.

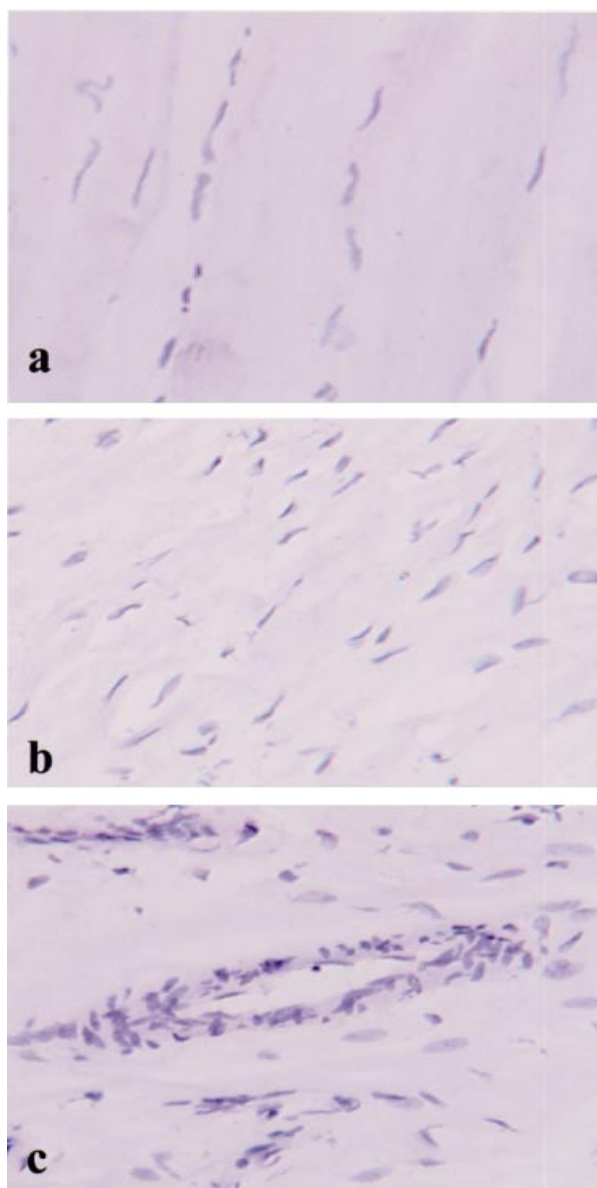


Fig. 4. Negative controls using a rabbit IgG fraction and counterstained with haematoxylin. *a* is from a 77-y-old cadaver section, *b* is from the core lesion of a 49-y-old male, *c* shows a blood vessel from the same patient. There was no peroxidase (brown) staining in any of the negative controls. $\times 400$.

β 3 (Fig. 2) and TGF- β RI (Fig. 3) in cells throughout the tissue matrix, although all 5 antibodies stained positive in blood vessels (Figs. 2, 3). Negative controls

showed no background or nonspecific staining (Fig. 4).

DISCUSSION

We have shown here that of the 3 TGF- β isoforms, only TGF- β 2 was expressed by tenocytes in the fibrillar matrix. TGF- β 1 and TGF- β 3 were restricted to blood vessels, co-expressed with TGF- β 2, as described in previous studies (Falanga et al. 1992; Gold et al. 1997). We have also shown that of the 2 TGF- β receptors, only TGF- β RII was present in tenocytes although both were present in blood vessels.

Although we did not apply quantitative techniques to this analysis, the percentage of cells expressing TGF- β 2 was significantly greater in patient tendons compared with normal cadaver tendons. We also found no difference in the percentage of positive cells between macroscopically normal sites in patient tendons, and specimens from the site of the lesion, although the latter were more cellular. Significant differences were not seen in the percentage of positive cell stained for TGF- β RII. Since the cadaver tendons were significantly older than the patient tendons, this difference in TGF- β 2 may reflect an ageing process rather than an effect of the pathology. As Achilles tendon injuries are common, it is also possible that despite the absence of any known history of tendinopathy in the cadaver specimens, there may have been previous pathological changes associated with some of these samples, although at the histochemical level there was no indication of obvious pathology.

TGF- β 1 has been shown to be upregulated in response to tissue damage in a number of connective tissue pathologies including keloid scarring (Lee et al. 1999), hypertrophic scarring (Zhou et al. 1997) and Dupuytren's contracture (Badalamente et al. 1996). Our study has shown that TGF- β 1 is absent in chronic Achilles tendinopathy, or at least is not present at levels detectable by immunoperoxidase staining. TGF- β 2 however was clearly detectable and prominently localized to cells throughout the tissues. TGF- β 2, along with TGF- β 1, is an essential factor in the

wound healing process and is associated with tissue healing and scarring (Shah et al. 1995), and is often prevalent in the earlier stages of wound healing along with TGF- β 3 (Levine et al. 1993). TGF- β 2 has also been linked to the induction of chondrogenesis and osteogenesis (Joyce et al. 1990) and may have a role in the chondrogenic change found in degenerate human tendons (Chard et al. 1994; Riley et al. 1996). However, we have found no evidence of markers of a chondrocytic phenotype, such as type II collagen, at the sites of chronic Achilles tendinosis (D. Ireland et al. unpublished). TGF- β 1 mRNA and protein have been shown to be upregulated following acute tendon laceration and repair. Both mRNA and protein were localised to intrinsic tenocytes and invading fibroblasts from the tendon sheath (Chang et al. 1997). However, this type of injury bears little resemblance to the chronic disorders that we have dealt with here, and therefore it is important to delineate the presence or absence of TGF- β (and indeed other factors) in these pathologies.

The factors that regulate TGF- β expression/activity are not well understood. One study has shown that both IL-1 and TNF- α are able to increase the synthesis of TGF- β in endothelial cells (Phan et al. 1992). Another study by Lemaire et al. (1996) showed that both granulocyte macrophage-colony stimulating factor and macrophage-colony stimulating factor upregulated TGF- β 1 mRNA in rat alveolar macrophages. A study on human articular chondrocytes has shown that both IL-1 and IL-6 can selectively induce TGF- β isoforms (Villiger et al. 1993). A number of other factors have also been shown to regulate TGF- β synthesis or secretion, including glucocorticoids (Karim et al. 1997; Beer et al. 2000), hypoxia (Falanga et al. 1991; Santilli et al. 1991; Klempt et al. 1992), ethanol (Szabo et al. 1996) and hyperthermia (Flanders et al. 1993). There is also evidence for differential regulation of the TGF- β isoforms (Falanga et al. 1991; Flanders et al. 1993; Villiger et al. 1993), suggesting that mechanisms of stress, tissue insult or cytokine exposure could induce a different spectrum of TGF- β isoform expression.

The 3 isoforms of TGF- β have been shown to have important, although differential, roles in wound healing (Shah et al. 1995; O'Kane & Ferguson, 1997) but their exact functions have still not been fully elucidated. The lack of resolution in chronic tendinosis suggests that there may be either a lack of TGF- β activity, or a failure to respond to TGF- β . TGF- β 2 is certainly present, although whether in its active form requires further investigation. Of possibly greater significance is the evident lack of the type I TGF- β

receptor, at least at the level of antibody detection, suggesting an absence or low level of expression of the receptor. TGF- β requires both type I and type II receptors to propagate its signal (Laiho et al. 1990; Wrana et al. 1994), therefore the possible lack of (or low levels of) the type I receptor suggests that signal might not be induced even in the presence of active TGF- β . The presence of receptors throughout wound repair has been shown to occur at a later stage than the presence of TGF- β ligand. Consequently it was suggested that TGF- β ligand may upregulate the TGF- β receptors for function or may reflect a lag time due to latent TGF- β processing (Gold et al. 1997). However, we are dealing here with a chronic condition, with symptoms of 12 mo up to 7 y. Granulation tissue in wounded skin has been shown to contain high levels of receptor (Schmid et al. 1998), although in undamaged skin, only small numbers of fibroblasts have detectable levels of receptors. Under normal conditions then, fibroblasts may not express one or both of the receptors, and we have shown that normal tendon also has an absence (or at least an undetectable level) of the type I receptor. The factors regulating TGF- β receptor expression in tendon are unknown, although a number of studies have been performed in other models to examine the factors that regulate receptor expression (Wu et al. 1997; Chang et al. 1998; Yoshizawa et al. 1998). Possibly of most relevance is the finding that mechanical strain increases the expression of TGF- β receptors in rat mesangial cells (Riser et al. 1999). The loss of strain across the pathological lesion in tendinosis could be a factor influencing the lack of TGF- β RI expression at these sites.

The cause of chronic tendon lesions is thought to be repeated microtrauma (Kannus, 1997). It has been speculated that microtrauma overwhelms the ability of tendon to repair (Jarvinen et al. 1997). A similar process has been shown to occur in chondrocytes during osteoarthritis, where a stage of the disease is reached where the chondrocytes fail to repair the matrix damage (Mankin et al. 1971). Tissue repair is a complex and tightly regulated process that requires sequential overlapping phases (Robinson, 1993; Mutsaers & Laurent, 1995). We postulate that the healing phases in tendinosis have not occurred in the correct manner. Inflammation is the first important step in tissue healing; without this initial stage, the tissue repair process may not proceed normally. In all lesions we have examined, there has been no evidence of inflammatory cells. In these chronic tendon problems, it may be that the repair process is not being triggered correctly or not being allowed

to proceed correctly due to the lack of inflammatory mediators, and it is this that accounts for the lack of resolution.

In summary we have shown that there is a differential expression of the 3 TGF- β isoforms and their receptors in both normal and pathological tendon. The number of cells expressing TGF- β 2 in chronic tendon pathology is increased which suggests that TGF- β 2 may have a role to play in mediating cell activity during this disease process. However, the lack of the type I receptor implies that TGF- β signalling does not occur. This study has implications for the treatment of tendinopathy with TGF- β , as without the presence of both receptors, exogenous TGF- β is unlikely to have an effect. We suggest that greater investigation into the factors that regulate TGF- β receptor expression is required to determine if this is a potential target for chronic tendinosis therapy.

ACKNOWLEDGEMENTS

We would like to acknowledge the Arthritis Research Campaign (ARC) and the Cambridge Arthritis Research Endeavour (CARE) for their funding of this work.

REFERENCES

- ASTRÖM M, RAUSING A (1995) Chronic Achilles tendinopathy. A survey of surgical and histopathologic findings. *Clinical Orthopaedics* **316**, 151–164.
- BADALAMENTE MA, SAMPSON SP, HURST LC, DOWD A, MIYASAKA K (1996) The role of transforming growth factor beta in Dupuytren's disease. *Journal of Hand Surgery-American Volume* **21A**, 210–215.
- BECK LS, DEGUZMAN L, LEE WP, XU Y, McFATRIDGE LA, AMENTO EP (1991) TGF-beta 1 accelerates wound healing: reversal of steroid-impaired healing in rats and rabbits. *Growth Factors* **5**, 295–304.
- BEER HD, FASSLER R, WERNER S (2000) Glucocorticoid-regulated gene expression during cutaneous wound repair. *Vitamins and Hormones* **59**, 217–239.
- BETTINGER DA, YAGER DR, DIEGELMANN RF, COHEN IK (1996) The effect of TGF-beta on keloid fibroblast proliferation and collagen synthesis. *Plastic and Reconstructive Surgery* **98**, 827–833.
- BRAND T, SCHNEIDER MD (1995) Inactive type II and type I receptors for TGF β are dominant inhibitors of TGF β -dependent transcription. *Journal of Biological Chemistry* **270**, 8274–8284.
- CHANG DJ, JI C, KIM KK, CASINGHINO S, McCARTHY TL, CENTRELLA M (1998) Reduction in transforming growth factor beta receptor I expression and transcription factor CBFal on bone cells by glucocorticoid. *Journal of Biological Chemistry* **273**, 4892–4896.
- CHANG J, MOST D, STELNICKI E, SIEBERT JW, LONGAKER MT, HUI K et al. (1997) Gene expression of transforming growth factor beta-1 in rabbit zone II flexor tendon wound healing: evidence for dual mechanisms of repair. *Plastic and Reconstructive Surgery* **100**, 937–944.
- CHARD MD, CAWSTON TE, RILEY GP, GRESHAM GA, HAZLEMAN BL (1994) Rotator cuff degeneration and lateral epicondylitis: a comparative histological study. *Annals of the Rheumatic Diseases* **53**, 30–34.
- CLARK DA, COKER R (1998) Transforming growth factor-beta. *International Journal of Biochemistry and Cell Biology* **30**, 293–298.
- CLARK RAF, McCOY GA, FOLKVORD JM, McPHERSON JM (1997) TGF-beta 1 stimulates cultured human fibroblasts to proliferate and produce tissue-like fibroplasia: a fibronectin matrix-dependent event. *Journal of Cellular Physiology* **170**, 69–80.
- CORDEIRO MF, GAY JA, KHAW PT (1999) Human anti-transforming growth factor-beta 2 antibody: a new glaucoma anti-scarring agent. *Investigative Ophthalmology and Visual Science* **40**, 2225–2234.
- FALANGA V, QIAN SW, DANIELPOUR D, KATZ MH, ROBERTS AB, SPORN MB (1991) Hypoxia upregulates the synthesis of TGF-beta 1 by human dermal fibroblasts. *Journal of Investigative Dermatology* **97**, 634–637.
- FALANGA V, GERHARDT CO, DASCH JR, TAKEHARA K, KSANDER GA (1992) Skin distribution and differential expression of transforming growth factor beta 1 and beta 2. *Journal of Dermatological Science* **3**, 131–136.
- FLANDERS KC, WINOKUR TS, HOLDER MG, SPORN MB (1993) Hyperthermia induces expression of transforming growth factor-betas in rat cardiac cells in vitro and in vivo. *Journal of Clinical Investigation* **92**, 404–410.
- FLINT MA, LYONS MF, MEANEY MF, WILLIAMS DE (1975) The Masson's staining of collagen—an explanation of an apparent paradox. *Histochemical Journal* **7**, 529–546.
- FRANK S, MADLENDER M, WERNER S (1996) Transforming growth factors β 1, β 2, β 3 and their receptors are differentially regulated during normal and impaired wound repair. *Journal of Biological Chemistry* **271**, 10188–10193.
- FUKUMURA K, MATSUNAGA S, YAMAMOTO T, NAGAMINE T, ISHIDOU Y, SAKOU T (1998) Immunolocalization of transforming growth factor-betas and type I and type II receptors in rat articular cartilage. *Anticancer Research* **18**, 4189–4193.
- GOLD LI, SUNG JJ, SIEBERT JW, LONGAKER MT (1997) Type I (RI) and type II (RII) receptors for transforming growth factor-beta isoforms are expressed subsequent to transforming growth factor-beta ligands during excisional wound repair. *American Journal of Pathology* **150**, 209–222.
- HORNER A, KEMP P, SUMMERS C, BORD S, BISHOP NJ, KELSALL AW, COLEMAN N, COMPSTON JE (1998) Expression and distribution of transforming growth factor-beta isoforms and their signaling receptors in growing human bone. *Bone* **23**, 95–102.
- ICHIKI Y, SMITH EA, LEROY EC, TROJANOWSKA M (1997) Basic fibroblast growth factor inhibits basal and transforming growth factor-beta induced collagen alpha 2(I) gene expression in scleroderma and normal fibroblasts. *Journal of Rheumatology* **24**, 90–95.
- IGNOTZ RA, MASSAGUE J (1986) Transforming growth-factor-beta stimulates the expression of fibronectin and collagen and their incorporation into the extracellular matrix. *Journal of Biological Chemistry* **261**, 4337–4345.
- JARVINEN M, JOZSA L, KANNUS P, JARVINEN TL, KVIST M, LEADBERRER W (1997) Histopathological findings in chronic tendon disorders. *Scandinavian Journal of Medicine and Science in Sports* **7**, 86–95.
- JOYCE ME, ROBERTS AB, SPORN MB, BOLANDER ME (1990) Transforming growth factor- β and the initiation of chondrogenesis and osteogenesis in the rat femur. *Journal of Cell Biology* **110**, 937–944.
- KANNUS P (1997) Etiology and pathophysiology of chronic tendon disorders in sports. *Scandinavian Journal of Medicine and Science in Sports* **7**, 78–85.

- KARIM MA, FRIZZELL S, INMAN L, SHINN M, MILLER DD (1997) In vivo role of glucocorticoids in barotrauma vascular repair and fibrosis. *Journal of Molecular and Cellular Cardiology* **29**, 1111–1122.
- KHAN KM, COOK JL, BONAR F, HARCOURT P, ASTRÖM M (1999) Histopathology of common tendinopathies. Update and implications for clinical management. *Sports Medicine* **27**, 393–408.
- KLEMPT ND, SIRIMANNE E, GUNN AJ, KLEMPT M, SINGH K, WILLIAMS C et al. (1992) Hypoxia-ischemia induces transforming growth factor beta 1 mRNA in the infant rat brain. *Brain Research. Molecular Brain Research* **13**, 93–101.
- KSANDER GA, OGAWA Y, CHU GH, McMULLIN H, ROSENBLATT JS, McPHERSON JM (1990) Exogenous transforming growth factor-beta 2 enhances connective tissue formation and wound strength in guinea pig dermal wounds healing by secondary intent. *Annals of Surgery* **211**, 288–294.
- LAIHO M, WEIS MB, MASSAGUE J (1990) Concomitant loss of transforming growth factor (TGF)-beta receptor types I and II in TGF-beta-resistant cell mutants implicates both receptor types in signal transduction. *Journal of Biological Chemistry* **265**, 18518–18524.
- LEE TY, CHIN GS, KIM WJH, CHAU D, GITTES GK, LONGAKER MT (1999) Expression of transforming growth factor beta 1, 2 and 3 proteins in keloids. *Annals of Plastic Surgery* **43**, 179–184.
- LEMAIRE I, YANG H, LAFONT V, DORNAND J, COMMES T, CANTIN MF (1996) Differential effects of macrophage- and granulocyte-macrophage colony-stimulating factors on cytokine gene expression during rat alveolar macrophage differentiation into multinucleated giant cells (MGC): role for IL-6 in type 2 MGC formation. *Journal of Immunology* **157**, 5118–5125.
- LEVINE JH, MOSES HL, GOLD LI, NANNEY LB (1993) Spatial and temporal patterns of immunoreactive transforming growth factor beta 1, beta 2, and beta 3 during excisional wound repair. *American Journal of Pathology* **143**, 368–380.
- MANKIN HJ, DORFMAN H, LIPPIELLO L, ZARINS A (1971) Biochemical and metabolic abnormalities in articular cartilage from osteo-arthritis human hips. II. Correlation of morphology with biochemical and metabolic data. *Journal of Bone and Joint Surgery* **53A**, 523–537.
- MATSUNAGA S, YAMAMOTO T, FUKUMURA K (1999) Temporal and spatial expressions of transforming growth factor-betas and their receptors in epiphyseal growth plate. *International Journal of Oncology* **14**, 1063–1067.
- McLENNAN IS, KOISHI K (1997) Cellular localisation of transforming growth factor-beta 2 and -beta 3 (TGF-beta 2, TGF-beta 3) in damaged and regenerating skeletal muscles. *Developmental Dynamics* **208**, 278–289.
- MEYER IW (1993) Wound therapy: growth factors as agents to promote healing. *Trends in Biotechnology* **11**, 387–392.
- MOVIN T, GAD A, REINHOLT FP, ROLF C (1997) Tendon pathology in long-standing achillodynia. Biopsy findings in 40 patients. *Acta Orthopaedica Scandinavica* **68**, 170–175.
- MUTSAERS S, LAURENT G (1995). Wound healing: from entropy to integrins. *The Biochemist* [Aug/Sept], 32–38
- O'KANE S, FERGUSON MW (1997) Transforming growth factor betas and wound healing. *International Journal of Biochemistry and Cell Biology* **29**, 63–78.
- PARK RW, LEE BH, KIM IS, CHOI JY, RYOO HM, LEE KS et al. (1995) Collagen synthesis in fibroblasts from keloid lesions and their responses to transforming growth factor-beta. *Korean Journal of Biochemistry* **27**, 209–217.
- PHAN SH, GHARAEI KM, McGARRY B, KUNKEL SL, WOLBER FW (1992) Regulation of rat pulmonary artery endothelial cell transforming growth factor-beta production by IL-1 beta and tumor necrosis factor-alpha. *Journal of Immunology* **149**, 103–106.
- QUAGLINO D, NANNEY LB, DITESHEIM JA, DAVIDSON JM (1991) Transforming growth factor-beta stimulates wound healing and modulates extracellular matrix gene expression in pig skin: incisional wound model. *Journal of Investigative Dermatology* **97**, 34–42.
- RILEY GP, HARRALL RL, CAWSTON TE, HAZLEMAN BL, MACKIE EJ (1996) Tenascin-C and human tendon degeneration. *American Journal of Pathology* **149**, 933–943.
- RISER BL, LADSON WS, SHARBA A, CORTES P, DRAKE K, GUERIN CJ et al. (1999) TGF-beta receptor expression and binding in rat mesangial cells: modulation by glucose and cyclic mechanical strain. *Kidney International* **56**, 428–439.
- ROBERTS AB, SPORN MB, ASSOIAN RK, SMITH JM, ROCHE NS, WAKEFIELD LM et al. (1986) Transforming growth-factor type-beta—rapid induction of fibrosis and angiogenesis in vivo and stimulation of collagen formation in vitro. *Proceedings of the National Academy of Sciences of the USA* **83**, 4167–4171.
- ROBINSON CJ (1993) Growth factors: therapeutic advances in wound healing. *Annals of Medicine* **25**, 535–538.
- SANTILLI SM, FIEGEL VD, ALDRIDGE DE, KNIGHTON DR (1991) Rabbit aortic endothelial cell hypoxia induces secretion of transforming growth factor beta and augments macrophage adhesion in vitro. *Annals of Vascular Surgery* **5**, 429–438.
- SCHMID P, ITIN P, CHERRY G, BI C, COX DA (1998) Enhanced expression of transforming growth factor-beta type I and type II receptors in wound granulation tissue and hypertrophic scar. *American Journal of Pathology* **152**, 485–493.
- SHAH M, FOREMAN DM, FERGUSON MWJ (1995) Neutralisation of TGF- β 1 and β 2 or exogenous addition of TGF- β 3 to cutaneous rat wounds reduces scarring. *Journal of Cell Science* **108**, 985–1002.
- SZABO G, MANDREKAR P, GIROUARD L, CATALANO D (1996) Regulation of human monocyte functions by acute ethanol treatment: decreased tumor necrosis factor-alpha, interleukin-1 beta and elevated interleukin-10, and transforming growth factor-beta production. *Alcoholism Clinical and Experimental Research* **20**, 900–907.
- VILLIGER PM, KUSARI AB, TEN DIJKE P, LOTZ M (1993) IL-1 beta and IL-6 selectively induce transforming growth factor-beta isoforms in human articular chondrocytes. *Journal of Immunology* **151**, 3337–3344.
- WANG X, SMITH P, PU LL, KIM YJ, KO F, ROBSON MC (1999) Exogenous transforming growth factor beta(2) modulates collagen I and collagen III synthesis in proliferative scar xenografts in nude rats. *Journal of Surgical Research* **87**, 194–200.
- WRANA JL, ATTISANO L, WIESER R, VENTURA F, MASSAGUE J (1994) Mechanism of activation of the TGF-beta receptor. *Nature* **370**, 341–347.
- WU Y, HAUGEN JD, ZINSMEISTER AR, KUMAR R (1997) 1 alpha,25-dihydroxyvitamin D3 increases transforming growth factor and transforming growth factor receptor type I and II synthesis in human bone cells. *Biochemical and Biophysical Research Communications* **239**, 734–739.
- YOSHIZAWA M, MIYAZAKI H, KOJIMA S (1998) Retinoids potentiate transforming growth factor-beta activity in bovine endothelial cells through up-regulating the expression of transforming growth factor-beta receptors. *Journal of Cell Physiology* **176**, 565–573.
- ZHOU LJ, ONO I, KANEKO F (1997) Role of transforming growth factor-beta 1 in fibroblasts derived from normal and hypertrophic scarred skin. *Archives of Dermatological Research* **289**, 646–652.