

Contents lists available at [ScienceDirect](https://www.sciencedirect.com)

## International Journal of Surgery Case Reports

journal homepage: [www.casereports.com](http://www.casereports.com)

# Inflammatory Breast Cancer in Men: A rare clinical case report and a literature review

Angeline Tanhueco\*, Mina M.G. Youssef

Department of Breast Surgery, Norfolk and Norwich University Hospital, Norwich, UK

## ARTICLE INFO

### Article history:

Received 7 February 2021

Received in revised form 21 February 2021

Accepted 21 February 2021

Available online 24 February 2021

### Keywords:

Male breast cancer

Case report on male inflammatory breast cancer

Inflammatory breast cancer in men

Delays in diagnosis for male breast cancer

## ABSTRACT

**INTRODUCTION AND IMPORTANCE:** The initial misdiagnosis and delayed treatment for inflammatory breast cancer in men is brought about by its rarity and lack of readily available guidelines on pathways. **CASE PRESENTATION:** A 78-year-old male presented to the breast clinic with an abscess and was later diagnosed with inflammatory breast cancer. He presented with an abscess and was initially treated with antibiotics. Imaging showed a large left breast mass consistent with inflammatory carcinoma with axillary lymph node involvement. Patient was started on Tamoxifen as a bridge for surgery with no response. He eventually had a mastectomy and axillary clearance with the histology confirming the diagnosis and tumour emboli in the lymphatic vessels. Chemotherapy, radiation and dual hormone therapy were included in the adjuvant treatment plan. Two episodes of neutropenic sepsis led to completing only five out of six planned chemotherapy cycles.

**CLINICAL DISCUSSION:** A review of literature and the reported cases was done by the team to contribute to the little information published about the disease and its management. The presented to the breast clinic during the height of the SARS-CoV-2 pandemic. The global impact of SARS-CoV-19 made surgical teams find ways to lessen elective lists to give way for patients affected during the pandemic.

**CONCLUSION:** Very few cases of inflammatory breast cancer have been reported in men. The diagnosis can be missed leading to delay in management. Management can be challenging and complex.

© 2021 Published by Elsevier Ltd on behalf of IJS Publishing Group Ltd. This is an open access article under the CC BY-NC-ND license (<http://creativecommons.org/licenses/by-nc-nd/4.0/>).

## 1. Introduction and importance

Breast cancer in men is a rare disease worldwide [1]. Because of this, most treatment pathways are based on results of trials on women with the diagnosis. This is further supported by the fifth version of the National Comprehensive Cancer Network Guidelines released in 2020 stating that the management of breast cancer in men and women is similar overall with special considerations pertinent to male patients [3]. Unusual presentations, more specifically breast cancer that is inflammatory in nature, poses challenges on its management. Inflammatory breast cancer is commonly associated with bad prognosis [2]. Reducing delays in diagnosis by early recognition of the disease is key. The limited data on male inflammatory breast cancer that is currently published serves only as a guide, highlighting the subtle similarities and major differences in the presentation and treatment of male inflammatory breast cancer. Interestingly, the manifestation of the condition presented in the cases currently published has not shown a definitive pattern of disease progression. This case report discusses a male patient diagnosed with inflammatory breast cancer, further sup-

ported by a literature review. The patient has given the authors the consent to discuss the case in this article, along with photos provided by the patient and those taken in the clinical setting. This case report followed the guidelines set by the SCARE criteria [18].

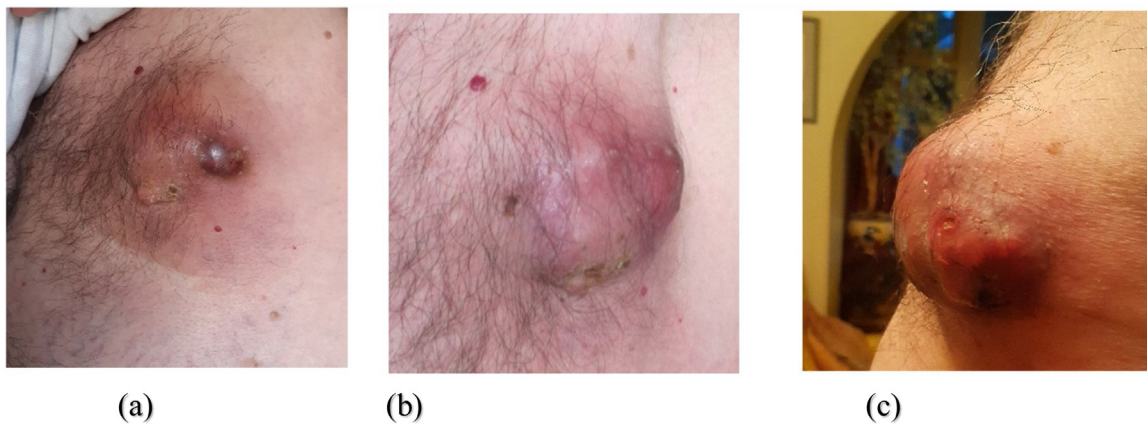
## 2. Case presentation

A 78-year-old man was referred to the one-stop breast clinic with a red, tender and hot swelling lump on his left breast with pus discharge (Fig. 1a). The condition has developed over a month before and was treated in the primary care with no improvement. He was given a two-week course of Flucloxacillin 500 mg TDS. That treatment resulted in the development of a sinus discharging pus with a residual abscess underneath. He has a history of bilateral simple gynecomastia diagnosed following a previous referral to the breast clinic three years ago. He is not diabetic, doesn't smoke and has no family history of breast cancer. His past medical history includes Hypertension, Atrial Fibrillation, Diabetes and Hyperlipidaemia. His regular medications include Allopurinol, Amlodipine and Warfarin.

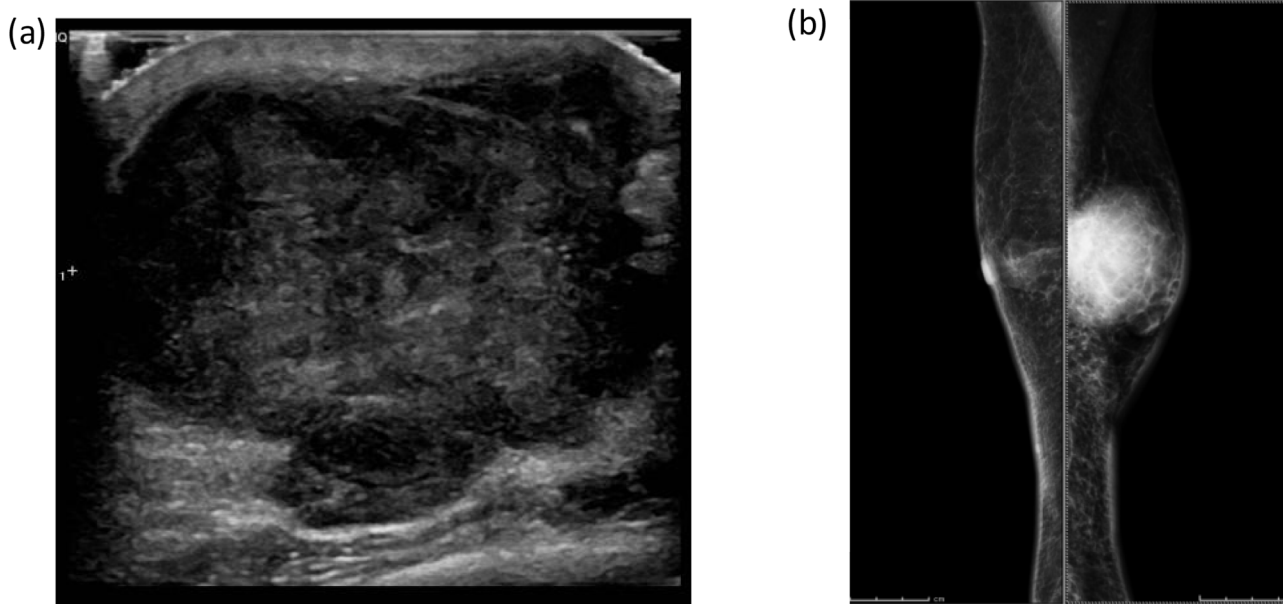
When he was examined, the large bilateral gynecomastia was noted, and an abscess/inflammatory mass was present on the left side. At that stage, the clinician organised an ultrasound scan as a mammogram was not possible due to severe pain. Ultrasound

\* Corresponding author at: Norfolk and Norwich University Hospital, Colney Lane, Norwich NR4 7UY, UK.

E-mail address: [angeline.tanhueco@nnuh.nhs.uk](mailto:angeline.tanhueco@nnuh.nhs.uk) (A. Tanhueco).



**Fig. 1.** Photos showing disease progression (all provided by the patient for use in literature and education): (a) Taken in March 2020. (b) Taken in June 2020, about three months from starting Tamoxifen. (c) Taken in August 2020.



**Fig. 2.** (a) Ultrasound at original presentation showing an excess of 50 mm abscess in the left retroareolar region that failed to yield any aspirate fluid. Clinical management was recommended. (b) Medio-Lateral Oblique mammographic view showing a well margined round 60 mm mass with overlying skin thickening on the left breast. The appearances are consistent with an inflammatory left breast carcinoma.

scan showed a large abscess in the left retroareolar region (Fig. 2a). Aspiration was attempted but did not yield any fluid. He was given the advice to continue the same antibiotic treatment and another appointment was arranged for clinical reassessment of improvement of the abscess. At that point, a mammogram was performed showing shows a well-margined, round 60 mm mass with overlying skin thickening on the left breast (Fig. 2b). The right side showed simple gynecomastia.

The repeat ultrasound showed an irregular vascularised hypoechoic mass measuring up to 55 mm seen to directly invade the thickened overlying skin in the area of the central left breast. Ultrasound to the left axilla further showed at least four enlarged and morphologically abnormal lymph nodes. Radiologic studies report that the appearances are consistent with an inflammatory left breast carcinoma and metastatic axillary lymph nodes.

To complete the triple assessment, a core biopsy was done for the left breast and the axillary lymph node.

The biopsy from the breast and the node showed a grade 2 Invasive ductal carcinoma, oestrogen receptor positive. The case was discussed at the MDT (Multidisciplinary team) meeting at the peak

of the first wave of the Covid-19 pandemic. Due to that situation, the MDT recommended primary bridging hormone treatment, and the patient was started on Tamoxifen 20 mg tablets. This was considering the advanced nature of the disease and the diagnosis of inflammatory breast cancer. Staging investigations were organised and revealed no distant metastasis.

The plan was to downstage the tumour with the primary hormone treatment in anticipation of surgery. Three months later, the patient was seen in the clinic for reassessment following hormone treatment. There was no real response with Tamoxifen. This led to the patient being listed for mastectomy and axillary clearance (Fig. 3).

During the surgery performed by the patient's consultant breast surgeon, chest wall involvement was found at the lateral area of the breast. This suggests how aggressive the tumour was as the attachment to the muscle was not visible in previous imaging. Final surgical histology revealed no cellular response (Miller and Payne grade 1) to Tamoxifen. The tumour size has increased from 60 mm on initial imaging to 90 mm. Muscle involvement was confirmed and 4 out of the 22 harvested lymph nodes contained metastases.

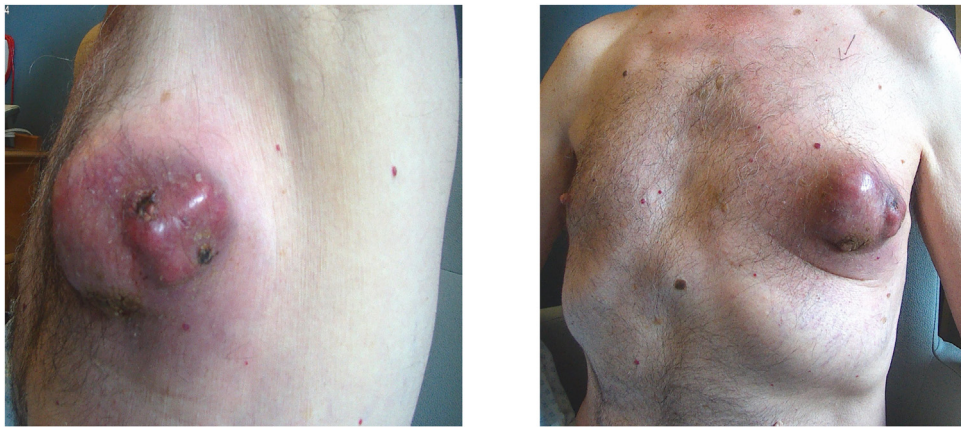


Fig. 3. Photos taken on the day of surgery, five months since day of diagnosis.

The presence of tumour emboli was confirmed in 1–2 dermal lymphatic vessels.

At the post-operative MDT, the question of further systemic treatment was discussed. It was clear that the tumour unusually didn't show any response to Tamoxifen. Therefore, a GnRH (Gonadotropin Releasing Hormone) analogue plus an aromatase inhibitor was recommended for adjuvant endocrine treatment as per the National Comprehensive Cancer Network Guidelines [3]. Post-mastectomy radiotherapy was recommended due to the involvement of the deep margin and axillary lymph nodes.

The MDT also recommended to discuss chemotherapy. This decision would have to be balanced against the medical comorbidities of the patient versus the definite benefit of chemotherapy in his case.

The suggestion, rationale and plans for chemotherapy were explained to the patient by the oncology team. The Fluorouracil, Epirubicin, Cyclophosphamide and Docetaxel (FEC-T) six-cycle regime, along with its pathway and risks, were

discussed with the patient and he accepted the recommendations.

At the end of the fifth cycle, the team met with the patient to discuss omitting the final cycle as the patient suffered neutropenic sepsis twice. Moving forward, the patient was satisfied with the plan and agreed to proceed with Radiotherapy and dual anti-hormone treatment.

### 3. Literature review

Little is known about Inflammatory Breast Cancer (IBC) in men hence, diagnosis may be missed and often delayed. As in the case of females, IBC diagnosis is largely a clinical diagnosis. This accounts for the possible delay in diagnosis of this condition. Treatment for IBC in men is commonly taken after therapeutic responses seen in females diagnosed with the disease [4]. Table 1 shows the summary of reported cases of male IBC found in English literature, now

Table 1  
Inflammatory Breast Cancer in male.

Case No	Author	Age (Years)	Clinical Presentation	Nodal Disease at presentation	Distant Metastases	Tumour Biology	Treatment
1	Treves [11]	66	Painless mass of the axilla	Axillary	None	Not reported	–
2	Treves [11]	72	Erythema and swelling of bilateral anterior chest wall	Neck, supraclavicular and bilateral inguinal	None	Not reported	–
3	Treves [11]	70	Erythema of left breast	Axillary	None	Not reported	–
4	Sina and Samorodin [12]	72	Erythema of bilateral anterior chest wall	Axillary	None	Not reported	–
5	Yamamoto et al. [13]	68	Erythema and swelling of left anterior chest wall	Axillary	Pleura	Not reported	Systemic chemotherapy
6	Spigel et al. [14]	48	Erythema and thickening of right breast	None	None	Not reported	Neoadjuvant chemotherapy and mastectomy Hormonal therapy
7	Skarin [15]	69	Diffuse rash of left anterior chest wall/severe back pain	None	Bone	Not reported	Systemic chemotherapy
8	Choueiri et al. [16]	56	Neck swelling/ warmth of the right anterior chest wall/gynecomastia	None	None	ER (-), PR (-), HER2/neu (-)	Mastectomy and adjuvant chemotherapy with radiation Systemic Chemotherapy
9	Morita et al. [6]	72	Erythema of the right chest wall/right breast mass	Axillary	None	ER (-), PR (-)	Hormone Therapy
10	Hyakudomi et al. [5]	85	Erythema and induration of the right chest wall	Axillary	Bone	ER (-), PR (-), HER2/neu (-)	Systemic chemotherapy and radiotherapy Mastectomy, Systemic Chemotherapy, Radiotherapy and Hormone Therapy
11	Loewen et al. [4]	51	Erythema and peau 'd orange of right breast	Axillary and bilateral cervical chain	Contralateral supraclavicular	ER (+), PR (+), HER2/neu (-)	Systemic chemotherapy and radiotherapy
12	Tashima et al. [17]	67	Multiple small masses of the left anterior chest wall	–	Skin	ER (+), PR (+), HER2/neu (-)	Mastectomy, Systemic Chemotherapy, Radiotherapy and Hormone Therapy
13	Current	78	Tender hot swelling of left breast with pus discharge	Axillary	None	ER (+), HER2/neu (-)	



accounting to 13 patients with an age range of 48–85 years old, including the current patient.

Generally, 92 % of male breast cancers are ER positive [1]. Out of the now 13 reported cases of inflammatory breast cancer in men, six were tested for ER, PR and HER2 expression, two of which were triple negative [1,5] and one tested for ER and PR only, turned out receptor negative [6].

This patient, who is now the 13th reported case of inflammatory breast cancer in men, is only the third hormone receptor positive reported inflammatory breast cancer case in men. The first reported ER positive patient was initially treated with Exemestane only, due to lack of medical insurance and patient's apprehensions. At the 12-month follow up, the patient has not reported any medication intolerance and continued the treatment with Everolimus and radiation therapy [4].

The details of the systemic treatment of eight out of the first 12 cases were described in the literature. Six out of eight of these patients were given chemotherapy [5].

Of the previous cases collated, two had no data on Lymph node involvement and only one had no actual lymph node involvement. The rest, including the current case, had at least an axillary lymph node metastasis [4]. Evidently, there is still marked delay in identifying this aggressive disease causing a higher likelihood that it has already reached the lymph nodes once the diagnosis is made.

#### 4. Discussion

Inflammatory breast cancer is said to be a clinico-pathological diagnosis [2]. What is generally agreed is its abrupt onset (no more than 6 months) with erythema involving more than a third of the breast [2]. Though pathognomonic and common in IBC, dermal lymphatic invasion was found out to be not required to establish a diagnosis [2].

Generally, for breast cancer in men, Tamoxifen is commonly used because of its efficacy in the both adjuvant and palliative settings [7]. There is no available literature to support its use in the neo-adjuvant setting and therefore the evidence is very limited.

Though Tamoxifen remains to be the first line hormone therapy for male breast cancer [7], occasions where it is not an option for treatment for men who test positive for oestrogen receptors is not unheard of. Deep vein thrombosis and weight gain are reported toxicities warranting discontinuation of the treatment [1,7]. These cause a large proportion of men to stop treatment before 5 years [1].

In men, single-agent adjuvant treatment with an aromatase inhibitor has been associated with inferior outcomes compared to Tamoxifen alone, likely due to inadequate estradiol suppression, and is not recommended [3].

This course of treatment was displayed in a case reported by Jiang et al. [8]. This was of a man who was initially treated with Letrozole as first line endocrine treatment. This was discontinued after 7 months because of disease progression. This was followed by Goserelin plus Anastrozole shortly after distant metastasis was found. This treatment provided stability of the disease for a year prior to progression. Exemestane replaced Anastrozole for the next 11 months, again, providing stability before further progression [8].

The extent of muscle involvement that was seen during the mastectomy of the patient indicated adjuvant radiotherapy. Men are more likely to be offered post mastectomy chest wall radiation therapy (PMRT) due to concern of adequate surgical margins even in small tumours and the higher incidence of nipple or skin involvement [1]. A radiotherapy boost may be administered to his chest wall to address this.

The risk of gynecomastia and breast cancer coexists in high oestrogen states [9]. This association is bringing into question the likelihood of these two separate conditions to co-exist; challenging

the initially proposed idea that gynecomastia increases the risk for breast cancer. The current patient still presents with gynecomastia on the contralateral side.

The global event brought about by SARS-CoV-19 affected the elective surgical activity immensely. More manpower support was needed for the critical care departments who care for patients with the coronavirus disease 2019, hence a huge number of elective surgeries were put on hold [10]. Surgical teams had to prioritise elective lists and alter treatment paths for patients who do not require immediate surgery. It can be argued that the patient could have had chemotherapy as a neo adjuvant treatment. The situation in the healthcare system at the time of presentation required a conscientious decision to attempt downstaging the tumour prior to surgery. This led to the discovery of having no response to hormone treatment, following discussion for more treatment.

#### 5. Conclusion

The limited data that we currently have for male inflammatory breast cancer still would not sufficiently provide a standard pathway for treatment. Men will still experience delay in diagnosis and treatment due to the lack of published information and reliable treatment pathways.

This reported case and literature review aim to add to the available body of evidence available for the management of this rare clinical condition which can represent a challenge for clinicians managing breast cancer in men.

#### Declaration of Competing Interest

The authors report no declarations of interest.

#### Sources of funding

The research done for this case report was not supported by sponsors for funding.

#### Ethical approval

The case report does not require ethical approval.

#### Consent

The patient has consented to the study and reporting of his case, he has provided photos to support the endeavour and signed a consent form to document this.

#### Author contribution

**Angeline Tanhueco:** Methodology, Investigation, Resources, Writing- Original Draft Preparation, Visualisation.

**Mina Youssef:** Conceptualisation, Resources, Review and Editing, Supervision.

#### Registration of research studies

Not applicable.

#### Guarantor

Mr. Mina Youssef.

#### Provenance and peer review

Not commissioned, externally peer-reviewed.

## References

- [1] S. Jain, W.J. Gradishar, Male Breast Cancer. *The Breast: Comprehensive Management of Benign and Malignant Diseases*, 76, 2018, pp. 974–980, <http://dx.doi.org/10.1016/B978-0-323-35955-9.00076-3>.
- [2] G. Cserni, et al., Inflammatory breast cancer: the pathologists' perspective, *Eur. J. Surg. Oncol.* (2018), <http://dx.doi.org/10.1016/j.ejso.2018.04.001>, Elsevier.
- [3] Breast Cancer, NCCN Clinical Practice Guidelines in Oncology. Ver 5, 2020, [www.nccn.org/patients](http://www.nccn.org/patients) (Accessed 3 September 2020).
- [4] A.H. Loewen, et al., Case report: hormone receptor positive, HER2/neu negative inflammatory breast cancer in a male patient, *S. D. Med.* 68 (October (10)) (2015), 435–7, 439–440. PMID:26630832.
- [5] M. Hyakudomi, T. Inao, Y. Minari, et al., A Case of Male Inflammatory Breast Cancer in International Cancer Conference Journal, 2, Springer, 2013, pp. 183–187, <http://dx.doi.org/10.1007/s13691-013-0087-9>.
- [6] Y. Morita, et al., A case report of male inflammatory breast cancer, *J. Jpn. Surg. Assoc.* 66 (1) (2005) 36–40.
- [7] M.H. Khan, et al., Hormone therapy for breast cancer in men, *Clin. Breast Cancer* 15 (4) (2015) 245–250, <http://dx.doi.org/10.1016/j.clbc.2015.01.007>, Elsevier Inc.
- [8] H. Jiang, et al., Goserelin plus endocrine treatments maintained long-term clinical benefit in a male patient with advanced breast cancer, *World J. Surg. Oncol.* 12 (2014) 393 <http://www.wjso.com/content/12/1/393>.
- [9] C.B. Niewoehner, A.E. Schorer, Gynecomastia and breast cancer in men, *BMJ* 336 (2008) 709–713, <http://dx.doi.org/10.1136/bmj.39511.493391.BE>.
- [10] J.C. Glaseby, A. Bhangu, et al., Elective cancer surgery in COVID-19-free surgical pathways during the SARS-CoV-2 pandemic: an international, multicenter, comparative cohort study, *J. Clin. Oncol.* 38 (2020), <http://dx.doi.org/10.1200/JCO.20.01933>.
- [11] N. Treves, Inflammatory carcinoma of the breast in the male patient, *Surgery* 34 (5) (1953) 810–820.
- [12] B. Sina, C.S. Samorodin, Bilateral inflammatory carcinoma of the male breast, *Cutis* 33 (5) (1984) 501–502.
- [13] T. Yamamoto, K. Iriyama, T. Araki, Male inflammatory breast cancer, *Surg. Today* 27 (7) (1997) 669–671.
- [14] J.J. Spigel, W.P. Evans, M.D. Grant, et al., Male inflammatory breast cancer, *Clin. Breast Cancer* 2 (2) (2001) 153–155.
- [15] A. Skarin, Unusual presentations of malignancy. Case 1. Male inflammatory (?) breast cancer, *J. Clin. Oncol.* 19 (13) (2001) 3288–3289.
- [16] M.B. Choueiri, et al., Inflammatory breast cancer in a male, *N. Z. Med. J.* 118 (1218) (2013) 1566 <http://www.nzma.org.nz/journal/118-1218/1566/>.
- [17] Y. Tashima, et al., A case report of luminal a male inflammatory breast cancer that was difficult to treat because of trousseau syndrome, *J. UOEH* 41 (2) (2019) 211–216.
- [18] R.A. Agha, T. Franchi, C. Sohrabi, G. Mathew, for the SCARE Group, The SCARE 2020 guideline: updating consensus Surgical CASE REport (SCARE) guidelines, *Int. J. Surg.* 84 (2020) (article in press).

## Open Access

This article is published Open Access at [sciencedirect.com](https://www.sciencedirect.com). It is distributed under the [IJSCR Supplemental terms and conditions](#), which permits unrestricted non commercial use, distribution, and reproduction in any medium, provided the original authors and source are credited.