

Imaging of Giant Cell Arteritis – Recent Advances

Word count: 9805.

Claire E. Owen PhD^{1,2}

Max Yates PhD^{3,4}

David F.L. Liew FRACP^{1,2}

Aurora M.T. Poon FRACP^{1,5}

Helen I. Keen FRACP^{6,7}

Catherine L. Hill MD^{8,9}

Sarah L. Mackie PhD^{10,11}

Corresponding author:

Dr Claire Owen

Rheumatology Department

Austin Health – Repatriation Campus, Level 1, North Wing

300 Waterdale Road,

Heidelberg VIC 3084, Australia.

Email: claire.owen@austin.org.au

Telephone: +613 9496 4013

Facsimile: +613 9496 4012

¹ Department of Rheumatology, Austin Health, Heidelberg, Victoria, Australia.

² Department of Medicine, University of Melbourne, Parkville, Victoria, Australia.

³ Department of Rheumatology, Norfolk and Norwich University Hospital, Norwich, United Kingdom.

⁴ Norwich Medical School, University of East Anglia, Norwich, United Kingdom.

⁵ Department of Molecular Imaging and Therapy, Austin Health, Heidelberg, Victoria, Australia.

⁶ Department of Rheumatology, Fiona Stanley Hospital, Murdoch, Western Australia, Australia.

⁷ Medical School, University of Western Australia, Perth, Western Australia, Australia.

⁸ Rheumatology Unit, Royal Adelaide Hospital, Adelaide, South Australia, Australia.

⁹ Discipline of Medicine, The University of Adelaide, Adelaide, South Australia, Australia.

¹⁰ Leeds Institute of Rheumatic and Musculoskeletal Medicine, University of Leeds, Leeds, United Kingdom

¹¹ NIHR-Leeds Biomedical Research Centre, Leeds Teaching Hospitals NHS Trust.

Imaging of Giant Cell Arteritis – Recent Advances

Claire E. Owen, Max Yates, David FL Liew, Aurora MT Poon, Helen I. Keen, Catherine L. Hill & Sarah L Mackie

Abstract

Imaging is increasingly being used to guide clinical decision-making in patients with giant cell arteritis (GCA). While ultrasound has been rapidly adopted in fast-track clinics worldwide as an alternative to temporal artery biopsy for the diagnosis of cranial disease, whole body PET/CT is emerging as a potential gold standard test for establishing large vessel involvement. However, many unanswered questions remain about the optimal approach to imaging in GCA. For example, it is uncertain how best to monitor disease activity, given there is frequent discordance between imaging findings and conventional disease activity measures, and imaging changes typically fail to resolve completely with treatment. This chapter addresses the current body of evidence for the use of imaging modalities in GCA across the spectrum of diagnosis, monitoring disease activity, and long-term surveillance for structural changes of aortic dilatation and aneurysm formation, and provides suggestions for future research directions.

Words: 145.

Key Words

Giant cell arteritis; diagnosis; monitoring; imaging; ultrasound; magnetic resonance imaging; positron emission tomography; computed tomography; angiography.

Introduction

Over the past decade, imaging has been readily adopted to facilitate early diagnosis of the most common immune-mediated form of large vessel vasculitis (LVV), giant cell arteritis (GCA).(1) In the 2022 ACR/EULAR classification criteria, imaging findings including a positive halo sign on temporal artery ultrasound, ¹⁸F-fluorodeoxyglucose (¹⁸F-FDG) uptake in the arterial wall of the aorta on positron emission tomography (PET) and bilateral axillary involvement using ultrasound, angiography (computed tomography [CT], magnetic resonance imaging [MRI] or catheter-based) or PET/CT have been incorporated into the definition of GCA for research purposes.(2) This shift to incorporate imaging alongside temporal artery biopsy (TAB) in the criteria reflects the accumulated evidence supporting the adequacy of an imaging-based GCA diagnosis, compared to traditional TAB, among patients with cranial manifestations such as headache, scalp tenderness, jaw claudication or acute visual loss. Another key factor driving acceptance of imaging as a diagnostic tool, is the increasing recognition of the extra-cranial form of GCA, known as large-vessel GCA (LV-GCA), that affects the aorta and its main branches. Whilst the need for histopathological diagnosis will remain in certain situations (for example, an individual with a high pre-test probability of GCA but negative imaging), imaging modalities additionally provide the potential of surveillance for the development of long-term, life-threatening vascular complications and may prove useful in assessing the patient's response to treatment. Following the therapeutic revolution that the landmark GIACTA trial has spurred in GCA, disease activity monitoring while on treatment has become one of profound clinical significance.(3) In the absence of a reliable biomarker due to the effect of interleukin-6 (IL-6) blockade upon conventional systemic inflammatory markers like C-reactive protein (CRP) and erythrocyte sedimentation rate (ESR), imaging offers an appealing means by which to assess disease activity, providing the results can be shown to be reliable, reproducible and clinically relevant. Moreover, any modality utilised in this manner should be widely available and performed by a provider with sufficient expertise.

In the following chapter, the fast-evolving literature in this field will first be reviewed regarding the present-day performance of modalities including ultrasound, MRI and PET/CT for the diagnosis of GCA. Emerging data for the utilisation of imaging to monitor disease activity will additionally be covered, along with the available evidence regarding monitoring for the development of vascular complications.

A. Diagnosis

In 1932, Bayard T. Horton reported that he had discovered a new disease – GCA, with his use of TAB in the diagnostic workup strongly influencing much of the literature that has followed. Interpretation of TAB is not straightforward due to skip lesions and heterogeneity of histological findings, and hence significant variation in sensitivity and specificity values are reported.(4, 5) A meta-analysis recently established an estimated sensitivity of 77%, however this together with the invasive nature of this test have prompted a push in the modern medical era for an alternative approach.(6, 7) Imaging was rapidly recognised as a potential solution, however the most appropriate modality tends to be determined by the vascular territory under evaluation. For cranial-GCA (c-GCA), ultrasound and, increasingly, MRI are preferred, whilst MR angiography (MRA) and PET/CT prove better suited to cases of suspected LV-GCA. Clinicians should though remain cognisant of potential limitations when ordering these investigations, including the likelihood of a false negative result owing to prior steroid exposure, and false positives from relevant differentials among an elderly population, such as atherosclerosis.(8)

Ultrasound

- Cranial disease:

Ultrasound was first used in GCA in a bid to increase the TAB positivity rate by identifying appropriate sites for biopsy, although it still remains unclear whether this substantially improves sensitivity.(9-11) By contrast, its ability to identify inflammation-related abnormalities in the arterial wall is now well-established. The pivotal Temporal Artery Biopsy and Ultrasound in the Diagnosis of GCA (TABUL) study provided early evidence for temporal artery ultrasound (TAU) being incorporated into GCA diagnostic pathways; the addition of TAU as a preliminary test being demonstrated to be cost-effective in reducing the number of TABs required, without substantial loss of diagnostic accuracy.(12) This, coupled with higher sensitivity of TAU (albeit slightly lower specificity compared to TAB) has encouraged uptake and spread of this approach to GCA diagnosis. These new “fast-track” diagnostic services have even claimed to reduce the rates of GCA-related visual loss in some centres, although this welcome improvement is not necessarily a direct result of the ultrasound test itself.(13, 14)

The halo sign (Figure 1), initially reported by Schmidt et al., describes a homogeneous, hypoechoic arterial wall thickening attributed to vascular wall oedema and has now been studied in multiple meta-analyses reporting sensitivity values of 68-88% and specificity of 77-91%.(5, 15) The inability to compress the temporal artery when applying pressure with the ultrasound probe, known as the compression sign, represents an additional suggestive finding (sensitivity 79% and specificity 100% in the initial report).(16) Accordingly, the Outcome Measures in Rheumatology Clinical Trials (OMERACT) Large Vessel Vasculitis Working Group have determined the halo and compression signs to be the most reliable indicators of c-GCA.(17) The experience of the clinician and equipment utilised should also be carefully considered, with the recommendation that >300 examinations be undertaken before a sonographer achieves competence

and a probe >15 MHz utilised to optimise scan results. Cut-offs for defining the “halo” have reduced over time as ultrasound equipment has become more sophisticated, however normal temporal artery intima-media thickness (IMT) values depend both on the size of the arteries (women tend to have smaller arteries than men) and on comorbid age-related intimal thickening, especially in individuals with a large burden of atherosclerosis.(18) Finally, it is worth noting that a significant difference in halo IMT is observed as early as ≥ 4 days post prednisolone commencement, hence TAU should be undertaken as soon as practically possible in the diagnostic work-up of a patient with symptoms suggestive of GCA.(19)

- Extra-cranial disease:

Whilst almost all large and medium arteries aside from the thoracic aorta can be assessed by ultrasound, imaging studies using this modality in GCA have concentrated on findings at the vertebral, carotid, subclavian and axillary arteries, which are frequently affected in LV-GCA. Like the cranial vessels, it is possible to assess for intima-media thickening in these arterial territories. Early PET data had suggested that up to 80% of GCA patients exhibited extra-cranial involvement at diagnosis, but ultrasound studies in larger, unselected GCA cohorts have not replicated such results.(20) Accordingly, the 2018 EULAR recommendations for the use of imaging in large vessel vasculitis advocate evaluation of the axillary arteries if TAU proves negative or indeterminate.(21) This approach is further substantiated by results of several recent studies demonstrating a substantive increase in sensitivity for confirming GCA as the diagnosis when axillary artery scanning is added.(22-24) Notably, the greatest benefit for routinely imaging the large vessels was found among those patients with a low pre-test probability of c-GCA. Utilisation of an extended ultrasound protocol (comprising temporal, axillary, brachiocephalic and carotid arteries) has been demonstrated to have superior diagnostic performance (sensitivity 95% and specificity 98%), but at the cost of increased examination time, which could compromise feasibility in a “fast-track” context. By contrast, inclusion of the subclavian arteries does not appear to be especially helpful.(25)

MRI

- Cranial disease:

The superior image resolution offered by MRI means that it can be utilised to assess most vascular territories throughout the body. Since the seminal publication of Bley et al. documented mural inflammatory changes (wall thickening and contrast enhancement) of the superficial temporal artery, vascular MRI has been recognised as a potential non-invasive test for GCA.(26) Results of a meta-analysis that informed the 2018 Update of the EULAR Recommendations for the Management of Large Vessel Vasculitis found a sensitivity of 73% and specificity of 88% compared with clinical c-GCA diagnosis as the reference standard, and sensitivity of 93% and specificity of 88% compared with TAB.(27) With the development of newer 3-dimensional techniques (3D), even better specificity values (91%) have since been reported.(28)

Unlike ultrasound, MRI offers the added advantage of being able to image smaller intra-cranial vessels and orbital structures. For example, posterior ciliary artery involvement (the most common cause of permanent visual loss in GCA) can be appreciated on 3D T1-weighted black-blood MRI.(29) This finding is recognised as highly sensitive and specific for arteritic, acute ischaemic optic neuropathy and can even precede the development of fundoscopic changes, thereby potentially identifying a “vision-at-risk” patient subset. Within the orbit, a range of abnormalities associated with GCA

have additionally been documented using MRI including non-specific orbital enhancement, optic nerve parenchymal enhancement, perineural sheath enhancement and optic chiasmal enhancement.(30) Whilst there does not appear to be a clear-cut correlation between such imaging findings and the development of visual symptoms, it is apparent that almost one-third of GCA patients possess intra-orbital changes on T1-weighted black-blood MRI.(31) Moving forwards, it will be essential to establish the prognostic significance of these abnormalities and gain an understanding of the anticipated treatment response following the initiation of glucocorticoid therapy.

- Extra-cranial disease:

MRA is the preferred imaging modality for diagnosis of Takayasu arteritis (TAK), which is the second commonest LVV, but is less frequently utilised for this purpose in LV-GCA despite reasonable diagnostic performance. In both TAK and LV-GCA, concentric wall thickening with mural contrast enhancement and oedema on T2-weighted images can be appreciated, together with structural lesions including stenosis, occlusion and aneurysm formation.(32) The lack of radiation required for MRI offers an advantage over CT angiography (CTA), but drawbacks include tolerability issues for patients with claustrophobia, longer acquisition time, inability to image patients with metallic implants, potential for adverse reactions to gadolinium-based contrast agents, lack of specificity in distinguishing segments of active vasculitis from atherosclerosis, and the absence of standardised definitions for arteriographic abnormalities, specifically wall thickness.(33) As compared with PET/CT, MRA is also limited to imaging the aorta and its branches in a single examination rather than providing an overview of vascular territories throughout the whole body.

¹⁸F-FDG PET/CT

- Cranial disease:

The low-image resolution and proximity of the PET avid brain to the cranial arteries had traditionally precluded the use of this modality to diagnose c-GCA. More recently however, improved time-of-flight technology has enabled closer examination of these smaller vessels.(34, 35) In the GAPS study, Sammel et al. utilised a new generation PET/CT scanner with 1mm CT reconstruction to image the vasculature of the head, neck and chest in patients with suspected GCA.(35) Results established a sensitivity of 92% and specificity of 85% compared with TAB as the reference standard, with a sensitivity of 71% and specificity of 91% achieved when evaluated against clinical diagnosis. The scan field did have to be limited to above the diaphragm due to the intensity of the protocol required and hence vascular wall ¹⁸F-FDG uptake could only be compared to the background intensity of the blood pool in the superior vena cava (rather than the liver). Despite this, 18 arterial segments could be assessed including bilateral temporal, occipital, maxillary, vertebral, carotid, subclavian and axillary arteries, the brachiocephalic artery, and the ascending, arch and descending aorta.

The best approach to scoring cranial disease on ¹⁸F-FDG PET/CT has since been the subject of a case-control study.(36) In comparing the scan results of c-GCA patients with controls, visual analysis of PET avidity proved less specific (75%) than utilising a semi-quantitative cut-off of 5.00 based upon the maximum standardised uptake value (SUV_{max}) of a defined arterial region of interest compared with the background blood pool (92%). The performance of qualitative scoring could however be improved by utilising a higher cut-off value and when multiple territories were involved. It is therefore clear that routinely evaluating the cranial arteries offers the potential of adding value to the diagnostic capability of this modality in suspected GCA cases. That said, there is a need for further research into the accuracy of

individual vessel findings on PET/CT, with another recent study finding better sensitivity for the trunk and frontal branches of the temporal arteries as compared with the parietal segments.(37)

- Extra-cranial disease:

Arterial uptake of the radiolabelled sugar molecule ^{18}F -FDG on PET scanning can confirm a diagnosis of LV-GCA due to the high metabolic activity of involved inflammatory cells including macrophages and lymphocytes, with low-dose CT facilitating anatomic correlation of findings.(38) The avidity of uptake is typically compared to the liver either by visual assessment using the Meller score (0 – no uptake present; 1 – low-grade uptake [uptake present but lower than liver uptake]; 2 – intermediate-grade uptake [similar to liver uptake]; 3 – high-grade uptake [between liver uptake and cerebral uptake]) or SUV_{max} .(39) In general, ^{18}F -FDG uptake in the vessel wall ≥ 2 is considered indicative of LVV, although higher SUV cut-off values have been advocated for at the aorta and iliofemoral regions due to greater likelihood of confounding by atherosclerotic disease in this distribution.(40)

Two studies have evaluated the diagnostic performance of PET in LV-GCA, reporting sensitivities of 67-77% and specificities of 66-100% using TAB and clinical diagnosis as reference standards, respectively.(41, 42) The timing of the scan relative to the administration of high-dose glucocorticoid therapy (which should not be delayed in patients with symptoms of c-GCA) is important, with a reduction in the intensity of ^{18}F -FDG uptake within the vessel wall appreciated after just 72 hours.(43) Despite this, accurate diagnosis was still achieved in a prospective study of patients with confirmed LV-GCA after 3 days of treatment, however the sensitivity of the test decreased substantially by day 10 with only 5/14 patients remaining PET positive. Among patients with a negative TAB, the sensitivity of PET/CT for an LV-GCA diagnosis has been established to be 61% and specificity 80%, based upon results of a retrospective cohort study.(44) A significant proportion of these patients were though treated with prednisolone prior to scanning, which presumably would have diminished the results. Regardless, it is clear that whole body PET/CT is worth considering to aid diagnosis in this clinical setting.

An additional advantage to whole body PET/CT over other imaging modalities in cases of suspected LVV, is its ability to exclude relevant differential diagnoses including malignancy and infection. In the instance of pyrexia of unknown origin and inflammation of unknown origin (a common clinical presentation among patients with LV-GCA), there is additionally evidence to support the cost-effectiveness of PET/CT as part of the preliminary work-up.(45-47) Furthermore, PET/CT is increasingly recognised as the gold standard investigation for polymyalgia rheumatica (PMR), as a result of exquisite sensitivity and specificity values when a combination of abnormalities at sites corresponding to distinctive musculotendinous inflammation are detected.(48) Given the overlapping pathologies of these conditions whereby roughly half of all GCA patients will experience polymyalgia symptoms, recognition of this disease subset may similarly prove useful in circumstances of diagnostic uncertainty.

B. Monitoring Disease Activity and Predicting Treatment Outcomes

Reliable tools to assess disease activity in GCA are required. Although 12 months of tocilizumab in combination with a weaning schedule of glucocorticoid therapy has been shown to substantially reduce the risk of relapse, less than one-quarter of participants in the open-label extension of the GIACTA study achieved a sustained drug-free remission at 2 years.(3, 49) For patients and clinicians alike, concern that sudden visual loss or stroke might result if disease relapse is

not treated promptly looms large. Similarly, structural complications including aortic aneurysm formation and dissection most frequently develop at vessel segments exhibiting active inflammation, with higher incidence rates among patients experiencing a relapsing disease course.(50, 51) At this point, however, there is insufficient evidence for routine imaging of GCA patients in clinical remission (defined as the absence of all symptoms and signs attributable to active disease and normalisation of CRP and ESR).(21, 52, 53) This is largely because abnormalities detected by modalities such as ultrasound, MRI and PET/CT at diagnosis do not universally resolve with treatment. The clinical significance of these residual changes is yet to be determined in some circumstances (for example, in c-GCA), or not convincingly associated with relevant long-term outcomes like disease relapse in others (for example, persistent ¹⁸F-FDG uptake in the large vessels on PET/CT).(20) Consequently, the present-day focus is very much upon establishing the expected resolution of abnormal findings with treatment and the correlation between persistence and/or recurrence of signs and disease activity.

Ultrasound

As at diagnosis, ultrasound's potential for point-of-care application makes it an appealing modality by which to evaluate disease activity in GCA. It is well-established that the halo sign in the cranial arteries resolves following 2-4 weeks of glucocorticoid therapy (Figure 2).(21) The same cannot be said of the extra-cranial vessels, where intima-media thickening can persist for many months; whether this represents ongoing active inflammation, fibrosis or a combination can be difficult to establish.(21)

The GUSTO study, which involved an ultra-short course of glucocorticoid therapy (500mg intravenous [IV] methylprednisolone [MP] administered for three consecutive days) followed by IV tocilizumab on day 3 and weekly subcutaneous (SC) tocilizumab thereafter, provides a unique insight into the impact of treatment upon cranial and extra-cranial vessel IMT.(54) Initial MP administration caused a rapid reduction in IMT at the temporal arteries by day 2/3, subsequently increasing back to baseline levels at week 4 and then gradually declining until week 52. Whilst a comparable reduction in IMT was documented at day 2/3 along with a gradual rebound in thickness up to week 8 at the axillary and subclavian arteries, a plateau was observed until week 24 when values were once again noted to decrease. Presumably, these observations reflect the rapid effects of high-dose glucocorticoid therapy upon vessel wall oedema, as compared with tocilizumab's slower onset of action. This differential response does however raise the possibility that tocilizumab might be less effective in its treatment of LV- than c-GCA, and/or further substantiates an inherent difference in the remodelling and repair efforts that take place in larger, more muscular great vessels once inflammation has abated. Unfortunately, practical and ethical considerations impede correlation of recurrent histological sampling with longitudinal imaging among GCA patients.

Few studies have specifically explored the correlation between ultrasound findings and clinical outcomes in GCA.(55-57). De Miguel et al. established a correlation between halo disappearance at the cranial arteries and reduced markers of systemic inflammation (CRP/ESR), with patients imaged at the time of disease relapse noted to have fewer involved arterial segments, lower CRP and ESR levels, and a shorter time to halo resolution compared with those scanned at the point of GCA diagnosis.(55) Change in IMT values following treatment has subsequently been explored as a means for monitoring disease activity, with a reduction in wall thickening once again more commonly observed at the temporal arteries than the larger vessels.(56) In their work assessing the sensitivity to change of the non-compressible halo sign

and IMT in newly diagnosed GCA patients, Ponte et al. demonstrated a positive correlation between temporal artery features and conventional disease activity markers (CRP, ESR and Birmingham Vasculitis Activity Score [BVAS]) during follow-up.(57) Notably, these findings were not replicated at the axillary arteries. In terms of long-term outcomes, a smaller number of involved halo segments and lower IMT at the temporal arteries (but not the axillary arteries) proved to be a predictor of clinical remission likelihood and cumulative prednisolone dose. Among 17 patients experiencing disease relapse, 16 (94.1%) were found to possess at least one active arterial segment with halo, which also exhibited an increase in IMT measured.

Put together, these results suggest that ultrasound shows promise as a monitoring tool for GCA disease activity, however it remains clear that differences abound in the trajectory of change that takes place in different vascular territories with treatment. The recently developed OMERACT GCA Ultrasonography Score, calculated from the sum of IMT measured in the superficial temporal (common trunk, frontal and parietal branches) and axillary arteries first divided by pre-determined IMT cut-off values and then the number of segments available, provides a consensus-based and provisionally validated instrument to monitor GCA that will require additional study in clinical research settings.(58) Modifications to ultrasound imaging protocols, such as the use of contrast, may similarly provide novel insights, particularly in the LV-GCA space. A proof-of-concept study suggests high sensitivity (91.7%) and specificity (100%) for the detection of active extra-cranial disease when a >25% increase in the calculated contrasted area is observed, however further investigation in a larger patient cohort where the sonographer is blinded to clinical information is now needed.(59)

PET/CT, MRA and PET/MRI

PET/CT represents the other most studied modality for monitoring disease activity in GCA to date, although research efforts are thus far limited to assessing extra-cranial manifestations longitudinally (Figure 3). Of course, radiation exposure (approximately 9mSv for a whole body scan from skull vertex to toes, less if limited from skull vertex to mid-thigh) and accessibility (usually limited to tertiary hospitals) represent definite drawbacks to utilising this modality for monitoring purposes. By contrast, MRI utilises magnetic properties to produce images, is more widely available and offers the theoretic potential to monitor both the cranial and extra-cranial arteries serially (although not at the same time). The current literature is however limited to the use of MRA in LV-GCA, though its application in c-GCA and correlation between these findings and clinical disease states will undoubtedly become areas of future research interest.

Blockmans et al. first studied repetitive PET in GCA, demonstrating a marked reduction in the number and intensity of involved arterial segments after 3 months of treatment, but no further decrease at the 6-month mark.(20) When the 18 patients whose disease relapsed during the follow-up period were compared with those participants in a sustained clinical remission, no difference could be identified in the PET findings between the groups at diagnosis, 3- or 6-months follow-up.

Hybrid PET/CT technology has since permitted improved anatomical correlation of vascular ¹⁸F-FDG uptake. Consequently, the calcific deposits that accompany atherosclerosis, recognised as another inflammatory condition of the blood vessel wall with abundant activated immune cells, can be better distinguished from segments of active LVV.(60) This is of certain importance when contemplating serial imaging to assess disease activity in the older GCA population. A diffuse and linear (as opposed to focal and patchy) pattern of abnormal ¹⁸F-FDG uptake in multiple vessels

is recognised as characteristic of active GCA, with PET avidity greater than the liver (Grade 3 as per Meller et al. (39)) the best discriminator between LV-GCA and atherosclerotic disease (sensitivity 83%, specificity 91%).(61)

A lack of widely accepted or standardised definitions for clinical outcomes of relevance, like remission and relapse, together with a paucity of accurate biomarkers have hampered efforts to establish thresholds of meaning for active disease on imaging in LVV.(62) In order to evaluate the potential of PET/CT for monitoring purposes, Grayson et al. undertook a large, prospective, longitudinal cohort study that repeated imaging at six-monthly intervals. Like results from ultrasound studies of extra-cranial involvement, frequent discordance between clinical remission and abnormal vascular ¹⁸F-FDG uptake was found – 41/71 patients (57.7%) deemed to be in clinical remission exhibited imaging findings consistent with active vasculitis. Consequently, the specificity of ¹⁸F-FDG-PET/CT to differentiate between LVV on imaging and remission was only 42%. Correlation between clinically active LVV and PET/CT findings was better though (34/40), yielding a sensitivity of 85% and specificity of 83%.

This work additionally provided the basis for the development of the PETVAS scoring system, an instrument designed to reflect vasculitis disease activity by summing the qualitative assessment of arterial ¹⁸F-FDG uptake compared to the liver across nine vascular territories (aorta, subclavian, carotid and innominate arteries).(63) Clinically active LVV was found to correlate with a higher mean PETVAS (21.5 vs. 12.2, $p < 0.001$), whilst lower scores were seen in association with disease remission. The ability of the PETVAS to discriminate between clinical disease states subsequently yielded a sensitivity of 68% and specificity of 71% using a cut-point of ≥ 20 . Whilst this performance is not ideal, the reliability of clinician-determined disease activity in LVV (which is similarly known to be imperfect) should be factored into these results. Furthermore, a much higher proportion of participants with a PETVAS score ≥ 20 were found to experience later disease relapse (45% vs. 11%, $p = 0.03$), suggesting a possible prognostic application.

The available literature in this field has since been the topic of a systematic review ($n = 21$) and meta-analysis ($n = 8$). (64) Substantial heterogeneity in study design was noted regarding LVV diagnosis (the majority including patients with GCA and TAK), disease duration (new or relapsing), imaging protocol (scan extent, ¹⁸F-FDG dose and acquisition time), reference standard (clinician diagnosis or use of instruments incompletely validated in LVV eg. BVAS, definition of ¹⁸F-FDG positivity (mostly using the liver as the reference organ) and analysis strategy (qualitative and/or semi-quantitative). Consequently, a planned meta-analysis to establish the proportion of patients in clinical remission with normalised scan findings was unable to proceed. The ability of ¹⁸F-FDG PET/CT to detect disease relapse/refractory disease could however be ascertained based upon results of four cross-sectional studies ($n = 111$ patients, with 136 scans). Results demonstrated moderate diagnostic accuracy, with a sensitivity of 77% and specificity of 71%.

Recent publications have focussed more upon the impact of different treatment approaches on PET/CT findings. In the Resolution of Vascular Inflammation in Patients with GCA (RIGA) study, Schönau et al. demonstrated a significant reduction in PETVAS scores during follow-up (median 11.8 months) among LV-GCA patients treated with either prednisolone monotherapy, or prednisolone combined with either methotrexate or tocilizumab.(65) A numerically greater reduction in PETVAS was observed with combination treatment, however only 37/82 (45.12%) follow-up scans were actually deemed “inactive” (defined as the absence of vascular ¹⁸F-FDG uptake ≥ 2 (39) in any vascular territory). In another prospective study involving LV-GCA patients treated with tocilizumab, a similar incidence of persistent

active vasculitis was recorded (11/25 [44%]).(66) Both groups have additionally explored the performance of PETVAS as a predictor of relapse, however findings failed to demonstrate good accuracy for discriminating between disease states and worsening vascular ¹⁸F-FDG uptake did not correlate with clinical manifestations in the majority of cases.(65, 66)

In the younger TAK population where repeated radiation exposure is particularly undesirable, MRA is preferred over ¹⁸F-FDG PET/CT for monitoring purposes.(21) By contrast, relatively few studies have investigated this application in LV-GCA. Similar to the PET/CT literature, discord between clinical and imaging-based remission has been observed – in patients with either new-onset or relapsing GCA treated with tocilizumab, one-third failed to improve their scan findings after 12 weeks despite being deemed to be in complete clinical and laboratory remission.(67) Quinn et al. additionally contrasted the performance of MRA and ¹⁸F-FDG PET/CT in a prospective study, finding MRI to be more capable of documenting disease extent but less reliable for assessing vasculitis activity.(68) Concordance between MRA and PET/CT was present in 68% of scans (Cohen's kappa=0.30), but correlation between clinical disease activity (determined by the treating physician) and imaging findings was superior for PET/CT. It therefore seems apparent that the higher image resolution of MRI compared to PET/CT confers greater sensitivity for the detection of vessel wall inflammatory changes, however not all abnormalities appreciated on imaging prove clinically significant. It is nonetheless worth noting that findings of wall oedema and thickening (but not vascular stenosis) on MRA were independently associated with PET/CT disease activity.

It is likely that hybrid imaging technology will continue to evolve. Although scarcely available, the lower radiation exposure associated with PET/MRI makes it another modality with potential for monitoring purposes. Thus far, a small pilot study has documented little difference in PET/MRI and PET/CT qualitative and semi-quantitative scores for active disease.(68) Furthermore, improved understanding of the precise pathophysiology underlying LV-GCA, and perhaps inherent differences to the cranial form of the disease, may translate into the development and application of novel PET tracers targeting cell populations specific to disease activity and which better correlate with outcomes of clinical relevance.(69)

C. Surveillance for Vascular Complications

Imaging is the primary means by which to surveil for thoracic aortic aneurysm (TAA) formation and thoracic aortic dilatation (TAD) in patients with established GCA. The optimal approach to do so, however, remains incompletely determined. As in diagnosis and disease activity monitoring, a similar paradigm exists whereby different imaging modalities offer their own characteristic advantages, yet no technique provides a perfect solution in isolation.

Increased thoracic aortic diameter, in the form of TAA and TAD, represent the most notable disease-related long-term complications for patients with established, treated GCA.(70) Diameter varies by location within the thoracic aorta, but also naturally increases over time, gaining approximately 1mm per decade of life. Aortic dilatation, which generally represents enlargement outside the age-specific normal range per 95% confidence intervals, can lead to aneurysm formation when the aorta is dilated >50% wider than expected. This phenomenon is recognised to occur in an accelerated fashion in some, but not all, GCA patients.(71) Uncontrolled aortitis, which can progress asynchronously to cranial and systemic manifestations, is believed to represent the primary driver, although other processes including atrophy of the aortic smooth muscle and concurrent atherosclerosis may additionally contribute.(50, 51, 72) Serial monitoring of aortic

diameter therefore has been suggested as a means by which to characterise each GCA patient's risk of a catastrophic complication.(71) While TAA is usually clinically silent as it develops, rupture is typically heralded by excruciating chest or thoracic back pain, dyspnoea and severe hypotension. Less than half of patients survive until emergency arrival at a hospital, and approximately half of the remaining patients will die in hospital, even with modern interventional techniques.(73, 74) Pre-emptive intervention, in the form of endovascular or open repair, is generally considered when rupture risk is deemed sufficiently high. A substantive imperative therefore exists to diagnose TAA prior to this outcome and identify those patients in whom intervention is justified.

TAD will however only impact a minority of patients with GCA, and it is presently unclear whether this increased risk similarly translates to abdominal aortic aneurysm formation.(75, 76) When contemplating the best approach to screening for vascular complications, the chosen imaging modality must not be detrimental to the unaffected majority through factors such as ionizing radiation exposure, financial cost or the psychological distress associated with serial radiographic surveillance and/or follow-up of incidental imaging findings. This challenge is further exacerbated by the broad window of TAA risk in GCA, which continues well after diagnosis before plateauing around ten years.(71) Optimal timing, including interval lengths at different stages of the natural history, has yet to be determined, although previous guidance has suggested reassessing every two years.(77) Quantification and serial comparison may also be aided by the use of angiographic scores and established methods for measurement.(78-80)

Chest X-Ray

Until recently, chest x-ray was considered the only modality feasible for routine screening of TAD and TAA in GCA.(77) Inherent advantages include its affordability, accessibility and minimal ionizing radiation. It is, however, insufficiently sensitive in the development of early-stage TAA as it cannot determine aortic wall thickness, and is of particularly limited value in the ascending aorta, which is frequently affected in GCA patients.(81, 82) Age-related radiographic appearances such as "unfolding of the aorta" can also lead to false-positives that necessitate further dedicated imaging.

Transthoracic Echocardiography (TTE)

TTE can visualise the aortic root and ascending aorta, and similarly offers the advantages of being widely accessible, relatively low cost, requires no contrast and confers no ionizing radiation. It nevertheless only detects the internal diameter of the aorta, missing the wall thickening associated with aortitis and secondary TAA, as well as other features of aortitis including peri-adventitial enhancement.(83) TTE cannot visualise the entire length of the thoracic aorta, is affected by body habitus, and its operator-dependent nature makes it less replicable in the context of serial imaging surveillance for measurement.(84, 85) Ultimately, TTE might be appropriate for screening for aortic structural change in GCA, but there is little evidence to support this approach and any abnormalities detected in this context should be subsequently confirmed with a different imaging modality.(81)

CTA

CTA represents another frequently employed modality for TAD and TAA surveillance.(21) Advantages include accessibility and relative affordability, together with its rapid image acquisition time and established use in other populations, for example collagen and connective tissue disorders like Marfan and vascular Ehlers-Danlos syndromes.

Notably, modern CT imaging techniques generally confer higher spatial resolution than MRI, and therefore are more accurate in measuring aortic structures. A prospective evaluation of aortic segments by CTA undertaken 12 months post the commencement of glucocorticoid therapy demonstrated persistent arterial wall thickening in approximately half of all GCA patients scanned.(86) This result does not however adequately inform the use of this modality for the detection of TAD and TAA. Furthermore, CTA is recognised as inferior to MRI and PET for assessing the activity of segments affected by vasculitis owing to limited soft tissue contrast. Consideration should additionally be given to the nephrotoxic potential of arterial-phase iodinated contrast agents and the risks associated with cumulative radiation exposure from serial imaging.(87) The radiation dose associated with CTA of the aorta has however reduced from 10-20 mSV to less than one-third of that in recent times, making repetitive scanning to monitor for TAD and TAA more feasible than before.(88, 89).

Few descriptions exist in the literature to inform screening recommendations about serial CTA in GCA. In one cohort, patients were imaged every four years, in the absence of any overt disease activity, to detect TAA and TAD.(90) Structural abnormalities were documented in up to one-third of participants, with the highest incidence during the 5 years following diagnosis. A lack of data exists to inform alternative approaches, including from other conditions wherein TAD monitoring is routine, yet optimal intervals remain contentious.(81, 91) Regardless, serial imaging utilising either CTA, MRI or US is considered justifiable in all GCA patients with known large vessel involvement.(21)

Whole Body PET/CT and MRA

PET/CT, with its enhanced capacity to demonstrate active aortitis, could plausibly predict future TAD and TAA development by demonstrating active inflammatory change. Increased ¹⁸F-FDG uptake at diagnosis in the aorta has been previously shown to correlate with the late volume of the thoracic aorta, considered a surrogate for aortic diameter.(92) A retrospective cohort analysis similarly found a relationship between the degree of PET avidity at both diagnosis and follow-up, and the incidence of TAD.(93) With increasing use of this modality for disease monitoring purposes in LV-GCA, it stands to reason that PET/CT may additionally be capable of surveying for evolving structural damage in this disease subset.

Despite the absence of ionizing radiation, MRI still provides sufficient spatial resolution, particularly of the aortic root, to facilitate TAD and TAA measurement. Its natural advantage in LV-GCA is aligned with its roles in diagnosis and disease monitoring: good soft tissue contrast permits sensitive detection of active aortitis. The ability of MRA to characterise vascular complications in GCA at individual timepoints is thus established, but evidence to support its use serially for the purpose of monitoring TAA is scarce, even outside of GCA.(67, 94)

Summary

Imaging has transformed the diagnosis of GCA, both for cranial and extra-cranial subsets of the disease, in the past decade, and significantly diminished the necessity for undertaking the traditional, but invasive, investigation of TAB. Many questions do remain unanswered concerning the best use of this technology for disease monitoring and vascular complication surveillance purposes. It is nonetheless clear, that the potential is great should future research studies manage to better characterise the expected change in abnormal imaging findings with treatment and their relationship

to outcomes of clinical significance like disease relapse, as well as determining the optimal interval for serial scanning to detect the development of TAD and TAA.

Practice Points

- TAU can be a first-line diagnostic test for cranial-GCA; when performed by an experienced sonographer, a positive TAU is sufficient for diagnosis without the need for a temporal artery biopsy.
- For patients with suspected LV-GCA, PET/CT offers the advantage over ultrasound and MRA of imaging the vasculature throughout the whole body, as well as excluding relevant differential diagnoses.
- Both cranial and extra-cranial/large vessel imaging abnormalities improve with treatment, however the latter appear more persistent; the relationship of these persistent changes to clinical disease states remains unclear.
- Surveillance for vascular complications including TAD and TAA is recommended in all LV-GCA patients, with best evidence for CTA as the imaging modality of choice, however the optimal interval between scans is contentious.

Research Agenda

- Role of imaging for assessing treatment response in GCA.
- Determination of the long-term clinical significance, particularly the relationship to remission and disease relapse, of persistent imaging abnormalities at both cranial and extra-cranial vessels in GCA.
- Further study of the incidence of vascular complications among all GCA patients, not just those with recognised large vessel involvement, with resultant characterisation of the best approach (imaging modality, frequency, duration) to surveillance.

Conflict of Interest

Author CEO declares advisory board for Abbvie; speaking honoraria from Abbvie, Novartis and Roche; Co-Investigator on STERLING-PMR trial, funded by NIHR; Investigator on Abbvie and Novartis clinical trials.

Author MY declares advisory board for BioGen; Co-investigator on STERLING-PMR trial, funded by NIHR; financial support from AbbVie and UCB to attend international conferences including the BSR and EULAR.

Author DFL Co-Investigator on STERLING-PMR trial, funded by NIHR.

Author AMP declares no conflict of interest.

Author HIK declares speaking honoraria from Abbvie, Roche and Jansen; Co-Investigator on STERLING-PMR trial, funded by NIHR; Investigator on Abbvie, Sanofi and Novartis clinical trials; educational support from Pfizer.

Author CLH declares...

Author SLM declares consultancy on behalf of her institution for Roche/Chugai, Sanofi, AbbVie and AstraZeneca; Investigator on clinical trials for Sanofi, GSK and Sparrow; speaking/lecturing on behalf of her institution for Roche/Chugai, Vifor, Pfizer, UCB and Novartis; chief investigator on STERLING-PMR trial, funded by NIHR; patron of the charity PMRGCAuk. No personal remuneration was received for any of the above activities. Support from Roche/Chugai to attend EULAR2019 in person and from Pfizer to attend ACR Convergence 2021 virtually. SLM is supported in part by the NIHR Leeds Biomedical Research Centre.

The views expressed in this article are those of the authors and not necessarily those of the NIHR, the NIHR Leeds Biomedical Research Centre, the National Health Service or the UK Department of Health and Social Care.

References

1. Watts RA, Hatemi G, Burns JC, et al. Global epidemiology of vasculitis. *Nature Reviews Rheumatology*. 2022;18(1):22-34.
2. Ponte C, Grayson PC, Robson JC, et al. 2022 American College of Rheumatology/EULAR classification criteria for giant cell arteritis. *Annals of the Rheumatic Diseases*. 2022;81(12):1647.
3. Stone JH, Tuckwell K, Dimonaco S, et al. Trial of Tocilizumab in Giant-Cell Arteritis. *New England Journal of Medicine*. 2017;377(4):317-28.
4. Ashton-Key M, Gallagher PJ. Surgical pathology of cranial arteritis and polymyalgia rheumatica. *Baillieres Clin Rheumatol*. 1991;5(3):387-404.
5. Ponte C, Martins-Martinho J, Luqmani RA. Diagnosis of giant cell arteritis. *Rheumatology (Oxford)*. 2020;59(Suppl 3):iii5-iii16.
6. Muniz Castro HM, Bhattacharjee MB, Chaudhry IA, et al. Diagnosis of giant cell arteritis using clinical, laboratory, and histopathological findings in patients undergoing temporal artery biopsy. *Clin Neurol Neurosurg*. 2022;221:107377.
7. Rubenstein E, Maldini C, Gonzalez-Chiappe S, et al. Sensitivity of temporal artery biopsy in the diagnosis of giant cell arteritis: a systematic literature review and meta-analysis. *Rheumatology (Oxford)*. 2020;59(5):1011-20.
8. Fernández-Fernández E, Monjo-Henry I, Bonilla G, et al. False positives in the ultrasound diagnosis of giant cell arteritis: some diseases can also show the halo sign. *Rheumatology (Oxford)*. 2020;59(9):2443-7.
9. Kelley JS. Doppler ultrasound flow detector used in temporal artery biopsy. *Arch Ophthalmol*. 1978;96(5):845-6.
10. Barrier J, Potel G, Renaut-Hovasse H, et al. The use of Doppler flow studies in the diagnosis of giant cell arteritis. Selection of temporal artery biopsy site is facilitated. *JAMA*. 1982;248(17):2158-9.
11. Germanò G, Muratore F, Cimino L, et al. Is colour duplex sonography-guided temporal artery biopsy useful in the diagnosis of giant cell arteritis? A randomized study. *Rheumatology (Oxford)*. 2015;54(3):400-4.
12. Luqmani R, Lee E, Singh S, et al. The Role of Ultrasound Compared to Biopsy of Temporal Arteries in the Diagnosis and Treatment of Giant Cell Arteritis (TABUL): a diagnostic accuracy and cost-effectiveness study. *Health Technol Assess*. 2016;20(90):1-238.
13. Patil P, Williams M, Maw WW, et al. Fast track pathway reduces sight loss in giant cell arteritis: results of a longitudinal observational cohort study. *Clin Exp Rheumatol*. 2015;33(2 Suppl 89):S-103-6.
14. Diamantopoulos AP, Haugeberg G, Lindland A, et al. The fast-track ultrasound clinic for early diagnosis of giant cell arteritis significantly reduces permanent visual impairment: towards a more effective strategy to improve clinical outcome in giant cell arteritis? *Rheumatology (Oxford)*. 2016;55(1):66-70.
15. Schmidt WA, Kraft HE, Vorpahl K, et al. Color Duplex Ultrasonography in the Diagnosis of Temporal Arteritis. *New England Journal of Medicine*. 1997;337(19):1336-42.
16. Aschwanden M, Daikeler T, Kesten F, et al. Temporal artery compression sign--a novel ultrasound finding for the diagnosis of giant cell arteritis. *Ultraschall Med*. 2013;34(1):47-50.
17. Chrysidis S, Duftner C, Dejaco C, et al. Definitions and reliability assessment of elementary ultrasound lesions in giant cell arteritis: a study from the OMERACT Large Vessel Vasculitis Ultrasound Working Group. *RMD Open*. 2018;4(1):e000598.
18. Dejaco C, Ponte C, Monti S, et al. The provisional OMERACT ultrasonography score for giant cell arteritis. *Ann Rheum Dis*. 2022.
19. Ponte C, Serafim AS, Monti S, et al. Early variation of ultrasound halo sign with treatment and relation with clinical features in patients with giant cell arteritis. *Rheumatology (Oxford)*. 2020;59(12):3717-26.
20. Blockmans D, de Ceuninck L, Vanderschueren S, et al. Repetitive 18F-fluorodeoxyglucose positron emission tomography in giant cell arteritis: a prospective study of 35 patients. *Arthritis Rheum*. 2006;55(1):131-7.
21. Dejaco C, Ramiro S, Duftner C, et al. EULAR recommendations for the use of imaging in large vessel vasculitis in clinical practice. *Annals of the Rheumatic Diseases*. 2018;77(5):636.
22. Hop H, Mulder DJ, Sandovici M, et al. Diagnostic value of axillary artery ultrasound in patients with suspected giant cell arteritis. *Rheumatology (Oxford)*. 2020;59(12):3676-84.
23. Prearo I, Dekorsy FJ, Brendel M, et al. Diagnostic yield of axillary artery ultrasound in addition to temporal artery ultrasound for the diagnosis of giant cell arteritis. *Clin Exp Rheumatol*. 2022;40(4):819-25.
24. Skoog J, Svensson C, Eriksson P, et al. The Diagnostic Performance of an Extended Ultrasound Protocol in Patients With Clinically Suspected Giant Cell Arteritis. *Frontiers in Medicine*. 2022;8.
25. Oshinsky C, Bays AM, Sacksen I, et al. The Usefulness of Subclavian Artery Ultrasound Assessment in Giant Cell Arteritis Evaluation. *J Clin Rheumatol*. 2023;29(1):43-6.

26. Bley TA, Reinhard M, Hauenstein C, et al. Comparison of duplex sonography and high-resolution magnetic resonance imaging in the diagnosis of giant cell (temporal) arteritis. *Arthritis Rheum.* 2008;58(8):2574-8.
27. Duftner C, Dejaco C, Sepriano A, et al. Imaging in diagnosis, outcome prediction and monitoring of large vessel vasculitis: a systematic literature review and meta-analysis informing the EULAR recommendations. *RMD Open.* 2018;4(1):e000612.
28. Zhang K-J, Li M-X, Zhang P, et al. Validity of high resolution magnetic resonance imaging in detecting giant cell arteritis: a meta-analysis. *Eur Radiol.* 2022;32(5):3541-52.
29. Sommer NN, Treitl KM, Coppenrath E, et al. Three-Dimensional High-Resolution Black-Blood Magnetic Resonance Imaging for Detection of Arteritic Anterior Ischemic Optic Neuropathy in Patients With Giant Cell Arteritis. *Invest Radiol.* 2018;53(11):698-704.
30. D'Souza NM, Morgan ML, Almarzouqi SJ, et al. Magnetic resonance imaging findings in giant cell arteritis. *Eye (Lond).* 2016;30(5):758-62.
31. Guggenberger KV, Vogt ML, Song JW, et al. Intraorbital findings in giant cell arteritis on black blood MRI. *Eur Radiol.* 2022.
32. Betrains A, Blockmans D. Diagnostic Approaches for Large Vessel Vasculitides. *Open Access Rheumatol.* 2021;13:153-65.
33. Quinn KA, Grayson PC. The Role of Vascular Imaging to Advance Clinical Care and Research in Large-Vessel Vasculitis. *Curr Treatm Opt Rheumatol.* 2019;5(1):20-35.
34. Nielsen BD, Hansen IT, Kramer S, et al. Simple dichotomous assessment of cranial artery inflammation by conventional 18F-FDG PET/CT shows high accuracy for the diagnosis of giant cell arteritis: a case-control study. *Eur J Nucl Med Mol Imaging.* 2019;46(1):184-93.
35. Sammel AM, Hsiao E, Schembri G, et al. Diagnostic Accuracy of PET/CT Scan of the Head, Neck and Chest for Giant Cell Arteritis: The Double-Blinded Giant Cell Arteritis and PET Scan (GAPS) Study. *Arthritis Rheumatol.* 2019;08:08.
36. Nienhuis PH, Sandovici M, Glaudemans AWJM, et al. Visual and semiquantitative assessment of cranial artery inflammation with FDG-PET/CT in giant cell arteritis. *Semin Arthritis Rheum.* 2020;50(4):616-23.
37. Rottenburger C, Mensch N, Imfeld S, et al. 18F-FDG PET/CT compared with ultrasound and biopsy for detection of vasculitis of the temporal artery branches. *Swiss Med Wkly.* 2021;151:w20512.
38. Belhocine T, Blockmans D, Hustinx R, et al. Imaging of large vessel vasculitis with (18)FDG PET: illusion or reality? A critical review of the literature data. *Eur J Nucl Med Mol Imaging.* 2003;30(9):1305-13.
39. Meller J, Strutz F, Siefker U, et al. Early diagnosis and follow-up of aortitis with [(18)F]FDG PET and MRI. *Eur J Nucl Med Mol Imaging.* 2003;30(5):730-6.
40. Imfeld S, Rottenburger C, Schegk E, et al. [18F]FDG positron emission tomography in patients presenting with suspicion of giant cell arteritis—lessons from a vasculitis clinic. *European Heart Journal - Cardiovascular Imaging.* 2017;19(8):933-40.
41. Blockmans D, Stroobants S, Maes A, et al. Positron emission tomography in giant cell arteritis and polymyalgia rheumatica: evidence for inflammation of the aortic arch. *The American Journal of Medicine.* 2000;108(3):246-9.
42. Lariviere D, Benali K, Coustet B, et al. Positron emission tomography and computed tomography angiography for the diagnosis of giant cell arteritis: A real-life prospective study. *Medicine (Baltimore).* 2016;95(30):e4146.
43. Nielsen BD, Gormsen LC, Hansen IT, et al. Three days of high-dose glucocorticoid treatment attenuates large-vessel 18F-FDG uptake in large-vessel giant cell arteritis but with a limited impact on diagnostic accuracy. *European Journal of Nuclear Medicine & Molecular Imaging.* 2018;45(7):1119-28.
44. Hay B, Mariano-Goulart D, Bourdon A, et al. Diagnostic performance of ¹⁸F-FDG PET-CT for large vessel involvement assessment in patients with suspected giant cell arteritis and negative temporal artery biopsy. *Ann Nucl Med.* 2019;33(7):512-20.
45. Becerra Nakayo EM, García Vicente AM, Soriano Castrejón AM, et al. Analysis of cost-effectiveness in the diagnosis of fever of unknown origin and the role of 18F-FDG PET-CT: A proposal of diagnostic algorithm. *Revista Española de Medicina Nuclear e Imagen Molecular (English Edition).* 2012;31(4):178-86.
46. Balink H, Tan SS, Veeger NJGM, et al. 18F-FDG PET/CT in inflammation of unknown origin: a cost-effectiveness pilot-study. *Eur J Nucl Med Mol Imaging.* 2015;42:1408-13.
47. Bilici Salman R, Gülbahar Ateş S, Satiş H, et al. Diagnostic Role of 18F-Fluorodeoxyglucose Positron Emission Tomography for the Evaluation of Patients With Inflammation of Unknown Origin. *J Clin Rheumatol.* 2021;27(6):219-25.
48. Owen CE, Poon AMT, Yang V, et al. Abnormalities at three musculoskeletal sites on whole-body positron emission tomography/computed tomography can diagnose polymyalgia rheumatica with high sensitivity and specificity. *European Journal of Nuclear Medicine & Molecular Imaging.* 2020;47(10):2461-8.

49. Stone JH, Han J, Aringer M, et al. Long-term effect of tocilizumab in patients with giant cell arteritis: open-label extension phase of the Giant Cell Arteritis Actemra (GiACTA) trial. *The Lancet Rheumatology*. 2021;3(5):e328-e36.
50. de Boysson H, Daumas A, Vautier M, et al. Large-vessel involvement and aortic dilation in giant-cell arteritis. A multicenter study of 549 patients. *Autoimmunity Reviews*. 2018;17(4):391-8.
51. Espitia O, Blonz G, Urbanski G, et al. Symptomatic aortitis at giant cell arteritis diagnosis: a prognostic factor of aortic event. *Arthritis Research & Therapy*. 2021;23(1):14.
52. Monti S, Águeda AF, Luqmani RA, et al. Systematic literature review informing the 2018 update of the EULAR recommendation for the management of large vessel vasculitis: focus on giant cell arteritis. *RMD Open*. 2019;5(2):e001003.
53. Hellmich B, Agueda A, Monti S, et al. 2018 Update of the EULAR recommendations for the management of large vessel vasculitis. *Annals of the Rheumatic Diseases*. 2020;79(1):19.
54. Seitz L, Christ L, Lötscher F, et al. Quantitative ultrasound to monitor the vascular response to tocilizumab in giant cell arteritis. *Rheumatology (Oxford)*. 2021;60(11):5052-9.
55. De Miguel E, Roxo A, Castillo C, et al. The utility and sensitivity of colour Doppler ultrasound in monitoring changes in giant cell arteritis. *Clinical & Experimental Rheumatology*. 2012;30(1 Suppl 70):S34-8.
56. Aschwanden M, Schegk E, Imfeld S, et al. Vessel wall plasticity in large vessel giant cell arteritis: an ultrasound follow-up study. *Rheumatology*. 2019;58(5):792-7.
57. Ponte C, Monti S, Scire CA, et al. Ultrasound halo sign as a potential monitoring tool for patients with giant cell arteritis: a prospective analysis. *Annals of the Rheumatic Diseases*. 2021;80(11):1475-82.
58. Dejaco C, Ponte C, Monti S, et al. The provisional OMERACT ultrasonography score for giant cell arteritis. *Annals of the Rheumatic Diseases*. 2023;82(4):556.
59. Bergner R, Splitthoff J, Wadsack D. Use of Contrast-Enhanced Ultrasound Sonography in Giant Cell Arteritis: A Proof-of-Concept Study. *Ultrasound Med Biol*. 2022;48(1):143-8.
60. Nienhuis PH, van Praagh GD, Glaudemans A, et al. A Review on the Value of Imaging in Differentiating between Large Vessel Vasculitis and Atherosclerosis. *J Pers Med*. 2021;11(3).
61. Stellingwerff MD, Brouwer E, Lensen KDF, et al. Different Scoring Methods of FDG PET/CT in Giant Cell Arteritis: Need for Standardization. *Medicine (Baltimore)*. 2015;94(37):e1542.
62. Aydin SZ, Robson JC, Sreih AG, et al. Update on Outcome Measure Development in Large-vessel Vasculitis: Report from OMERACT 2018. *The Journal of rheumatology*. 2019;46(9):1198-201.
63. Grayson PC, Alehashemi S, Bagheri AA, et al. ¹⁸F-Fluorodeoxyglucose-Positron Emission Tomography As an Imaging Biomarker in a Prospective, Longitudinal Cohort of Patients With Large Vessel Vasculitis. *Arthritis Rheumatol*. 2018;70(3):439-49.
64. van der Geest KSM, Treglia G, Glaudemans A, et al. Diagnostic value of [18F]FDG-PET/CT for treatment monitoring in large vessel vasculitis: a systematic review and meta-analysis. *Eur J Nucl Med Mol Imaging*. 2021;48(12):3886-902.
65. Schönau V, Roth J, Tascilar K, et al. Resolution of vascular inflammation in patients with new-onset giant cell arteritis: data from the RIGA study. *Rheumatology (Oxford)*. 2021;60(8):3851-61.
66. Quinn KA, Dashora H, Novakovich E, et al. Use of 18F-fluorodeoxyglucose positron emission tomography to monitor tocilizumab effect on vascular inflammation in giant cell arteritis. *Rheumatology*. 2021;60(9):4384-9.
67. Reichenbach S, Adler S, Bonel H, et al. Magnetic resonance angiography in giant cell arteritis: results of a randomized controlled trial of tocilizumab in giant cell arteritis. *Rheumatology*. 2018;57(6):982-6.
68. Quinn KA, Ahlman MA, Malayeri AA, et al. Comparison of magnetic resonance angiography and 18F-fluorodeoxyglucose positron emission tomography in large-vessel vasculitis. *Annals of the rheumatic diseases*. 2018;77(8):1165-71.
69. van der Geest KSM, Sandovici M, Nienhuis PH, et al. Novel PET Imaging of Inflammatory Targets and Cells for the Diagnosis and Monitoring of Giant Cell Arteritis and Polymyalgia Rheumatica. *Front Med (Lausanne)*. 2022;9:902155.
70. Kermani TA, Warrington KJ, Crowson CS, et al. Large-vessel involvement in giant cell arteritis: a population-based cohort study of the incidence-trends and prognosis. *Ann Rheum Dis*. 2013;72(12):1989-94.
71. Robson JC, Kiran A, Maskell J, et al. The relative risk of aortic aneurysm in patients with giant cell arteritis compared with the general population of the UK. *Ann Rheum Dis*. 2015;74(1):129-35.
72. Margos PN, Moyssakis IE, Tzioufas AG, et al. Impaired elastic properties of ascending aorta in patients with giant cell arteritis. *Ann Rheum Dis*. 2005;64(2):253-6.
73. Johansson G, Markström U, Swedenborg J. Ruptured thoracic aortic aneurysms: a study of incidence and mortality rates. *J Vasc Surg*. 1995;21(6):985-8.

74. Geisbüsch P, Kotelis D, Weber TF, et al. Endovascular repair of ruptured thoracic aortic aneurysms is associated with high perioperative mortality and morbidity. *J Vasc Surg.* 2010;51(2):299-304.
75. Mackie SL, Hensor EM, Morgan AW, et al. Should I send my patient with previous giant cell arteritis for imaging of the thoracic aorta? A systematic literature review and meta-analysis. *Ann Rheum Dis.* 2014;73(1):143-8.
76. Jud P, Verheyen N, Dejaco C, et al. Prevalence and prognostic factors for aortic dilatation in giant cell arteritis - a longitudinal study. *Semin Arthritis Rheum.* 2021;51(4):911-8.
77. Dasgupta B, Borg FA, Hassan N, et al. BSR and BHRP guidelines for the management of giant cell arteritis. *Rheumatology (Oxford).* 2010;49(8):1594-7.
78. Nakagomi D, Cousins C, Sznajd J, et al. Development of a score for assessment of radiologic damage in large-vessel vasculitis (Combined Arteritis Damage Score, CARDS). *Clin Exp Rheumatol.* 2017;35 Suppl 103(1):139-45.
79. Tombetti E, Godi C, Ambrosi A, et al. Novel Angiographic Scores for evaluation of Large Vessel Vasculitis. *Sci Rep.* 2018;8(1):15979.
80. Kawel-Boehm N, Maceira A, Valsangiacomo-Buechel ER, et al. Normal values for cardiovascular magnetic resonance in adults and children. *J Cardiovasc Magn Reson.* 2015;17(1):29.
81. Erbel R, Aboyans V, Boileau C, et al. 2014 ESC Guidelines on the diagnosis and treatment of aortic diseases: Document covering acute and chronic aortic diseases of the thoracic and abdominal aorta of the adult. The Task Force for the Diagnosis and Treatment of Aortic Diseases of the European Society of Cardiology (ESC). *Eur Heart J.* 2014;35(41):2873-926.
82. von Kodolitsch Y, Nienaber CA, Dieckmann C, et al. Chest radiography for the diagnosis of acute aortic syndrome. *Am J Med.* 2004;116(2):73-7.
83. Kallianos KG, Burris NS. Imaging Thoracic Aortic Aneurysm. *Radiol Clin North Am.* 2020;58(4):721-31.
84. Bhawe NM, Nienaber CA, Clough RE, et al. Multimodality Imaging of Thoracic Aortic Diseases in Adults. *JACC Cardiovasc Imaging.* 2018;11(6):902-19.
85. Eswarsingh A, Bose A, Islam T, et al. Predictors and Rate of Progression of Aortic Root and Ascending Aorta Dilatation. *Am J Cardiol.* 2022;181:118-21.
86. Prieto-González S, García-Martínez A, Tavera-Bahillo I, et al. Effect of glucocorticoid treatment on computed tomography angiography detected large-vessel inflammation in giant-cell arteritis. A prospective, longitudinal study. *Medicine (Baltimore).* 2015;94(5):e486.
87. Smith-Bindman R, Lipson J, Marcus R, et al. Radiation dose associated with common computed tomography examinations and the associated lifetime attributable risk of cancer. *Arch Intern Med.* 2009;169(22):2078-86.
88. Liu Y, Xu J, Li J, et al. The ascending aortic image quality and the whole aortic radiation dose of high-pitch dual-source CT angiography. *J Cardiothorac Surg.* 2013;8(1):228.
89. Kok M, de Haan MW, Muhl C, et al. Individualized CT Angiography Protocols for the Evaluation of the Aorta: A Feasibility Study. *J Vasc Interv Radiol.* 2016;27(4):531-8.
90. García-Martínez A, Arguis P, Prieto-González S, et al. Prospective long term follow-up of a cohort of patients with giant cell arteritis screened for aortic structural damage (aneurysm or dilatation). *Annals of the Rheumatic Diseases.* 2014;73(10):1826.
91. Hiratzka LF, Bakris GL, Beckman JA, et al. 2010 ACCF/AHA/AATS/ACR/ASA/SCA/SCAI/SIR/STS/SVM guidelines for the diagnosis and management of patients with Thoracic Aortic Disease: a report of the American College of Cardiology Foundation/American Heart Association Task Force on Practice Guidelines, American Association for Thoracic Surgery, American College of Radiology, American Stroke Association, Society of Cardiovascular Anesthesiologists, Society for Cardiovascular Angiography and Interventions, Society of Interventional Radiology, Society of Thoracic Surgeons, and Society for Vascular Medicine. *Circulation.* 2010;121(13):e266-369.
92. Blockmans D, Coudyzer W, Vanderschueren S, et al. Relationship between fluorodeoxyglucose uptake in the large vessels and late aortic diameter in giant cell arteritis. *Rheumatology (Oxford).* 2008;47(8):1179-84.
93. Muratore F, Crescentini F, Spaggiari L, et al. Aortic dilatation in patients with large vessel vasculitis: A longitudinal case control study using PET/CT. *Semin Arthritis Rheum.* 2019;48(6):1074-82.
94. Koenigkam-Santos M, Sharma P, Kalb B, et al. Magnetic resonance angiography in extracranial giant cell arteritis. *J Clin Rheumatol.* 2011;17(6):306-10.

Table 1: Utility of available imaging modalities for diagnosis, disease activity monitoring, and surveillance for vascular complications in GCA.

Modality	Ultrasound	MRI	¹⁸ F-FDG PET/CT	CTA
Site	Cranial vessels Great vessels (excluding aorta)	Cranial vessels Great vessels (MRA)	Whole body (skull vertex to toes)	Great vessels
Key Findings	c-GCA: <ul style="list-style-type: none"> Halo sign Compression sign LV-GCA: <ul style="list-style-type: none"> Halo sign IMT >1.0mm⁵³ 	Concentric wall thickening and mural contrast enhancement	Diffuse and linear ¹⁸ F-FDG uptake in the vessel wall ≥2 [#]	Vascular complications including TAD and TAA
Advantages	No ionising radiation Point-of-care use	High image resolution No ionising radiation Can additionally image orbit and intra-cranial vessels	Exclude relevant differentials Can assess all vascular territories throughout the body	Readily available Rapid acquisition time Affordable
Disadvantages	Operator-dependent Halo IMT reduces ≥4 days post treatment	Metallic implants contraindicated Claustrophobia Longer acquisition time AEs to gadolinium-contrast agent – allergy, nephrotoxicity	Reduced ¹⁸ F-FDG uptake >72 hours post treatment Ionising radiation (~9mSv) Limited availability Expensive	Ionising radiation (~≤7mSv) AEs to iodinated contrast – allergy, nephrotoxicity
Diagnosis*	Halo sign ^{5,14} : <ul style="list-style-type: none"> Sensitivity 68-88% Specificity 77-91% 	c-GCA ²⁶ : <ul style="list-style-type: none"> Sensitivity 73% Specificity 88% 	c-GCA ⁴⁵ : <ul style="list-style-type: none"> Sensitivity 71% Specificity 91% LV-GCA ³⁷ : <ul style="list-style-type: none"> Sensitivity 67% Specificity 100% 	Inferior to MRI and PET/CT due to limited soft tissue contrast
Monitoring Disease Activity	c-GCA changes more responsive to treatment than LV-GCA No. of halo segments and IMT values may correlate with relapse/remission in c-GCA ⁵⁷	Frequent discord between imaging findings and clinical state Less reliable than PET/CT for assessing disease activity ⁷⁰	Low-grade ¹⁸ F-FDG uptake common despite clinical remission Moderate accuracy for detecting disease relapse ⁶³ : <ul style="list-style-type: none"> Sensitivity 77% Specificity 71% 	Not appropriate
Surveillance for Vascular Complications	TTE may be appropriate for screening	Scarce evidence in GCA	May demonstrate at-risk segments for TAD and TAA ⁹⁵	Most frequently employed modality

*Utilising clinical diagnosis as the reference standard.

[#]As per the Meller score, where 2 represents intermediate-grade uptake, similar to the liver.

Figure 1: A. Normal temporal artery with Power Doppler ultrasound (PDUS); B. Normal temporal artery under compression; C. Normal axillary artery; D. Normal axillary artery with PDUS; E. Halo sign in c-GCA; F. Compression sign in c-GCA; G. Abnormal axillary artery in LV-GCA; H. Abnormal axillary artery in LV-GCA with PDUS demonstrating increased IMT.

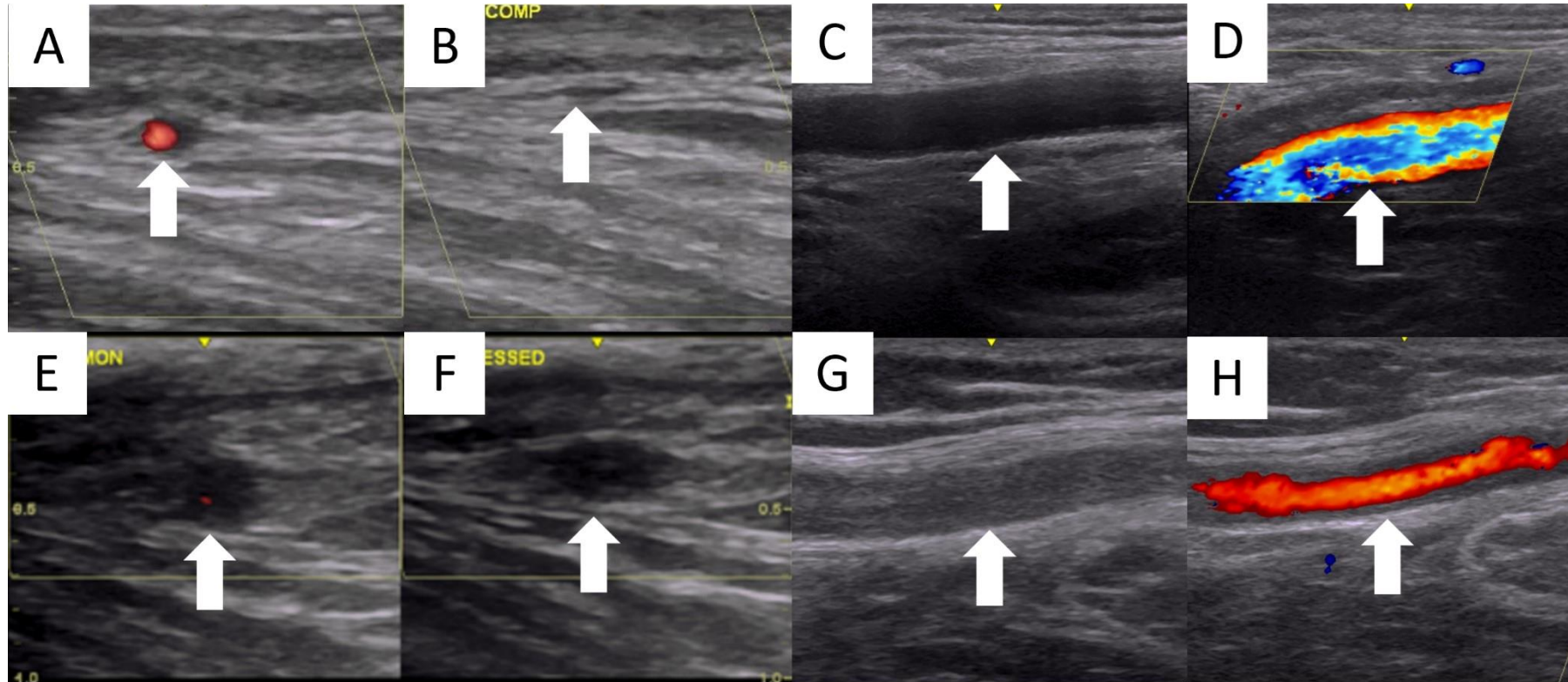


Figure 2: Halo sign in c-GCA at baseline in transverse (A.) and longitudinal views (C.); Resolution of halo sign following initiation of treatment (B. and D.).

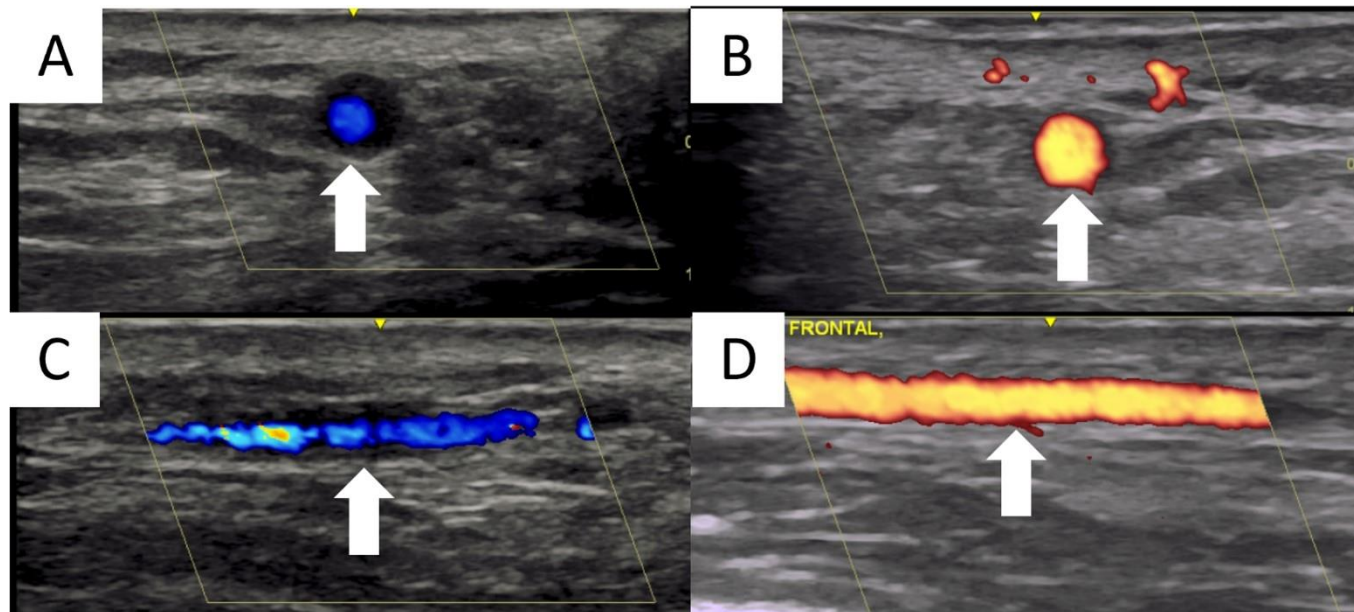


Figure 3: LV-GCA on whole body PET/CT at diagnosis (A.); Significant improvement in ^{18}F -FDG uptake following 12 months of treatment with tocilizumab (B.).

