

## CASE REPORT

# Testicular vasculitis: a diagnostic conundrum

Alice M. Malpas<sup>1,\*†</sup>, Richard Y. Ball<sup>2</sup>, Chetan Mukhtyar<sup>3</sup>,  
James W. MacKay<sup>4</sup> and Mohammed Omer<sup>2</sup>

<sup>1</sup>Rheumatology Department, Norfolk and Norwich Hospital, Norwich, UK, <sup>2</sup>Norfolk & Waveney Cellular Pathology Service, The Cotman Centre, Norfolk and Norwich University Hospital, Norwich, UK, <sup>3</sup>Rheumatology Department, Norfolk and Norwich Hospital, University of East Anglia, Norwich, UK and, <sup>4</sup>Norwich Medical School, University of East Anglia, Norwich, UK

\*Correspondence address. Rheumatology Department, Norfolk and Norwich Hospital, Colney Lane, Norwich NR4 7UY, UK. Tel: +44-01603286286; E-mail: [alice.malpas@nnuh.nhs.uk](mailto:alice.malpas@nnuh.nhs.uk)

## Abstract

Vasculitis is rare in the context of testicular lesions but, when found, can be classified as a single organ vasculitis or part of a multi-organ inflammatory process. In the context of a patient with a pre-existing autoimmune disorder, this finding might cause diagnostic confusion and preferentially bias a physician towards attributing the condition to the known diagnosis or its treatment. This diagnostic bias can interfere with patient care and lead to over caution, resulting in a worse outcome for the patient involved. We describe such a patient with rheumatoid arthritis on biologic therapy.

## INTRODUCTION

Single organ vasculitis (SOV) in the context of a pre-existing autoimmune disorder can cause diagnostic confusion, especially when a patient is immunosuppressed. Diagnostic bias can ensue with patients being treated more cautiously than necessary at the potential expense of their health. We report a case of testicular vasculitis in a patient with rheumatoid arthritis (RA) on etanercept; both of which are known to cause systemic vasculitis.

## CASE

A 66-year-old man developed painless right testicular swelling. He had a history of RA, Parkinson's disease and depression, for which he was taking etanercept, carbidopa levodopa and mirtazapine.

Examination identified a mass in the right testicle; abdominal examination was normal. Full blood count and liver and renal functions were normal. C-reactive protein was <1 mg/l; erythrocyte sedimentation rate had been chronically above normal with no specific cause identified. Alpha-fetoprotein and human chorionic gonadotropin were both normal.

Ultrasound scanning showed a normal left testis but a focal hypochoic mass-like lesion in the right testis (Fig. 1) with several small nodular foci which were isoechoic to background testis. Appearances were concerning for testicular cancer. He was seen by a urologist 2 weeks later and had a normal computed tomography of the thorax, abdomen and pelvis. Within 3 weeks of the ultrasound, he had a radical orchidectomy in accordance with European urology guidelines [1] as a malignant tumour was suspected.

On slicing, the testis contained an ill-defined mid-zonal reddish/brown focus (Fig. 2). Histopathological examination showed

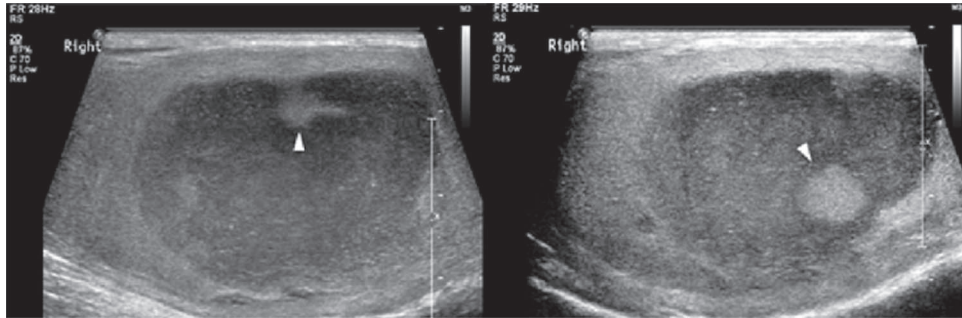
†Alice M. Malpas, <http://orcid.org/0000-0002-7079-4999>

Received: January 14, 2020. Revised: March 3, 2020. Accepted: March 31, 2020

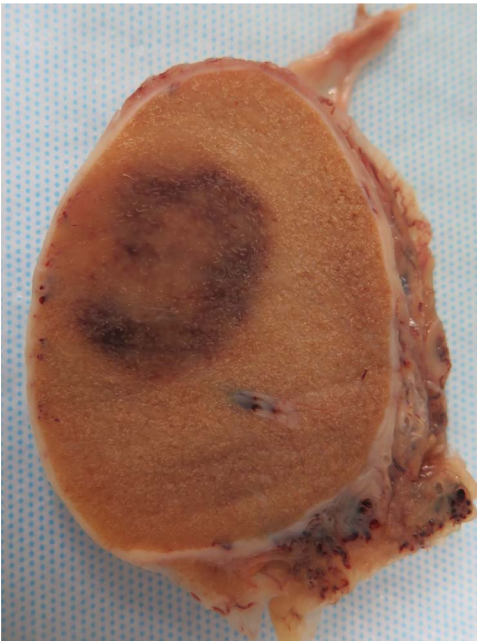
© The Author(s) 2020. Published by Oxford University Press.

This is an Open Access article distributed under the terms of the Creative Commons Attribution Non-Commercial License (<http://creativecommons.org/licenses/by-nc/4.0/>), which permits non-commercial re-use, distribution, and reproduction in any medium, provided the original work is properly cited.

For commercial re-use, please contact [journals.permissions@oup.com](mailto:journals.permissions@oup.com)



**Figure 1:** Two representative longitudinal greyscale ultrasound views of the right testis. A relatively well-defined hypoechoic mass-like lesion is demonstrated containing nodular foci which are isoechoic to normal background testicle (white arrowheads). Colour Doppler (not shown) demonstrated patchy vascularity within the lesion which was similar to that of background testicle.

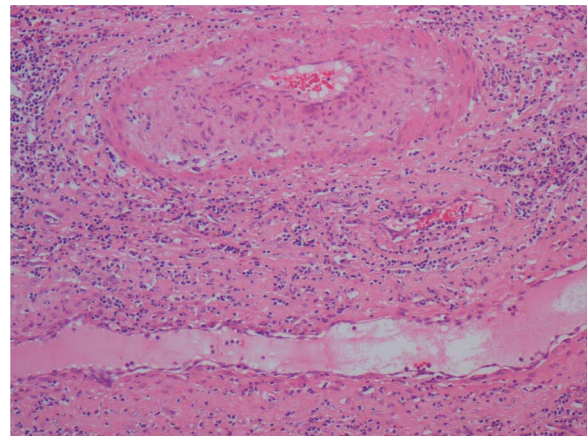


**Figure 2:** The cut surface of the fixed testis showing an oval focus of disease left of centre. The parenchyma surrounding the lesion is normal.

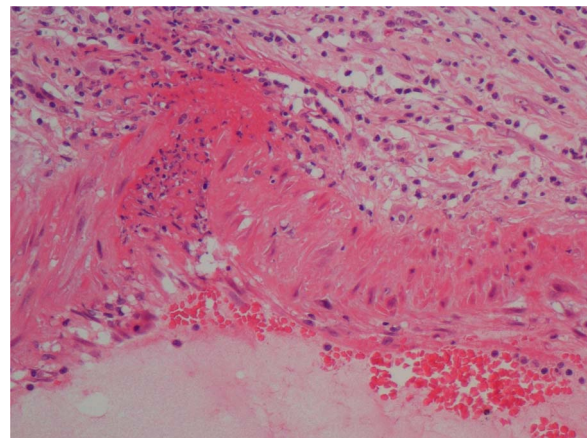
focal diffuse lymphocytic permeation of the parenchyma with aspermatogenic seminiferous tubules, most of which contained Sertoli cells and some spermatogonia. There was focal lymphocytic permeation of seminiferous tubules. Small- and medium-sized arteries in the lesion showed various vasculitic changes, including fibrocellular intimal thickening (Fig. 3), focal mild permeation of the intima by lymphocytes, dense adventitial lymphoid cell infiltration, focal transmural chronic inflammation, and focal fibrinoid necrosis with neutrophils (Fig. 4). No granulomata were present. Some veins contained organising thrombus, with mural inflammatory changes.

Many of the lymphocytes, including those surrounding and infiltrating vessel walls, were T-cells (CD3+, CD5+). The interstitial infiltrate also contained small numbers of mature-looking B-cells (CD20+, CD10-), a few of which permeated arterial walls. Molecular genetics tests confirmed that both sets of lymphocytes were polyclonal (reactive).

The changes indicated a form of non-granulomatous vasculitis affecting medium-sized vessels with associated localised chronic orchitis. The differential diagnoses included



**Figure 3:** A small testicular artery (top) shows marked fibrocellular intimal thickening and luminal narrowing with focal permeation of the wall by lymphocytes. The accompanying vein (bottom) shows more extensive permeation of its wall by lymphocytes. H&E;  $\times 10$  objective.



**Figure 4:** A small testicular artery shows a small focus of fibrinoid necrosis and neutrophil permeation at a branch point. H&E;  $\times 20$  objective.

antineutrophil cytoplasmic antibody (ANCA)-associated vasculitis (AAV), polyarteritis nodosa (PAN), SOV, rheumatoid vasculitis or drug-induced vasculitis.

His RA had been in remission for a number of years treated with etanercept monotherapy. He was in clinical remission with

no systemic symptoms. He had positive rheumatoid factor, anti-citrullinated antibodies and anti-Ro antibodies. ANCA was negative. Hepatitis B screening had been negative prior to starting etanercept 5 years earlier. While we did not perform coeliac axis angiography, PAN, AAV and rheumatoid vasculitis were thought less likely. There was no role for colour Doppler ultrasound or positron emission tomography-CT as there was no evidence of a large vessel vasculitis. Etanercept and other tumour necrosis factor  $\alpha$  inhibitors (TNF $\alpha$ ) are known to cause vasculitis, but no previous case of SOV has been attributed to TNF $\alpha$  in the literature. Neither carbidopa levodopa nor mirtazapine has been associated with vasculitis. Our final diagnosis was SOV, which may or may not have been drug-induced.

The etanercept had been stopped around the time of the orchidectomy due to surgical risks and subsequent vasculitis diagnosis. There was careful consideration as to whether it should be restarted. Considering there have been no previous documented cases of SOV related to TNF $\alpha$ , he was in remission on this therapy, and SOV of the testis is treated by the removal of the affected organ with a low recurrence rate; it was felt that the drug could be restarted.

## DISCUSSION

The Chapel Hill consensus conference defined SOV as 'Vasculitis in arteries or veins of any size in a single organ that has no features that indicate that it is a limited expression of a systemic vasculitis' [2]. SOV has a better prognosis and requires less aggressive therapy than systemic vasculitis, but reviewing the patient for at least 6 months to ensure no progression is recommended [3].

Testicular vasculitis is rare, having been reported in only 0.003% of surgeries [4] of testicular lesions and presents as a painful mass in the testis. About 80% of cases are unilateral, and surgical removal is considered curative; no further systemic treatment should be required.

Systemic vasculitis is identified by raised inflammatory markers, constitutional symptoms as well as specific organ involvement. PAN is the systemic vasculitis most commonly associated with testicular involvement, but the latter can be seen in AAV. Behçet's disease, IgA vasculitis, relapsing polychondritis and RA can also affect the testis but, in the case of RA, predominantly as a vasculitis or serositis with systemic symptoms and active arthritis. Our patient's RA was in remission.

Etanercept and other TNF $\alpha$  inhibitors have been known to cause a cutaneous leucocytoclastic vasculitis and a systemic vasculitis affecting the kidney or peripheral nerves [5, 6], but not SOV. It is doubtful that the TNF $\alpha$  was the cause of our patient's testicular vasculitis.

With RA and a drug unfamiliar to many physicians, our patient was treated cautiously. His TNF $\alpha$  inhibitor was withheld, which adversely affected his rheumatoid disease control. After a period of ~6 months following orchidectomy, etanercept was reintroduced with monitoring for recurrence, and he regained rheumatoid remission.

In spite of there being no evidence linking etanercept to SOV, there was a diagnostic bias which meant that he stayed off a drug

essential for his well-being longer than necessary. It is important not to assume blame when faced with unfamiliar diagnoses or drugs but to consider the literature available.

## ACKNOWLEDGEMENTS

None to declare.

## FUNDING

There are no sources of funding for this article.

## ETHICAL APPROVAL

None required.

## CONSENT

Informed consent was obtained from the patient.

## GUARANTOR

Alice M. Malpas is the guarantor for this report.

## CONFLICT OF INTEREST STATEMENT

No conflicts of interest.

## REFERENCES

1. European Association of Urology. *Guidelines on testicular Testicular cancer* (Online). Arnheim: European Association of Urology, 2015. [https://uroweb.org/wp-content/uploads/11-Testicular-Cancer\\_LR1.pdf](https://uroweb.org/wp-content/uploads/11-Testicular-Cancer_LR1.pdf) (3 March 2020, date last accessed).
2. Jennette JC, Falk RJ, Bacon PA, Basu N, Cid MC, Ferrario F, et al. 2012 revised international Chapel Hill consensus conference nomenclature of vasculitides. *Arthritis Rheum* 2013;**65**: 1–11.
3. Atisha-fregoso Y, Hinojosa-Azaola A, Alcocer-Varela J. Localized, single-organ vasculitis: clinical presentation and management. *Clinical Rheumatology* 2013;**32**:1–6.
4. Hernández-Rodríguez J, Tan CD, Koenig CL, Khasnis A, Rodríguez ER, Hoffman GS. Testicular vasculitis. Findings differentiating isolated disease from systemic disease in 72 patients. *Medicine (Baltimore)* 2012;**91**:75–85.
5. Sokumbi S, Wetter D, Makol A, Warrington K. Vasculitis associated with tumor necrosis factor- $\alpha$  inhibitors. *Mayo Clin Proc.* 2012;**87**:739–45.
6. Stokes MB, Foster K, Markowitz GS, Ebrahimi F, Hines W, Kaufman D et al. Development of glomerulonephritis during anti-TNF- $\alpha$  therapy for rheumatoid arthritis. *Nephrol Dial Transplant* 2005;**20**:1400–6.